



Flexor pollicis longus tendon rupture after volar wrist plating : reconstruction with palmaris longus interposition graft

Pieter BERGER, Joris DUERINCKX

From the Department of Orthopaedic Surgery and Traumatology, Ziekenhuis Oost-Limburg

Rupture of the flexor pollicis longus tendon is a rare complication after volar plating of distal radius fractures. Several surgical treatment options have been proposed but postoperative results are not well documented. The authors retrospectively studied the clinical outcome of 4 patients after flexor pollicis longus tendon reconstruction with a palmaris longus interposition graft. Minimal follow-up was 12 months. Mean active interphalangeal joint flexion (44°) and thumb opposition (Kapandji 8/10) were significantly reduced compared to the opposite side. Mean power grip (32 kg) and key pinch strength (8kg) of the operated hand were comparable to the contralateral hand. The mean Visual Analogue Scale for pain was 2.5/10. The mean DASH score was 14 points. Although flexion and opposition of the thumb did not return to normal after surgery, patients reported excellent functional results.

Keywords: distal radius fracture; osteosynthesis; complication; flexor pollicis longus; palmaris longus; tendon rupture

INTRODUCTION

Spontaneous ruptures of the flexor pollicis longus (FPL) tendon are rare. In the past it was typically described in patients with rheumatoid arthritis and known as a Mannerfelt lesion (11). When a scaphoid osteophyte erodes through the volar wrist capsule it can cause an attritional rupture of the FPL-tendon.

With advances in medical therapy this pathology has become rare (14,4). The introduction of angular stable volar plating to treat distal radius fractures in 2000 (14) has been associated with an increasing incidence of FPL-tendon ruptures (3,8,10). The main contributing factor is flexor tendon wear over the distal edge of a plate if this is placed superficial or distal to the watershed line (18).

Primary repair of chronic FPL tendon ruptures is difficult due to tendon abrasion and retraction. Treatment options are interposition tendon graft, tendon transfer of the 3th or 4th flexor digitorum superficialis (FDS) to the thumb (17), tendon advancement (16) or IP joint fusion (19). Preferred management for chronic FPL tendon ruptures has not been determined yet as only a few reports present the outcome of their surgical treatment in detail (3,6,10,20).

The purpose of this study was to evaluate the outcome of a series of 4 one-stage reconstructions of the FPL tendon with a free palmaris longus (PL) interposition tendon graft.

- Dr. Pieter Berger, MD, Resident
- Dr. Joris Duerinckx, MD, Surgeon
Ziekenhuis Oost-Limburg, Department of Orthopaedic Surgery and Traumatology, Belgium.

Correspondence : Dr. J. Duerinckx, Department of Orthopaedic Surgery and Traumatology, Ziekenhuis Oost-Limburg, Schiepse Bos 6, 3600 Genk, Belgium. Telephone: +32 89 326118.

E-mail : joris.duerinckx@zol.be

© 2017, Acta Orthopaedica Belgica.

*No benefits or funds were received in support of this study.
The authors report no conflict of interests.*

PATIENTS AND METHODS

With retrospective chart review we identified 4 patients who had an FPL tendon reconstruction with a palmaris longus tendon interposition graft. Surgeries were performed between February 2013 and January 2015. All patients (3 female, 1 male) were included in this study. Mean interval between tendon reconstruction surgery and study assessment was 19.8 months (Range 12-31). Median patient age at the time of tendon reconstruction was 66 years (range 52-79). In all patients the FPL tendon rupture was caused by friction against a prominent volar plate used for osteosynthesis of a distal radius fracture. Surgical treatment of the distal radius fracture in our study population was performed from 1998 to 2012. The interval between fracture treatment and tendon rupture varied between 5 months and 15 years. There were no patients with prodromal symptoms of tendon rupture. The interval between loss of active thumb flexion and surgical repair averaged 3 months (range 2-4,5). All patients underwent FPL tendon reconstruction with a PL tendon interposition autograft. The same post-operative rehabilitation protocol was used in all patients.

A single surgeon (JD) performed all surgeries. Another physician (PB) assessed the patients for this study. The involved extremity was examined first, followed by the contralateral limb that was used as a control. We measured flexion and extension of the interphalangeal (IP) joint of the thumb with a manual goniometer with the wrist in 45° of extension as this places the hand in the functional grasping position. Thumb opposition was scored as described by Kapandji. Thumb retropulsion was measured as the distance in millimeters from a flat surface to the thumb pulp with the palm placed flat on the surface and the thumb elevated to maximum retropulsion. Thumb motion was assessed actively and passively. We measured thumb pinch strength and grip strength of both hands with a pinch gauge and a dynamometer respectively (Jamar, Patterson Medical, Warrenville, IL, USA). Pain at the operated hand was scored with the Visual Analogue Scale. Functional outcome was measured with the Disabilities of the Arm, Shoulder, and Hand

questionnaire (DASH, Dutch version). Statistical analysis was performed using the non-paired Student's t-test. The study was approved by the institutional ethical review committee (reference number: B371201526231).

Surgical technique

Surgery was performed under axillary block anesthesia and with an upper arm tourniquet. A volar Henry approach at the distal forearm was used incorporating the previous incision and lengthening it if required. Rupture of the FPL tendon at the distal edge of the osteosynthesis plate was evident. The frayed ends of the FPL tendon were held in continuity by pseudo-tendon that was debrided (Fig. 1). Passive excursion of the FPL muscle was between 2-4 cm in all patients (Fig. 2). All hardware was removed. No other flexor tendons were ruptured. The PL tendon was harvested by transection at the volar wrist crease and proximal retrieval at its musculotendinous junction with a tendon stripper. To identify the distal end of the FPL tendon we made a Brunner-incision at the digitopalmar crease of the thumb (Fig. 3). The FPL tendon ends could not be approximated without excessive shortening. The PL graft was passed through the carpal tunnel from the proximal to the distal incision with a tendon clamp, following the normal trajectory of the FPL tendon (Fig. 4). The presence of the long distal stump of FPL-tendon in the carpal tunnel almost up to the volar wrist crease prevents tunnel fibrosis and

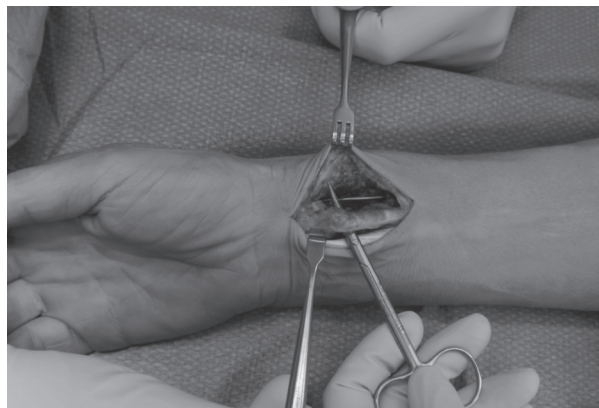


Fig. 1. — The flexor pollicis longus tendon is torn over the distal edge of the plate and held in continuity by thick fibrous tissue resembling a pseudo-tendon.

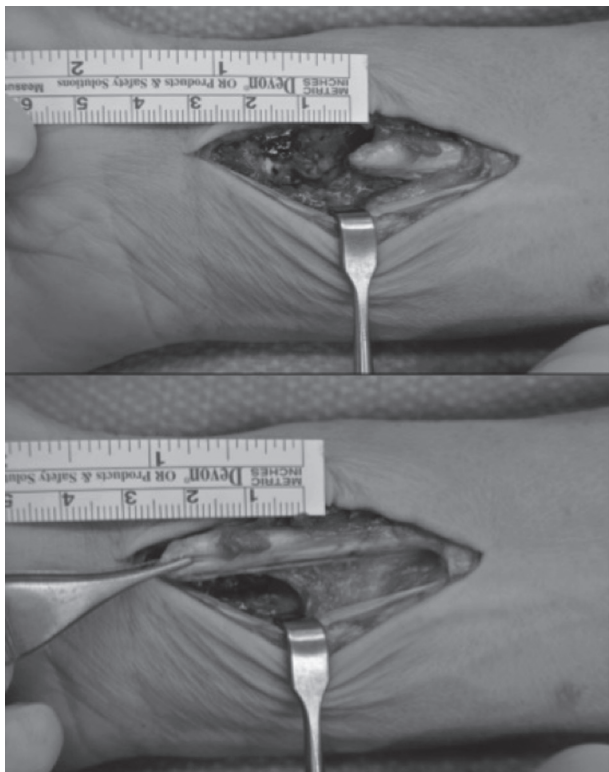


Fig. 2. — Passive excursion of the flexor pollicis longus muscle belly is measured.

facilitates passing the graft in the correct position. Next the PL graft is fixed to the distal tendon stump with a Pulvertaft tendon weave repair using at least 4 transverse passes. At every pass the tendon graft was fixed with a mattress stitch with Fiberloop 4-0 suture (Arthrex, Naples, Florida, USA). Proximally we fixed the graft using the same technique. The graft was tensioned in slightly more flexion than the contralateral thumb, taking contracture of the FPL muscle belly into account. With the wrist in neutral position the thumb pulp touched the base of the ring finger (Fig. 5). Wrist tenodesis effect was tested to ensure proper gliding of the tendon graft. Postoperatively a dorsal blocking splint was applied, immobilizing the wrist and thumb in moderate flexion. Three to five days postoperatively a standard Kleinert type passive flexion and active extension rehabilitation protocol was started under supervision of a hand therapist with protective bracing for 6 weeks. Labor and sports activities were allowed at 3 months after surgery.

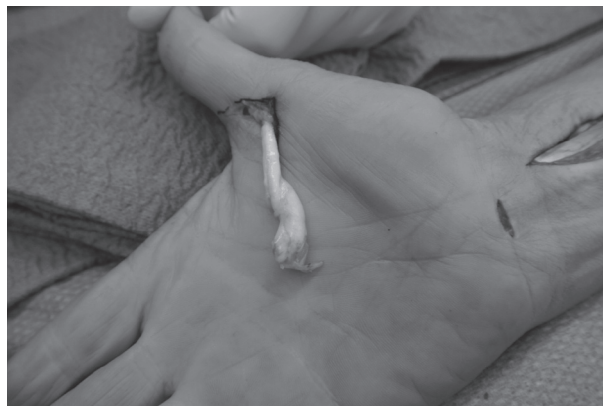

Fig. 3. — The distal end of the flexor pollicis longus tendon is identified.

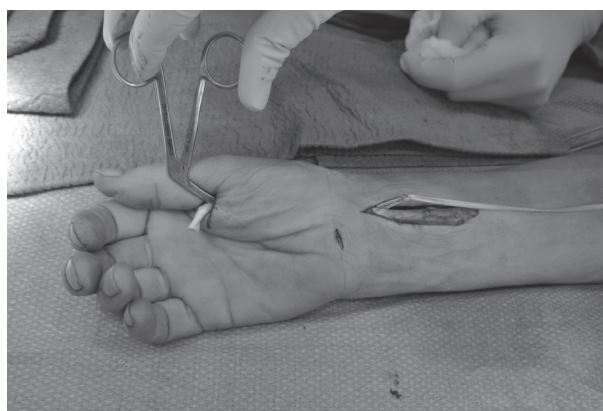


Fig. 4. — The palmaris longus tendon graft is passed from proximal to distal.

RESULTS

The results of our patients are shown in the table. Mean active flexion of the IP joint was 44° for the operated thumb and 80° for the contralateral thumb. This is a significant reduction of IP joint flexion of the thumb after FPL reconstruction compared to the unaffected side ($P 0.02$). Mean active thumb opposition of the operated hand was measured 8/10 according to Kapandji. This is significantly reduced compared to the complete thumb opposition of the contralateral side ($P 0.03$). Mean active thumb retropulsion was 26mm on the operated hand and 33mm on the contralateral hand. This difference is not significant ($P 0.3$). All patients had full passive range of motion of the operated thumb.

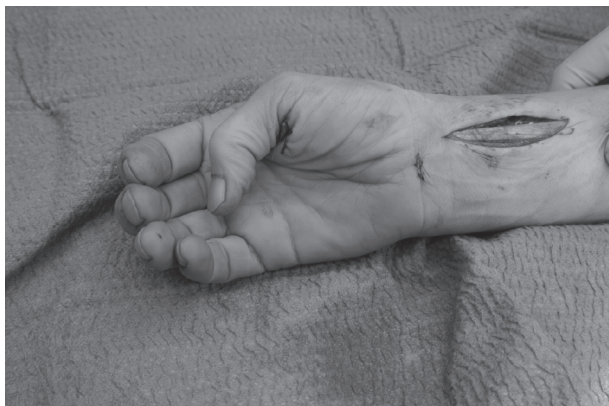

Fig. 5. — Appropriate tension of the tendon reconstruction.

Power grip of the operated hand (mean 32 kg) was comparable to the contralateral hand (mean 32 kg) and was not significantly altered (P 0.5). Key pinch strength was 7 kg for the operated hand and 8 kg for the opposite side (P 0.25).

Mean DASH score was 14 points (range 4.5-28).

The mean Visual Analogue Scale for pain was 2.5 (scale of 1-10, where 1 is normal).

No patient required reoperation. No patient had developed complex regional pain syndrome or other complications at final follow-up.

Neither of the two active working patients had to change their occupation.

DISCUSSION

Plate and screw osteosynthesis on the volar side of the distal radius can interfere with flexor tendon function. Hardware that is placed prominent to the watershed line can irritate the flexor tendons. Flexor tenosynovitis can be followed by tendon rupture and is an indication for hardware removal (1). Of all the flexor tendons the FPL tendon is most prone to rupture, followed by the flexor digitorum profundus tendon to the index finger (2). A recent systematic review of the literature found a total of 27 reported FPL ruptures after volar plating of the distal radius (2). The median interval between osteosynthesis and flexor tendon rupture is 9 months (2). Surgical treatment in these cases consisted most commonly of PL autograft reconstruction (9 patients), followed by end-to-end repair (8 patients) and tendon transfer (4 patients). Postoperative range of motion of

the interphalangeal joint of only 8 patients was documented. Only 2 cases achieved a full range of motion (one after end-to-end repair, and one following palmaris longus tendon transfer).

Tendon ruptures after wrist plating may not be amenable for primary repair because of attritional changes in the tendon tissue. A free tendon graft can be interposed to bridge the defect. The PL is usually of suitable length and diameter and conveniently near. Other tendons that can be used are plantaris and extensor indicis proprius. To be successful the FPL muscle must still be functional and not excessively shortened. When a flexor tendon is ruptured at wrist level it is prone to shortening because there are no restraints to proximal retraction. There is no way to determine tendon shortening of muscle fibrosis preoperatively. Normal excursion of the FPL tendon is 5.5-6 cm (17). Matev stated that if passive stretch of the FPL-tendon of 3-4 cm is preserved, restoration of full IP flexion could be expected. Even with 1.0 to 1.5 cm of passive stretch, the result would be “adequate” (12). If less than this it is better to choose another motor. In our series where passive stretch of the FPL muscle was 2-4 cm we have a mean active flexion of the IP-joint of 44°. In our small patient group we did not find a correlation between passive stretch and final active motion.

An alternative technique is to transfer the flexor superficialis tendon of the 4th finger to the distal stump of the FPL tendon. Its normal excursion is an advantage and makes it a useful procedure in those cases in which the FPL muscle is secondary contracted. In a series of 23 patients where this technique was used for reconstruction of posttraumatic FPL ruptures, postoperative mobility of the IP joint averaged 53.5° (15). Drawbacks of this technique are potential morbidity at the donor finger and the need for cortical reorganization.

To our knowledge this is the first study that reports the results of a series of FPL reconstructions in detail. Although IP flexion of the thumb did not return to normal after surgery, patients reported excellent functional results. The primary function of the FPL tendon is to position and to stabilize the thumb for tip-to-tip pinch and fingernail pickup (9). This function requires 20° to 30° of IP joint flexion and can be expected after PL tendon interposition.

Table I. — Patient demographics and results (I = involved side, UI = uninvolved side)

Patient	Age (years)	Side	DASH	VAS pain (/10)	Key pinch strength (kg)		Grip strength (kg)	
					I	UI	I	UI
1	52	L	28	3	7.5	13	46	48
2	79	R	7.5	5	7.5	5.5	20	24
3	76	R	4.5	1	6	6	31	25
4	57	R	16	1	6	7.5	30	30

Patient	Active IP flexion (degrees)		Active thumb retropulsion (mm)		Active thumb opposition (Kapandji score)	
	I	UI	I	UI	I	UI
1	55	60	0	30	9	10
2	15	70	35	35	5	10
3	60	100	30	15	9	10
4	45	90	40	50	8	10

The mean DASH score of 14 in our study population is comparable with the mean DASH score of 13 points that is found in the normal population (7). In our series grip and key pinch strength were unaffected. The prime source of flexion power of the thumb for pinch and grasp is the adductor pollicis.

Shortcomings of this study are the retrospective design, the lack of a control group and the small number of patients.

We conclude that FPL tendon rupture is a severe complication after volar plating of distal radius fractures. Preferred treatment of FPL rupture in this indication has not been determined yet and not much is known about outcome of eventual surgical treatment. FPL reconstruction with PL autograft is a valuable treatment option that can provide good functional recovery of hand function provided that the FPL-tendon has an excursion of at least 2cm.

REFERENCES

1. **Adham MN, Porembski M, Adham C.** Flexor tendon problems after volar plate fixation of distal radius fractures. *Hand* 2009 ; 4 : 406-409.
2. **Asadollahi S, Keith PA.** Flexor tendon injuries following plate fixation of distal radius fractures: a systematic review of the literature. *J Orthopaed Traumatol* 2013 ; 14 : 227-234.
3. **Bell JSP, Wollstein R, Citron ND.** Rupture of flexor pollicis longus tendon. A complication of volar plating of the distal radius. *J Bone Joint Surg* 1998 ; 80-B : 225-6.
4. **Breedveld FC.** Current and future management approaches for rheumatoid arthritis. *Arthritis Res* 2002 ; 4 : 16-21.
5. **Chung KC, Pushman AG.** Current Concepts in the Management of the Rheumatoid Hand. *J Hand Surg Am* 2011 ; 36 : 736-747.
6. **de Panafieu E, Upex P, Doursounian L, Robert N.** Free tendon grafts in elder patients, a case report of repair of flexor pollicis longus tendon with a free palmaris longus graft in an 89-year-old woman. *Ann Chir Plast Esthet* 2014 ; 1260 : 167-168.
7. **Jester A, Harth A, Germann G.** Measuring levels of upper-extremity disability in employed adults using the DASH questionnaire. *J Hand Surg Am* 2005 ; 30 : 1074. e1-1074.e10.
8. **Johnson NA, Cutler L, Dias JJ, Ullah AS, Wildin CJ, Bhowal B.** Complications after volar locking plate fixation of distal radius fractures. *Injury* 2014 ; 45 : 528-533.
9. **Kilgore ES, Newmeyer WL, Graham WP, Brown LG.** The dubiousness of grafting the flexor pollicis longus. *Am J Surg* 1976 ; 132 : 292-296.
10. **Klug RA, Press CM, Gonzalez MH.** Rupture of the flexor pollicis longus tendon after volar fixed-angle plating of a distal radius fracture: a case report. *J Hand Surg* 2007 ; 32A : 984-988.
11. **Mannerfelt L, Norman O.** Attrition ruptures of flexor tendons in rheumatoid arthritis caused by bony spurs in the carpal tunnel. A clinical and radiological study. *J Bone Joint Surg Br* 1969 ; 51 : 270-277.

12. **Matev IB.** *Reconstructive surgery of the thumb.* Pilgrim's Press, Brentwood, 1983, 50-56.
13. **Melton JT, Murray JR, Lowdon IM.** A simple clinical test of flexor pollicis longus rupture. *J Hand Surg Br* 2005 ; 30 : 624-625.
14. **Orbay JL.** The treatment of unstable distal radius fractures with volar fixation. *Hand Surg* 2000 ; 5 : 103-112.
15. **Posner MA.** Flexor superficialis tendon transfers to the thumb-an alternative to the free tendon graft for treatment of chronic injuries within the digital sheath. *J Hand Surg Am* 1983 ; 8 : 876-881.
16. **Schmitt S, Mühldorfer-Fodor M, van Schoonhoven J, Prommersberger KJ.** Restoration of thumb flexion at the interphalangeal joint by transposition of the flexor digitorum superficialis tendon from the ring finger. *Oper Orthop Traumatol* 2013 ; 25 : 321-330.
17. **Schneider LH, Wiltshire D.** Restoration of flexor pollicis longus function by flexor digitorum superficialis transfer. *J Hand Surg Am* 1983 ; 8 : 98-101.
18. **Soong M, Earp BE, Bishop G, Leung A, Blazar P.** Volar locking plate implant prominence and flexor tendon rupture. *J Bone Joint Surg Am* 2011 ; 93 : 328-335.
19. **Urbaniak JR, Goldner JL.** Laceration of the flexor pollicis longus tendon: delayed repair by advancement, free graft or direct suture. *J Bone Joint Surg Am* 1973 ; 55 : 1123-1148.
20. **Valbuena SE, Cogswell LK, Baraziol R, Valenti P.** Rupture of flexor tendon following volar plate of distal radius fracture. Report of five cases. *Chir Main* 2010 ; 29 : 109-113.