

Does harvesting the medial third of the patellar tendon cause lateral shift of the patella after ACL reconstruction ?

Mandeep S. DHILLON, Parmod MOHAN, Onkar N. NAGI

Many centers do not use the medial third of the patellar tendon as a graft for ACL reconstruction due to the apprehension that there may be post harvest maltracking of the patella towards the lateral side. We undertook a prospective study to evaluate patellar alignment in 30 patients in whom ACL reconstruction was done using the medial third of the patellar tendon. Q-angle assessment was the rough clinical parameter, and the Merchant view, Laurin views, and CT scans were used for radiological assessment. The assessment was done preoperatively and at six months post surgery, and the contralateral normal knees were used as controls. We observed no significant changes in the congruence angle (pre-op -13.86° , postop -12°) or the lateral patellofemoral angles in the pre-operative and postoperative knees as compared to the controls. CT scans were more sensitive for evaluating the congruence angles, and picked up an insignificant abnormal lateralisation of the patella in four cases. None of these patients however had any postoperative symptoms of misalignment. Although medial third graft harvesting did have a 13% change in patellar alignment, this was not statistically significant. Post harvesting local problems are inherent to the procedure, and are independent of the site of harvesting, as they were also seen in cases with no evidence of misalignment.

INTRODUCTION

Reconstruction of the ACL-deficient knee is one of the most frequent orthopaedic operations done today because of the increasing involvement in sports at all ages. The gold standard for surgical reconstruction today is intra-articular reconstruc-

tion with autogenous grafts. The bone-patellar tendon-bone graft is perhaps the strongest of the biological grafts for this purpose (4, 12) there are some primary advantages like better strength, ready availability, ease of fixation with interference screws (7) and the theoretical advantages of rapid healing of bone plugs within tibial and femoral tunnels (4, 7, 12). However inherent problems are often seen at the donor site defect, related to the healing process (14). Although Jones is credited with pioneering the use of patellar tendon to replace the injured ACL, Campbell had apparently advocated similar procedures in 1930 (8). Campbell has been credited with the use of the medial one-third of the patellar tendon in 1936 and the harvesting of the central one-third was described in 1963 by Jones, and is presently more widespread (3). The medial third of the tendon was initially used as the graft (1, 5, 8, 13), but most surgeons now prefer the central one-third; this may be partly based on the unproven belief that use of the medial third has the potential for patellar maltracking. The use of the

From the Postgraduate Institute of Medical Education & Research, Chandigarh, India.

Manjeep S. Dhillon, Additional Professor.

Parmod Mohan, Senior Resident.

Onkar S. Nagi, Professor and Head.

Department of Orthopaedics, Post Graduate Institute of Medical Education & Research, Chandigarh, India.

Correspondence and reprints : Manjeep S. Dhillon, Additional Professor Orthopaedics, 1090/2 Sector 39-B Chandigarh, 160036, India. E-mail : msdhillon@sancharnet.in ; mandyrima@hotmail.com.

© 2003, Acta Orthopædica Belgica.

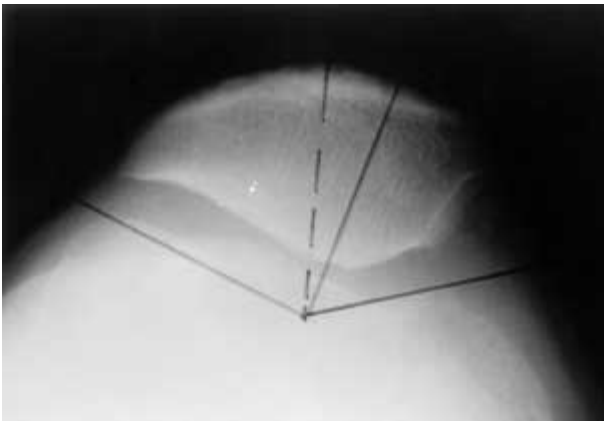


Fig. 1A. — Radiograph showing Merchant's view of a preoperative knee, with normal sulcus and congruence angles.

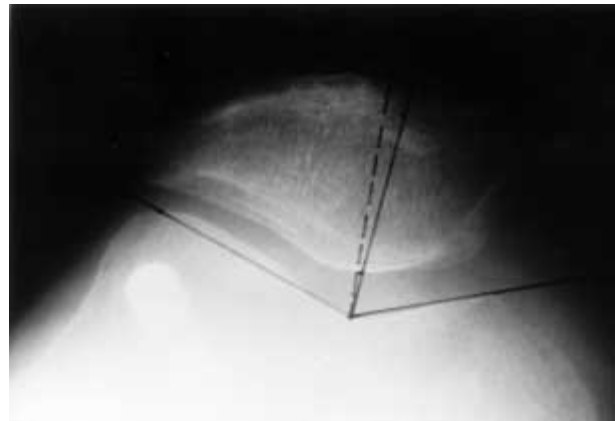


Fig. 1B. — Same case after ACL reconstruction (note medial graft harvest site and outside in interference screw). There is insignificant change in the angles.

patellar tendon as a graft can lead to some complications such as mild flexion contracture, patellofemoral pain, patellar tendon shortening with anterior knee pain and patella infera syndrome (14). This is the reason why the hamstrings are now being preferred by some as graft material.

In general there is the additional apprehension that the use of the medial third of the patellar tendon may predispose to patellofemoral arthrosis and changes in the patellar tracking, which might be responsible for the anterior knee pain and subsequent failure in some of these cases. Johnson *et al* (6, 7) used the medial third of the patellar tendon ; with 7 to 9 years follow-up, they noted residual primary laxity of the ACL graft, arthrosis, subpatellar crepitus, decreased mobility of the patella, patellar tenderness, thigh atrophy and parapatellar pain, but made no mention of maltracking. On the other hand, in another study, where the medial one-third of the patellar tendon was employed, the lateral mobility of the patella was actually found to be increased (16), and this is perhaps the basis of the disrepute of this procedure.

It is only recently that some light has been shed on this issue by a study that utilized ultrasound and radiological parameters to assess the presence or absence of misalignment (9).

We have been using the medial third of the patellar tendon as graft for over seven years, with no apparent increase in patellar maltracking. To prove or disprove this hypothesis, a prospective study was

done for assessment of the static patellar position in the early stages of flexion, using clinical and radiological parameters.

MATERIAL AND METHODS

Thirty patients with an ACL-deficient knee, undergoing ACL reconstruction using the medial third of the patellar tendon, were enrolled in a prospective study over a 6 months period. ACL deficiency was confirmed clinically, radiologically (MRI) and by arthroscopy.

The cases were evaluated pre-operatively, immediately postoperatively, and at six months postoperatively by studying their patellar alignment and tracking with the help of clinical examination, conventional radiography as well as CT scans. The normal knees of the same patient were used as controls for the study.

The criteria for exclusion from the study included cases with an already deranged patellar alignment, presence of significant patellofemoral arthritis or a history of previous injury to the patella or extensor mechanism.

Clinical examination included the use of the Q-angle that was measured in all patients in both knees pre-operatively and postoperatively. The Q angle is formed by a line joining the anterior superior iliac spine to the center of the patella, and a second line from this point to the tibial tuberosity. Although this is not a fully reliable and reproducible measurement, it was taken as a rough clinical guide for patellar alignment in these cases. Conventional radiographic evaluation was done with tangential views (Merchant and Laurin views). The Merchant view was taken with the patient in the supine position with the knee flexed to 30°-45° with the beam

directed caudal and inferior 30° from the vertical. The Sulcus angle was measured between two lines connecting the deepest point of the femoral groove to the highest point of the femoral condyles. The Congruence angle was measured as the angle between the line bisecting the sulcus angle with the line connecting the apex of the sulcus to the lowest aspect of the patellar ridge. If the apex was lateral to the reference line, a positive value was designated and if medial to it, a negative value was given.

The Laurin view was taken with the patient in a sitting position and the knee flexed to 20°, with the X-ray beam directed cephalad and superior at an angle of 160° from the vertical. The lateral patellofemoral angle was determined by drawing a line across the femoral condyles and a second line along the lateral facet of the patella. If the two lines diverged laterally the patellar position was considered to be within normal limits. If the two lines were parallel or converged laterally a tendency towards subluxation or dislocation was suspected.

CT scan was done to assess the tracking of the patella in the static mode. Three 5-mm cuts were taken at the widest portion of the patella with the knee in flexion of 0°, 15° and 30° flexion and the sulcus and congruence angles were measured in all cuts. Special wooden frames with fixed angles of 15° and 30° which would support the leg during CT, were constructed in order to get the same degree of knee flexion in all cases, so as to ensure reproducibility of the scans. The reduction in number of cuts helped in reducing the amount of radiation exposure.

All the patients were reviewed again after a period of 6 months following surgery when the special views and CT scan were repeated and the same parameters reassessed. All initial investigations were done one week pre-operative, and 6 months post-operative values were assessed to see if there was any change on radiograph or CT in the patellar alignment after harvesting the medial third of the patellar tendon. Descriptive statistical analysis of the collected data was performed. Data was expressed as mean \pm standard deviation and comparison was carried out using t-test and paired t-tests.

RESULTS

There were 26 males and 4 females with the average age at surgery of 26.9 years. (range 17 to 45 years). Both sides were affected equally (15 cases each).

The average Q-angle on the operated side pre-operatively was $14.32 \pm 1.67^\circ$ and postoperatively

Table I. — Q-angle (average)

| | Operated | Control |
|---------------|------------------------|------------------------|
| Pre-operative | $14.32 \pm 1.67^\circ$ | $14.50 \pm 1.74^\circ$ |
| Postoperative | $14.87 \pm 1.55^\circ$ | $14.80 \pm 1.45^\circ$ |

Average values of preoperative and postoperative Q angle measurements in operated and control knees.

Table II. — Merchant's view – congruence angle

| | Operated | Control |
|---------------|-------------------------|------------------------|
| Pre-operative | $-13.86 \pm 6.70^\circ$ | $11.95 \pm 5.43^\circ$ |
| Postoperative | $-12.10 \pm 7.07^\circ$ | $10.83 \pm 7.23^\circ$ |

Average values of pre-operative and postoperative measurements of congruence angle, in radiographs, in both operated and control knees.

was $14.87 \pm 1.55^\circ$. In eight of the 30 postoperative knees, a difference in Q-angle in comparison to the control knees was noticed. There was an average increase of 1.83° in the postoperative Q-angle of 6 knees in comparison to preoperative values, while in 2 knees it was found to have decreased. This however, was statistically insignificant ($p = 1.710$). A similar change in value was also noticed in controls, which was attributed to observer error (table I).

None of the operated knees showed any tendency for lateral subluxation as evaluated by the Merchant view. All of them had a negative value of the congruence angle (normal range -24° to -5°). The average preoperative congruence angle of affected knees was $-13.86 \pm 6.70^\circ$ and the postoperative congruence angle was $-12.10 \pm 7.07^\circ$. Although a slight average change was seen towards the positive side, indicating a mild displacement, the change was not significant ($p = 0.832$). The change in the angle was not always towards one side, and this discordance was perhaps a reflection of the observer error in assessing these radiographs. Even in the control knees, we found a similar change in the congruence angle on radiographs, which was again attributed to observer error. Thus no gross difference in the congruence angle measured on Merchant view in the pre and post-operative knees was observed (table II).

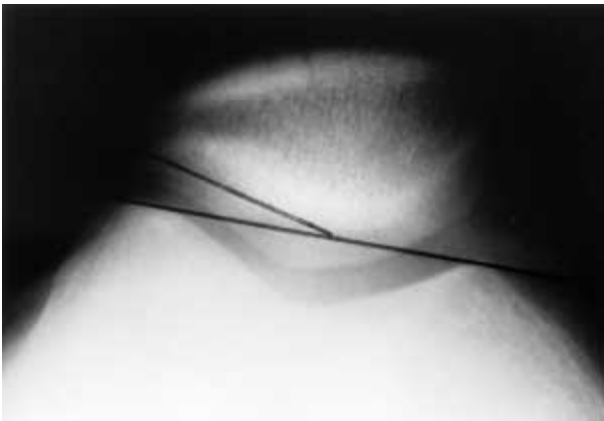

Fig. 2A. — Preoperative radiograph (Laurin's view) showing normal patellofemoral angle.

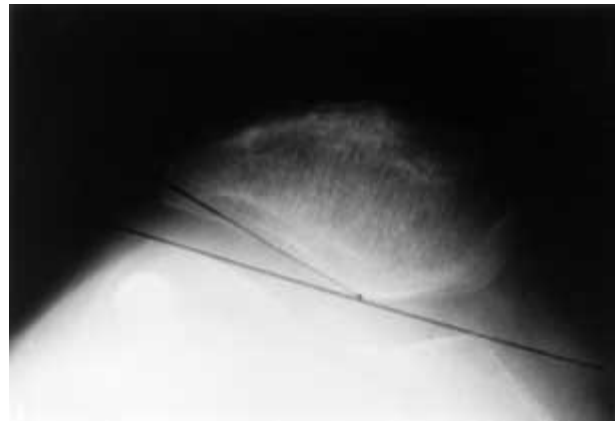

Fig. 2B. — Same case, 6 months postoperative, showing no change in the lateral patellofemoral angle.

Table III. — CT scan measurements

| Congruence angle | Operated | Control |
|---------------------------|---------------|----------------|
| Pre-operative (Angle 0°) | 23.50 ± 9.72 | 22.77 ± 11.76 |
| Postoperative (Angle 0°) | 19.53 ± 12.71 | 21.27 ± 13.65 |
| Pre-operative (Angle 15°) | -8.14 ± 7.70 | -10.19 ± 5.40 |
| Postoperative (Angle 15°) | -8.67 ± 7.85 | -9.47 ± 6.64° |
| Pre-operative (Angle 30°) | -9.77 ± 6.14 | -10.27 ± 5.65° |
| Postoperative (Angle 30°) | -7.43 ± 7.89 | -7.37 ± 5.42° |

Mean values of pre-operative and postoperative measurements of congruence angle, in CT scans, in both operated and control knees, at 0°, 15° and 30° of flexion respectively.

The lateral patellofemoral angle as measured in Laurin's view (expressed as normal or abnormal value) was found to be normal in all pre-operative and postoperative knees as well as in the controls. This indicated that there was no lateral tilt in any of the knees, either before or after surgery.

The congruence angles measured with CT scan in axial cuts of the knee in full extension showed a positive value in both controls and affected side in pre- as well as postoperative films. The average pre- and postcongruence angles of controls in this position are given in table III. The similar values for the operated knees were also changed, and such changes in the measurements were statistically insignificant ($p = 0.839$, $p = 0.251$) respectively.

The congruence angles in controls measured at 15° and 30° of knee flexion showed a minor change in average pre- and postoperative value (table III).

Similar values for the operated cases were $-8.14 \pm 7.70^\circ$ and $-8.67 \pm 7.85^\circ$ respectively at 15° flexion and $-9.77 \pm 6.14^\circ$ and $-7.43 \pm 7.29^\circ$ at 30° flexion. These changes in congruence angle were also not significant statistically. Although there was a discordance in the congruence angle measurement in these cases, which was not significant. We found four cases out of the 30 evaluated (all 4 on the left side) showing an abnormal lateralisation of the patella in postoperative films which was considered important; however this could not be correlated to any symptoms. The pre- and postoperative congruence angles of these four cases at 15° were found to be changed by an average of 12°, and by an average of 19° when measured at 30° flexion, suggestive of lateralisation of the patellae.

DISCUSSION

Complications and problems related to the donor site defect and its healing process are one of the major reasons why the use of the Bone-Patellar-Bone graft for ACL reconstruction is falling into some disrepute. Complications include patella fracture, patellar tendon avulsion, patella infera and potentially medial or lateral subluxation of the patella.

Harvesting of the medial third of the patellar tendon was done with some theoretical advantages in mind (Hertel P, personal communication). There is the need for only one cut in the tendon, the attach-

ment of the tendon on the patella is curved and when this end is used as the anterior distal edge of the reconstructed graft, it may reproduce some of the original ACL's attachment. The incision can be deepened fairly easily through the capsule and synovium to convert the procedure to a "mini-arthrotomy" if there are technical problems with a purely arthroscopic ACL reconstruction, without significantly compromising knee stability or postoperative rehabilitation. However a justifiable apprehension seems to be the fact that with medial third harvesting, the potential for lateral subluxation may exist. This would lead to patellofemoral pain and misalignment, with the potential for late degeneration.

Until 2001, the literature had no clear study which had analysed this after the use of the medial third of the PT, although some authors had demonstrated alignment alterations after ACL reconstruction itself (10), and some had studied these alterations after central third tendon harvesting. Our study was a preliminary attempt to try and formulate a fairly reproducible method of pre and post-operative patellar alignment assessment with CT scans. Although Q angles were measured in this study, their reproducibility is very doubtful, and these were used as a rough clinical guide.

The healing process of the donor defect has been extensively studied, with investigators using ultrasound and MRI to demonstrate the tendon hypertrophy and healing with scar tissue (9). However no major investigation has been done to examine the patellar alignment after graft harvesting. In a series studying the patellar alignment after central third PT harvesting, a 4.7° change in Merchant's angle was found at 2-year follow up by Muellner *et al* (10). The only study examining the change after medial third PT harvesting was by Moebius *et al* (9), who used US to assess PT thickness and width, and tangential radiographs at 30° to see for misalignment. An added aspect to this study was the evaluation of two subsets of patients, with follow-up periods of less than 30 months and those with follow-up more than 30 months, to see for short term and long term changes. They concluded that the tendon area healed adequately, with a final cross section area of 95% of the contralateral limb ;

no significant lateral shift was noted, although there was a slight non-significant lateral displacement. This was in contrast to the medial displacement observed by some authors after use of the central third PT for grafting.

The inaccuracy of radiological assessment of the patellar position is reflected in many facts. Conventional radiographic methods for measuring patellofemoral alignment employ tangential radiographs, which require some element of knee flexion, and may not take into account hip rotations. CT scans are an additional and more accurate methodology which allows the measurement of the patellar alignment in full extension, when the stabilizing function of the lateral femoral condyle is diminished as the patella disengages from the patellofemoral groove (6). This is thought to be a better reflection of the medial soft tissue integrity and better displays subluxation, as well as allows reliable consistency with positioning of the leg in specified angles (8). We thus used CT scans in addition to conventional radiographs in an attempt to increase accuracy as well as to include the alignment in full extension.

This small study shows clearly that no major changes occur after the harvesting of the medial third of the patellar tendon for grafting the ACL. The premise that there is a potential for lateral tilt or shift of the patella is thus unjustified. Changes in the patellar height and congruence angle are perhaps similar to those seen after harvesting the medial third, which could be explained by other factors. Previous reports have highlighted the fact that any procedure around the patellar tendon, even without harvesting it, can cause length changes (9, 14).

There are certain inherent lacunae in this study. Firstly the number of cases is small, but we feel that this preliminary work opens up avenues for future research, with studies on a larger scale designed to correlate radiographs, CT scans, cine radiology and even dynamic MRIs where available. Static measurements with the quads relaxed and with muscle contracted could have potentially different values. A second part of this study will be to analyse these same cases after an additional two years of follow-up to see for late changes in align-

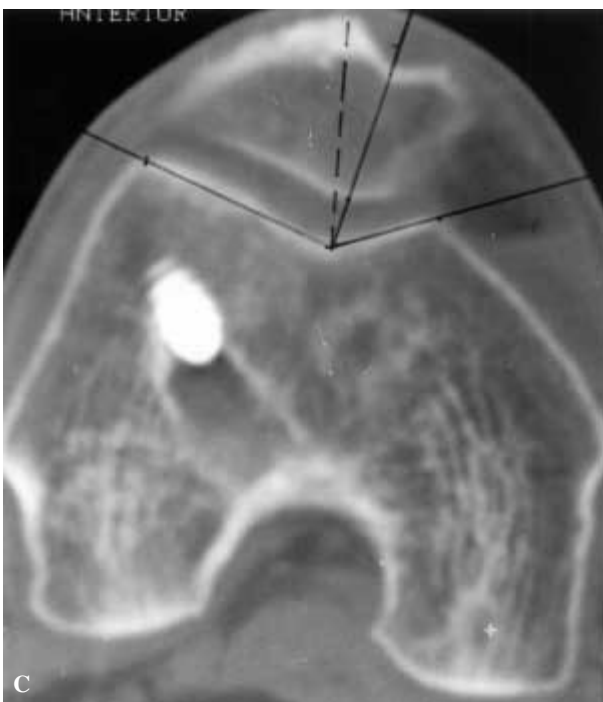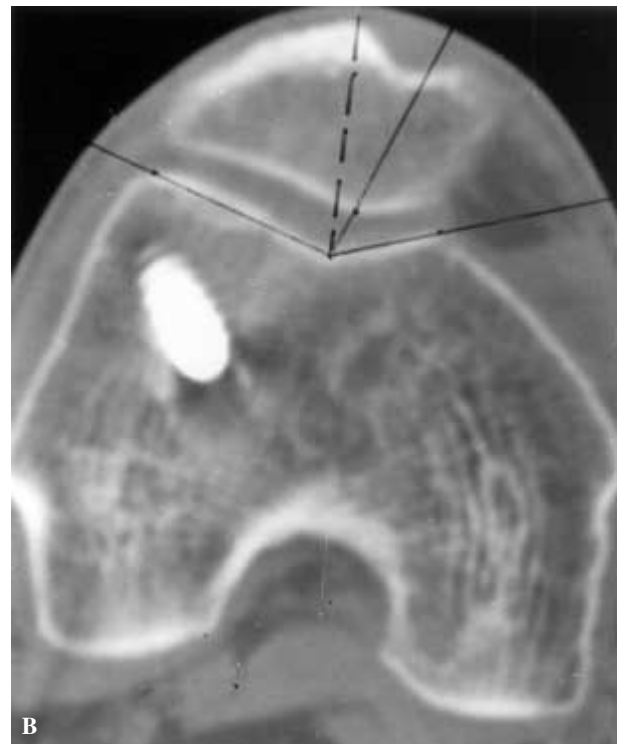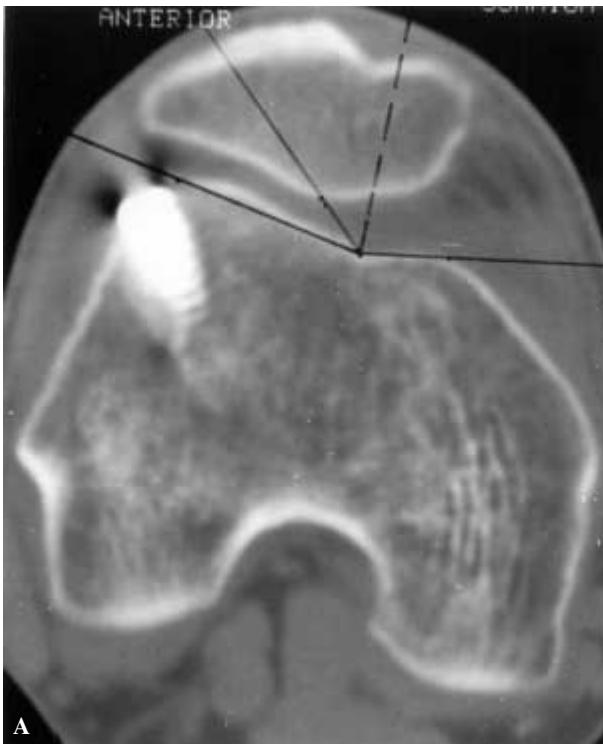


Fig. 3A. — CT scan of the same patient, 6 months postoperative, in full extension. Note the abnormal congruence angle in this position.

Fig. 3B. — Same knee in 15° flexion showing normal congruence angle.

Fig. 3C. — The congruence angle remains unchanged in further flexion to 30°.

ment. Moebius *et al* (9) have found different values in cases examined before and after 30 months of follow-up. Merchant's congruence angle values

were very variable in the initial stages, with somewhat more increased values in cases with shorter follow-up, and seemed to decrease to non-significant levels in cases with follow-up of more than three months.

Harvesting of the medial third of the patellar tendon is performed without injuring the medial patellofemoral ligament, the patellomeniscal ligament or the medial retinacular fibers. These provide more than 75% of the restraining forces that prevent lateral patellar displacement. The mild lateral displacement observed in some cases with short follow up by Moebius *et al* (9) may be due to the defect in the scar tissue in the early phases; with scar consolidation, the balance between medial and lateral structures is restored. Another factor may be the medial quadriceps strength, which is

restored later after adequate rehabilitation protocols have been employed, and this may be important for stabilising the patella medially.

In conclusion, our preliminary work indicates that there is no significant lateral subluxation of the patella after harvesting the medial third of the tendon; the problems are the same which are inherent in harvesting the middle third of the tendon, and both procedures are comparable. However more accurate and reproducible methods for the alignment assessment need to be developed, and this attempt by using a cheap device to ensure reproducibility on CT scan assessment is the first step in that direction. Another point of note is that the assessment needs to be done serially as late as 1-2 years after the procedure to assess the effect of muscle development on patellar positioning, and perhaps more advanced dynamic studies using both cine MRIs and other devices may be the option of the future.

REFERENCES

1. **Alm A, Gillquist J.** Reconstruction of the anterior cruciate ligament by using medial third of the patellar ligament. *Acta Chir Scand* 1974 ; 140 : 289-96.
2. **Dandy DJ.** Some clinical aspects of reconstruction of chronic anterior cruciate ligament deficiency. *Ann R Coll Surg Engl* 1995 ; 77 : 290-298.
3. **De Maio, Noyes FR, Mangine RE.** Principles of aggressive rehabilitation after reconstruction of anterior cruciate ligament. *Orthopaedics* 1992 ; 15 : 385-392.
4. **Eriksson E.** Stalked patellar tendon graft in reconstruction of the anterior cruciate ligament. *J Bone Joint Surg* 1994 ; 76-B : 193-197.
5. **Inoue M, Shino K, Hirose H, Hirobe S, Ono K.** Subluxation of patella. *J Bone Joint Surg* 1998 ; 70-A : 1331-1337.
6. **Johnson RJ, Beynonn BD, Nichols CE, Renstrom PAFH.** Current concepts review. The treatment of injuries of the anterior cruciate ligament. *J Bone Joint Surg* 1992 ; 74A : 140-151.
7. **Johnson RJ, Eriksson E, Haggmark, Pope MH.** Five to ten year follow-up evaluation after reconstruction of anterior cruciate ligament. *Clin Orthop* 1984 ; 193 : 122-139.
8. **Martinez S, Korbkin M, Fondren FB, Hedlund LW, Goldner JL.** Computed tomography of the normal patellofemoral joint. *Invest Radiol* 1983 ; 18 : 249-253.
9. **Moebius UG, Anastasios D, Georgoulis et al.** Alterations of the extensor apparatus after anterior cruciate ligament reconstruction using medial third of the patellar tendon. *Arthroscopy* ; 17 : 953-959.
10. **Muellner T, Kaltenbrunner W, Nicolic A, Mittelboeck M, Schabus R, Vescei V.** Anterior cruciate ligament reconstruction alters the patellar alignment. *Arthroscopy* 1999 ; 15 : 165-168.
11. **Noyes FR, Butler DL, Grood ES, Zernicke RF, Hefzy MS.** Biomechanical analysis of human ligament grafts used in knee ligament repair and reconstruction. *J Bone Joint Surg* 1984 ; 66-A : 344-352.
12. **Paterson FW, Trickey EL.** Anterior cruciate ligament reconstruction using part of the patellar tendon as free graft. *Nord Med* 1994 ; 109 : 44-46.
13. **Sachs RA, Daniel DM, Stone ML, Grfein RF.** Patellofemoral problems after ACL reconstruction. *Am J Sports Med* 1985 ; 17 : 760-765.
14. **Schaffer BS, Tibone JE.** Patellar tendon length change after anterior cruciate ligament reconstruction using the midthird patellar tendon. *Am J Sports Med* 1993 ; 21 : 449-454.
15. **Steen H, Tseng KF, Goldskin SA, Carpenter JE.** Harvest of patellar tendon (bone-tendon-bone) autograft for ACL reconstruction significantly alters surface strain in the human patella. *J Biochem Eng (Am)* 1999 ; 121 : 229-233.
16. **Wirth CJ, Refior HJ.** The plastic replacement of old ruptured cruciate ligaments. II. Late results. *Z Orthop Ihre Grenzgeb* 1976 ; 114 : 922-930.