

Results of surgical treatment of osteoid osteoma of the spine

Ufuk AYDINLI¹, Cagatay OZTURK¹, Salim ERSOZLU¹, Gulaydan FILIZ²

Ten percent of all osteoid osteomas are located in the spine ; they represent the most common cause of painful scoliosis in adolescents. The recommended treatment is surgical excision of the nidus. Nine patients with osteoid osteoma of the spine underwent surgical treatment between 1996 and 2002. Complete nidus removal was performed in all patients and the diagnosis was made by frozen sections intraoperatively. The follow-up period was 27 months. Scoliosis was present in five of the cases (55.5%). All deformities improved during the postoperative follow-up period. All nine patients with the diagnosis of osteoid osteoma who had operations had histological confirmation. All patients had immediate and complete relief of pain after surgery. There were no complications and no local recurrences after a follow-up of two years. In the authors' opinion, removal of the nidus by open surgical technique remains a valid method of treatment for osteoid osteoma of the spine.

INTRODUCTION

In 1953, Jaffe (8) defined osteoid osteoma as a benign bone neoplasm characterised by the formation of a nidus of bone surrounded by fibrovascular tissue and a dense sclerotic bone margin. Osteoid osteomas are small, well confined, and generally self-limited in growth potential. The basic microscopic pattern in osteoid osteoma is a bone-forming tumour containing numerous osteoblasts producing osteoid and woven bone. Its size is the main distinguishing feature between it and an osteoblastoma and varies between 1.5 and 2 cm (4, 7, 13, 23).

Osteoid osteomas are uncommon. They comprise approximately 3% of primary bone tumours and 11% of all primary benign bone tumours (22). Most

osteoid osteomas are found in the first three decades of life. Classic symptoms are pain localised to the lesion, increased pain with activity, pain at night and pain responding to aspirin. Routine roentgenograms are often diagnostic, but bone scan or computed tomography commonly is required to accurately localise the lesion. The recommended treatment is surgical excision of the nidus (18, 22). This is performed through an open procedure.

The spine is the location of 10% of all osteoid osteomas (2, 9, 20). Scoliosis is reported in 70% of the cases and it is the most common cause of painful scoliosis in adolescents (21). It is considered to be secondary to muscle spasm and inflammatory changes of the adjacent soft tissues on the side of the lesion (10, 19). Osteoid osteomas tend to involve the posterior component of the spine (23).

The purpose of this retrospective study was to analyse the clinical findings, radiologic findings and treatment results of the cases with osteoid osteoma of the spine treated by open surgery.

From Uludag University, Bursa, Turkey.

Ufuk Aydinli, MD : Orthopaedic Surgeon, Professor of Orthopaedics.

Cagatay Ozturk, MD : Orthopaedic Resident.

Department of Orthopaedics and Traumatology, Uludag University, Bursa, Turkey.

Gulaydan Filiz, MD : Associate Professor, Department of Pathology, Bursa, Turkey.

Correspondence and reprints : Ufuk Aydinli, Uludag universitesi, Tip Fakültesi Hastanesi, Ortopedi ve Travmatoloji A.D., Görükle Kampüsü, 16059 Bursa, Turkey.

E-mail : anakha@superonline.com.

© 2003, Acta Orthopædica Belgica.

Table I. — Data of the patients

Patient	Age (y)	Sex	Site	Side	Part	Duration of Sx (months)	Preoperative deformity	Recurrence	Postoperative deformity	Follow-up (months)
1	7	F	Th 9	Left	Facet	3	+	-	Improved	14
2	35	M	L 2	Left	Pedicle	6	-	-	-	14
3	14	M	L3	Right	Pedicle	4	+	-	Improved	18
4	14	M	Th 11	Right	Pedicle	6	+	-	Improved	60
5	14	F	L 3	Right	Facet	1	+	-	Improved	31
6	22	F	L 3	Right	Pedicle	12	+	-	Improved	27
7	8	F	L 4	Left	Pedicle	7	-	-	-	66
8	16	M	Th 11	Left	Pedicle	6	-	-	-	8
9	18	M	L4	Left	Pedicle	4	-	-	-	4

MATERIALS AND METHODS

Nine patients with osteoid osteoma of the spine underwent surgical treatment in the Department of Orthopaedic Surgery of Uludag University Faculty of Medicine between 1996 and 2002. The ages of the patients ranged between 7 and 35 years. Five patients (55.5%) were male and four (44.5%) were female. We reviewed the hospital notes, pre-operative and postoperative images and the histological findings of all patients.

Three (33.3%) tumors were in the thoracic spine (Th9, Th11, Th11); six (66.6%) were in the lumbar spine (one in L2, three in L3, two in L4). There was no tumour involvement in the cervical spine and sacrum. All tumours were located mainly in the posterior part of the spine. Seven (77.7%) osteoid osteomas were located in the pedicle and two (22.2%) were in the facet region. Four (44.5%) tumors were on the right side, five (55.5%) on the left.

Typical pain was the chief complaint in all patients accompanied by scoliosis, concave to the effected side, in 5 (55.5%) patients also. Complete nidus excision was performed in all patients and the diagnosis was controlled by frozen sections intraoperatively. All patients except one did not need a secondary operation and except for this patient, no posterior instrumentation was used for stabilisation during the operative procedure. All patients were allowed to mobilise after the operation.

The follow-up period ranged from 4 to 66 months; an average of 27 months. The data of the cases are shown in table I.

RESULTS

The duration of pre-operative pain ranged between one and 12 months (average 5 months).

There were no neurological manifestations in the patients pre-operatively. Patients with lumbar involvement also had buttock and leg pain due to root irritation. All patients had open removal of the lesion. In one case, a second operation was required due to incomplete removal of the nidus in the first operation because of the extension of the tumour beneath a nerve root. After the second operation, the patient was completely symptom-free.

On plain radiographs, most of the lesions were osteosclerotic with or without identification of the nidus. Computed tomography clearly showed the characteristics of the lesions (fig 1). Scoliosis was present in five of the cases (55.5%). The curves were concave to the affected site and all deformities improved during the postoperative follow-up period (fig 2 a, b). However, MRI studies were performed in three patients previously, due to the pain complaints. The lesions were not diagnosed. After retrospective analysis of these MR images, the lesions could indeed be identified (fig 3).

The diagnostic accuracy for osteoid osteoma is excellent. In our series, there were no diagnostic errors. All nine patients with the diagnosis of osteoid osteoma who had operations had histological confirmation. Histologically, the tumour is characterised by a rich fibrovascular stroma and abundant prominent osteoblasts rimming interspersed spicules of woven bone arranged in a chaotic fashion.

All patients had immediate and complete relief of pain after surgery. There were no complications and no local recurrences at a follow-up of two years. The patients remained in hospital for a mean duration of 4 days.

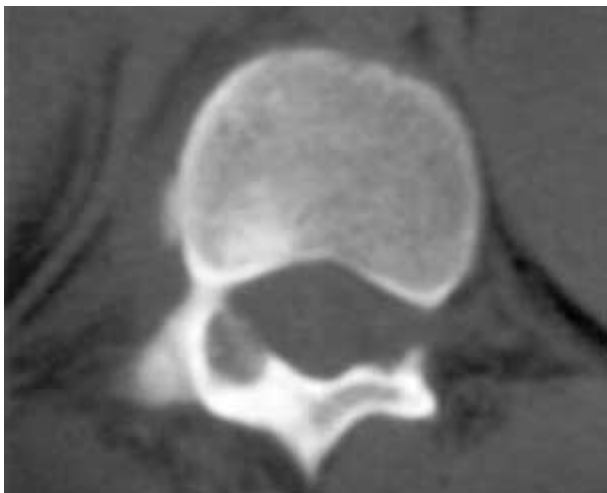


Fig. 1. — CT scan of Case 4 showing the nidus in the right pedicle.

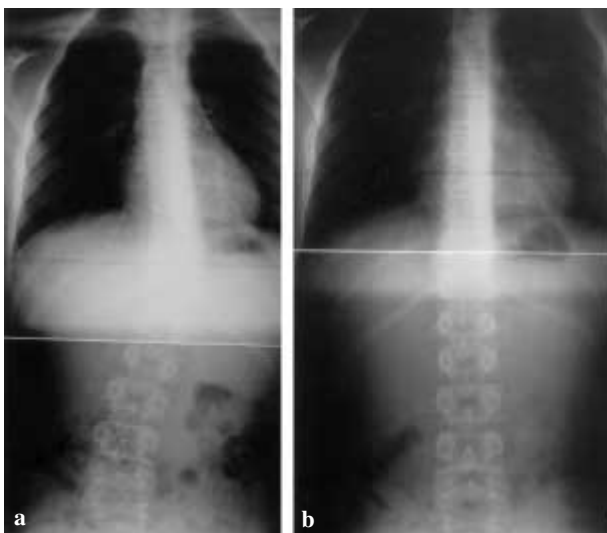


Fig. 2. — a. Anteroposterior radiograph of the spine in Case 4 showing scoliosis.
b. Anteroposterior radiograph of the same patient showing improvement of the deformity at the follow-up of 4.5 years.

DISCUSSION

Osteoid osteoma is a benign tumour of the bony tissue and involves the spine in 10% of the cases (2, 9, 20). The hallmark of osteoid osteoma histologically is the central nidus, which is primarily osteoid, surrounded by fibrous stroma. This renders the nidus radiolucent on radiographs and translates

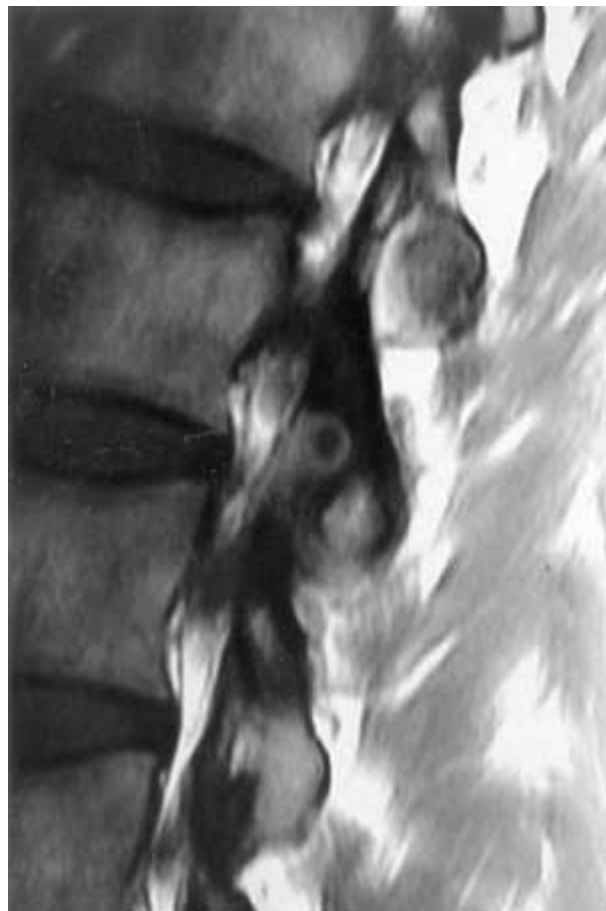


Fig. 3. — MR image of Case 2 showing the nidus surrounded by oedema and reactive sclerotic bone ; the nidus had not been identified initially.

into low attenuation on computed tomography, the diagnostic modality of choice. The nidus is in turn surrounded by sclerosis.

The patients' main symptom was leg and/or back pain depending on the anatomic localisation of the nidus. Different theories have been proposed as the cause of pain (9, 13, 15). The pain has been shown to abate if one waits long enough (4-8 years) as the osteoid tissue of the nidus matures into bone tissue (2).

In the literature, the incidence of scoliosis in patients with osteoid osteoma or osteoblastoma has been reported as between 25% and 70% (14, 18). It was demonstrated that asymmetrically located lesions in the thoracic or lumbar spine are associated

with the greatest risk of developing scoliosis (21). The question then arises as to why all patients with lesions in the spine do not have spinal deformity. As it was mentioned earlier, scoliosis is due to muscle spasm secondary to an inflammatory reaction around the tumour. In a study of osteoid osteoma of the spine, only 63% of the cases were associated with surrounding inflammatory changes (1). It is clear, therefore, that not all lesions produce an inflammatory response in adjacent soft tissues, and such lesions located in the spine would not be expected to produce a scoliosis (1). Kyphosis also may be produced by destructive lesions that cause wedge collapse of the vertebral body. Conversely, hyperlordosis has been described as a consequence of symmetric posterior muscle spasm (2). In the current study, 5 of 8 patients (62.5%) were diagnosed with scoliosis. The osteoid osteomas were located in the concave side of the apex. It has been reported that most patients with short duration of symptoms (< 15 months) had improvement of the scoliosis after removal of the nidus; however, in the patients with long duration of the symptoms (> 15 months), scoliosis becomes structural and may not improve after surgery (18, 19). In our study, the patients with back pain who had evidence of scoliosis improved during the postoperative follow-up period.

Because there are no specific MRI features, MRI is not a routine investigation modality in osteoid osteoma. On MRI, one is made aware of a local inflammatory process with oedema in the bone marrow and adjacent soft tissues (3). The nidus is rarely appreciated in the middle of the oedema and reactive sclerotic bone. Extensive soft tissue and bone marrow oedema observed on MRI of the spine, in a patient presenting with back pain, should be further evaluated with a bone scan or computed tomography in order to identify osteoid osteoma as the potential aetiology of the pain. The tumour generally appears as a hot spot on scintigraphy. Computerised tomography is the method of choice for the definite identification and localisation of the nidus and for optimal assessment of the tumour matrix. MRI may have a value only to assess the effect of the lesion on the spinal canal and spinal cord (1).

In the differential diagnosis, aneurysmal bone cyst and giant cell tumour should be considered. Although aneurysmal bone cysts typically involve the posterior elements and giant cell tumours usually involve the body of the vertebrae alone, these tumours are usually lytic findings on plain radiographs. Osteoid osteoma shows reactive bone sclerosis around the nidus (17). Because osteoid osteoma is difficult to detect radiologically, in patients with persistent back pain or with painful scoliosis, a bone scan or computed tomography should be obtained to rule out the presence of these lesions (6).

The recommended treatment for an osteoid osteoma causing disabling pain and/or deformity is complete removal of the nidus (2, 18, 20). However, the difficulty of identifying the lesion, the possibility of incomplete removal and creating instability due to extensive resection and the risk of neurological injury are potential problems during surgery. If the removal of the nidus is not complete, pain persists and an additional operation is necessary to complete removal of the nidus. A case of incomplete removal was encountered due to the extension of the nidus underneath the nerve root. A second operation was performed and the nidus was removed completely under magnification. Posterior instrumentation and fusion was performed due to instability.

In recent years, some authors advocated several different techniques of percutaneous removal of the nidus in osteoid osteoma (6, 11, 16, 25). The examples of these methods are high-frequency radio-wave ablation, thermo-coagulation and laser coagulation techniques. Percutaneous methods have some obvious advantages such as reduced cost and shorter stay in hospital. They appear to be particularly suited to deep sites, such as in the neck of the femur and in the pelvis. However, these methods are not indicated in most osteoid osteomas of the spine and of the small bones. They, especially laser or thermo-coagulation, should not be used when the lesion is close to a neurovascular bundle (5, 25). The primary cure rates of percutaneous methods have been reported between 40% and 83% (5). With open surgery, these rates are close to 100% in most series (5, 12).

CONCLUSION

In the presence of painful scoliosis in adolescents, osteoid osteoma of the spine should be kept in mind for the differential diagnosis. Careful pre-operative planning with advanced imaging techniques is mandatory for complete surgical removal of the nidus. However, one should carefully explore the area under magnification during the surgery, especially if the nidus is close to neurological structures, to ensure complete removal of the nidus.

REFERENCES

1. Assoun J, Richardi G, Railhac JJ. Osteoid osteoma : MR imaging versus CT. *Radiology* 1994 ; 19 : 217-223.
2. Azouz E M, Kozlowski K, Marton D, Sprague P, Zerhouni A, Asselah F. Osteoid osteoma and osteoblastoma of the spine in children : Report of 22 cases with brief literature review. *Pediatr Radiol* 1986 ; 16 : 25-31.
3. Biebuyck JC, Katz LD, McCauley T. Soft tissue edema in osteoid osteoma. *Skeletal Radiol* 1992 ; 22 : 37-41.
4. Campanacci M. *Osteoid Osteoma*. Springer-Verlag, Bologna, 1990, pp 371-373.
5. Campanacci M, Ruggieri P, Gasbarrini A, Ferraro A, Campanacci L. Osteoid osteoma. Direct visual identification and intralesional excision of the nidus with minimal removal of bone. *J Bone Joint Surg* 1999 ; 81-B : 814-819.
6. Cove JA, Taminiau AH, Obermann WR, Vanderschuuren GM. Osteoid osteoma of the spine treated with percutaneous computed tomography-guided thermocoagulation. *Spine* 2000 ; 25 : 1283-1286..
7. Gitelis S, Schjowicz F. Osteoid osteoma and osteoblastoma. *Orthop Clin North Am* 1989 ; 20 : 313-325.
8. Jaffe HL. Osteoid osteoma. *Proc R Soc Med* 1953 ; 46 : 1007-1012.
9. Jackson RP, Reckling FW, Mantz FA. Osteoid osteoma and osteoblastoma : Similar histologic lesions with different natural histories. *Clin Orthop* 1977 ; 128 : 303-313.
10. Keim HA, Reina EG. Osteoid osteoma as a cause of scoliosis. *J Bone Joint Surg* 1975 ; 57-A, 159-163.
11. Labbe JL, Clement JL, Duparc B, Poey C, Railhac JJ. Percutaneous extraction of vertebral osteoid osteoma under computed tomography guidance. *Eur Spine J* 1995 ; 4 : 368-371.
12. Lefton DR, Torissi JM, Haller JO. Vertebral osteoid osteoma masquerading as a malignant bone or soft-tissue tumor on MRI. *Pediatr Radiol* 2001 ; 31 : 72-75.
13. Mirra JM. *Bone Tumors : Clinical, Radiologic and Pathologic Correlations*. Lea & Febiger, London, 1989, pp 226-248.
14. Nemoto O, Moser RP, Jr, Van Dam BE, Aoki J, Gilkey FW. Osteoblastoma of the spine : A review of 75 cases. *Spine* 1990 ; 15 : 1272-1280.
15. Nagues P, Marti-Bonmati L, Aparisi F. MR imaging assessment of juxtacortical edema in osteoid osteoma in 28 patients. *Eur Radiol* 1998 ; 8 : 236-238.
16. Osti OL, Sebben R. High-frequency radio-wave ablation of osteoid osteoma in the lumbar spine. *Eur Spine J* 1998 ; 7 : 422-425.
17. Ozaki T, Liljenqvist U, Hillmann A, Halm H, Lindner N, Gosheger G, Winkelmann W. Osteoid osteoma and osteoblastoma of the spine : experiences with 22 patients. *Clin Orthop* 2002 ; 39 : 394-402.
18. Pettine KA, Klassen RA. Osteoid osteoma and osteoblastoma of the spine. *J Bone Joint Surg* 1986 ; 68-A : 354-361.
19. Ransford AO, Pozo JL, Hutton PAN. The behaviour pattern of scoliosis associated with osteoid osteoma or osteoblastoma of the spine. *J Bone Joint Surg* 1984 ; 66-B : 16-20.
20. Raskas DS, Graziano GP, Heidelberger KP, Hensinger RN. Osteoid osteoma and osteoblastoma of the spine. *J Spinal Disord* 1992 ; 5 : 204-211.
21. Saifuddin A, White J, Sherazi Z, Shaikh MI, Natali C, Ransford AO. Osteoid osteoma and osteoblastoma of the spine. Factors associated with the presence of scoliosis. *Spine* 1998 ; 23 : 47-53.
22. Sybert GW. *Osteoid Osteoma and Osteoblastoma of the Spine*. W. B. Saunders Company, Philadelphia, 1990, pp 117-127.
23. Unni KK. *Osteoid Osteoma*. Lippincott Raven, Philadelphia, 1996, pp 121-130.
24. Ward WG, Eckardt JJ, Shayeestefhar S. Osteoid osteoma diagnosis and management with low morbidity. *Clin Orthop* 1993 ; 291 : 229-235.
25. Witt JD, Hall-Craggs MA, Ripley P, Cobb JP, Bown SG. Interstitial laser photocoagulation for the treatment of osteoid osteoma. *J Bone Joint Surg* 2000 ; 82-B : 125-128.