



## Septic arthritis of a lumbar facet joint Case report and review of the literature

Mahmoud SMIDA, Mejed LEJRI, Hajer KANDARA, Meriem SAYED, Ferid BEN CHEHIDA, Maher BEN GHACHEM

Septic arthritis of a lumbar facet joint (SALFJ) is a very rare condition. It has mostly been described in adults. Only one other paediatric case has been reported.

We present a case of septic arthritis of the left L<sub>5</sub>-S<sub>1</sub> lumbar facet joint, associated with epiduritis and paraspinal abscess, in an 8-year-old boy.

Plain radiographs and Technetium bone scan were negative. The diagnosis was made by blood cultures, which isolated *staphylococcus epidermidis*, and by MRI. The child was treated successfully with antibiotics only.

### CASE REPORT

An 8-year-old boy without antecedents was hospitalised with acute severe back pain since 5 days, without a history of trauma.

Clinical examination revealed a temperature of 39°C, a left painful paraspinal mass, and stiffness of the lumbar spine. No neurological deficit was found.

Laboratory findings : a white blood cell count of 15.500/mm<sup>3</sup> with 90% polymorphs, and an erythrocyte sedimentation rate of 105 mm in the first hour. Two blood cultures were positive for *staphylococcus epidermidis*.

Plain radiographs of the lumbar spine did not reveal any bone lesion, except disappearance of the lumbar lordosis. Ultrasound detected only oedema of the paraspinal soft tissues corresponding to the paraspinal mass. Magnetic resonance imaging (MRI) was performed 3 days after admission and showed effusion in the left L<sub>5</sub>-S<sub>1</sub> facet joint, inflammatory changes in the adjacent paraspinal muscles,

and posterior epiduritis (fig 1). There was no evidence of discitis, vertebral osteomyelitis or psoas abscess. A three-phase Technetium-99 bone scintigraphy, performed 2 weeks after onset, demonstrated slight uptake laterally at the level of the paraspinal mass (fig 2).

The boy was treated conservatively with appropriate antimicrobials given intravenously for 10 days, then orally for one month. After one week of treatment, he became afebrile and free of pain. Eighteen months later he remained free of symptoms. Plain radiographs showed sclerosis of the subchondral bone of the left L<sub>5</sub>-S<sub>1</sub> facet joint.

### DISCUSSION

#### Epidemiology

Septic arthritis of a facet joint (SAFJ) is a very rare condition. In 2002 only 40 cases had been re-

---

*From Tunis Children's Hospital, Tunis, Tunisia.*

Mahmoud Smida, Assistant, Paediatric Orthopaedic Surgeon.

Mejed Lejri, Resident.

Hajer Kandara, Resident.

Maher Ben Ghachem, Professor of Paediatric Orthopaedics.

*Department of Paediatric Orthopaedics.*

Meriem Sayed, Paediatric Radiologist.

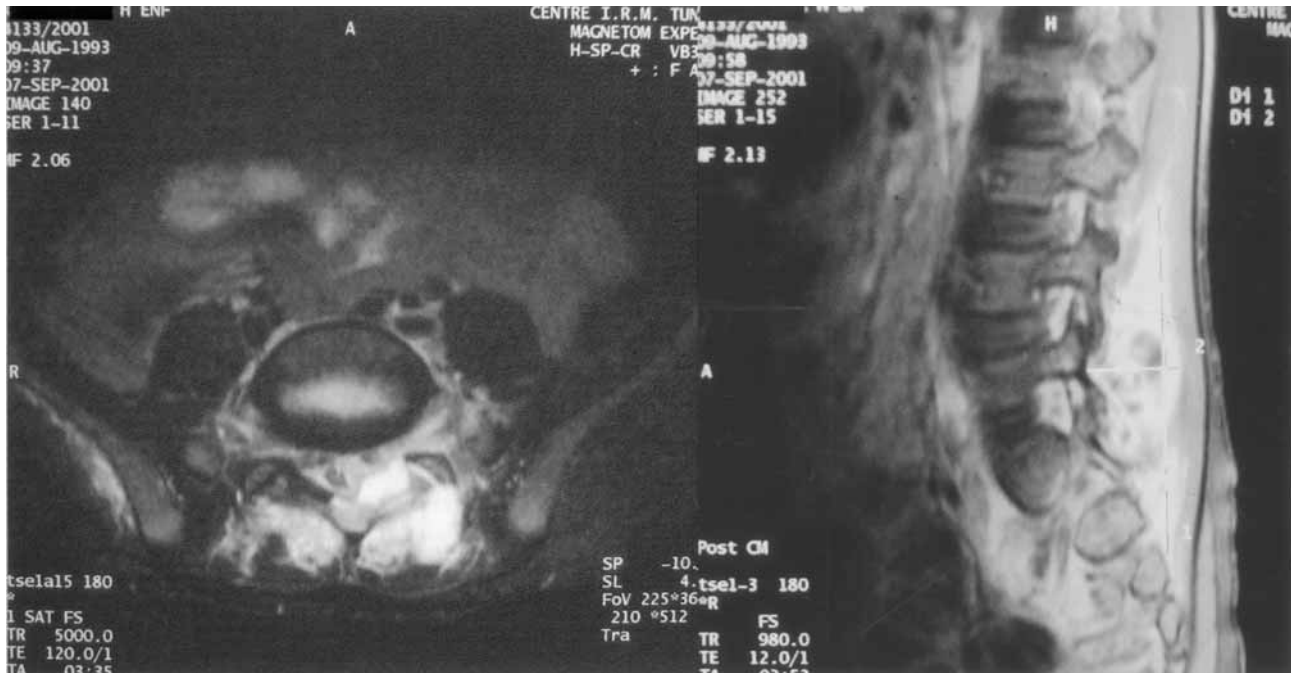
Ferid Ben Chehida, Professor of Paediatric Radiology.

*Department of Paediatric Radiology.*

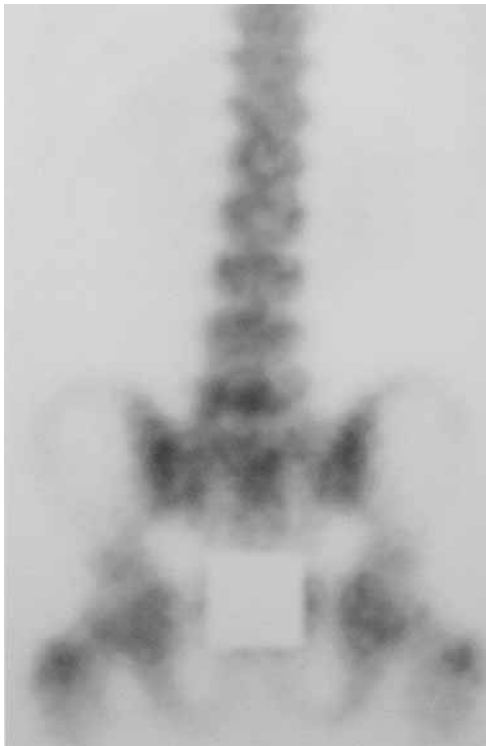Correspondence : Mahmoud Smida, Department of Paediatric Orthopaedics, Tunis Children's Hospital, 1007 Bab Saadoun, Tunis, Tunisia. E-mail : mahmoud.smida@rns.tn.

© 2004, Acta Orthopædica Belgica.

---



**Fig. 1.** — MRI : widening of left L<sub>5</sub>-S<sub>1</sub> facet joint with posterior epiduritis and left paraspinal abscess



**Fig. 2.** — Technetium bone scintigram : increased uptake at the level of the left L<sub>5</sub>-S<sub>1</sub> facet joint.

ported (21). The exact incidence of this entity is unknown. In 1981, David-Chaussé reported a single case of SAFJ in a series of 491 spinal infections : an incidence of 0.2% (5). This is less common than the 4% (6 of 140 cases of pyogenic spinal infection) reported by Muffoletto *et al* in 2001 (15). The paucity of reports and the discrepancy in occurrence may be partly explained by underdiagnosis, resulting from unfamiliarity with the condition (4, 15). Ergan *et al* think that SAFJ may be more common than is usually believed (9). There is a slight male preponderance among the cases collected from the literature by Muffoletto *et al* (17 out of 31 patients) (15). Adults are more frequently affected, at an average age of 60 years (6, 8, 9, 15). To our knowledge, only one other paediatric case has been reported : the patient was a 10-year-old boy (13). Our patient is probably the youngest with SAFJ. The lumbar spine is predominantly affected (8, 9, 15). According to Douvrin *et al*, only 3 cases of cervical SAFJ have been reported in the literature (8). We found only one reported case of thoracic SAFJ (19). Among 16 cases in which the level was specified, Ergan *et al* found involvement of the L<sub>4</sub>-

L<sub>5</sub> facet joint in 8 cases (50%) (9). Bilateral facet joint involvement at one level has also been described (7, 15). Immunodeficiency is a predisposing factor : diabetes mellitus, alcohol abuse and chronic steroid usage are the most common risk factors (8, 9, 15, 16).

### Aetiology

SAFJ is often haematogenous : septicemia and positive blood cultures (frequently *Staphylococcus aureus*) were mentioned many times (3, 8, 14). Likewise, one case was associated with endocarditis (6), and one with septic arthritis of the sternoclavicular joint (4). SAFJ can also be caused by contiguity, or by direct inoculation by epidural catheters, facet joint infiltrations, discectomies or spinal surgery (2, 3, 8, 14, 16, 17, 18).

The exact pathogenesis of SAFJ, and the reason why this condition is less common than discitis, remain unknown. Ergon *et al* thought about a relation with characteristics of the vascular supply (9). Halpin and Gibson reported a case arising after back strain ; he suggested that a secondary effusion or haemarthrosis in a facet joint allowed its colonisation by bacteria (12). Ergon *et al* and Derouet *et al* thought that degenerative lesions in the facet joints may constitute an increased risk for bacterial infection (6, 9).

### Clinical picture

The clinical picture of SAFJ is similar to that of spondylodiscitis. It includes back pain at rest and with activity. Patients may be febrile (1, 3, 8, 15), and may present with stiffness and a mass (4), as in our case. The intensity of pain and fever is variable (3, 4, 6, 9). Dauwe *et al* noted that forceful hyperextension sharpened the pain, whereas flexion reduced it ; lumbar motion was restricted in all directions, and the straight leg raising test increased the back pain (4). These clinical signs are not specific and may suggest other diagnoses like primary spinal muscle abscess (20), tumours (2, 8), or isolated epidural abscess (8, 15), but spondylodiscitis is usually suspected (3, 4, 8, 14, 15). In SAFJ, pain and tenderness tend to be situated more laterally. The com-

plaints start more acutely, with greater severity in the early stages (4, 9, 12, 15). In lumbar SAFJ, the pain may radiate into the flank, buttocks or thighs and tend to mimic other diagnoses, including acute lumbago, symptomatic sciatica (3, 4, 15, 17) or even pyelonephritis (1). Patients may present neurological complications, often radicular in nature, and sometimes severe deficits. Cauda equina syndrome was reported in some cases (8, 14, 15). Thus, a high index of clinical suspicion is necessary for early and accurate diagnosis to prevent neurological deficits in SAFJ. These neurological complications are produced by epidural abscess formation. In fact, infection of a facet joint may spread contiguously to the epidural space and to the paraspinal musculature (1, 3, 8, 9, 15). In the literature review of Douvrin *et al*, epidural abscess was reported in 50% of the cases (8). Combining previous series and their own cases, Muffoletto *et al* found an epidural abscess in 25%, epidural granulation in 38 % and a paraspinal abscess in 39% (15). This decompression into soft tissues may explain in some cases the benign clinical presentation (3, 12). Some authors think that facet joint, posterior epidural space and paraspinal muscles are involved concomitantly because of their common arterial supply (9, 14). Intradural extension has also been reported (21).

### Laboratory data

Laboratory data are similar to those found in spondylodiscitis. Leukocyte counts are inconsistently elevated (50% of the cases), but erythrocyte sedimentation rate (ESR) and C-reactive protein (CRP) are always elevated (4, 9, 14, 15). *Staphylococcus aureus* is the most commonly reported causative organism. Other bacteria, such as *streptococcus* and gram-negative rods, are reported less frequently (3, 6, 8, 9, 14, 15). *Staphylococcus epidermidis* has also been identified, exactly as in our case, but secondary to infection of an epidural catheter (18). Identification of the infecting organism is usually obtained by blood culture, which is positive in 50% of the cases (4, 8). Surgery or percutaneous aspiration of the facet joint or paraspinal abscess under fluoroscopic, ultrasonographic or

tomodensitometric guidance may directly isolate the germ (3, 6, 8, 9, 15). In some authors' opinion, aspiration is warranted only if blood cultures fail to recover the organism or if the septic nature of the arthritis is still in doubt (6, 9). Positive tissue cultures are found in 75% of the cases, and either positive tissue or positive blood cultures can be obtained approximately 95% of the time (15).

## Imaging

Clinical and biological data are often insufficient to diagnose SAFJ. Imaging studies are essential for diagnosis and also for evaluation of infection spread. Plain radiographs are of no value in the initial stages of the disease: bone abnormalities become visible only after several weeks of evolution: 3 weeks to 3 months (6, 14, 15). Moreover, these abnormalities are apparent only on oblique views (9, 15). Joint space narrowing or irregularities of joint facets are the early radiological signs. Subsequent radiographs reveal subchondral erosions, joint space narrowing or widening (8, 9, 14, 15).

Bone scan abnormalities are visible earlier, on average one to two weeks before radiographic changes (8, 9). Furthermore, bone scintigraphy is a very sensitive investigation in detecting infective processes. According to Muffoletto *et al*, technetium 99m bone scintigraphy is 100% sensitive in detecting SAFJ, as early as 3 days after the onset of symptoms (15). In the series of Ergan *et al*, mean time to positivity of the radionuclide bone scan was one month (9). Technetium bone scan has no spatial resolution and is not specific. Some authors advocate a gallium bone scan to increase the specificity, and single proton emission computed tomography (SPECT) to more clearly show the involvement of the posterior vertebral arch (1, 4, 9, 15, 16, 18). SPECT images with a laterally-located hot spot, a vertical long axis and greater hyperactivity on the posterior projection are typical; in spondylodiscitis a horizontal long axis is seen (2, 3, 6, 8, 9, 14, 16). As in our case, a false negative bone scan does not exclude the diagnosis. Dauwe *et al* even reported a case with a negative gallium scintigraphy (4). Ergan *et al* saw one false negative technetium scan in a series of 6 cases; it had been performed 2 weeks after

onset (9). Pilleul and Garcia reported one aspecific and one false negative bone scintigram (19).

Computed tomography (CT) has been reported to allow early diagnosis, as well as determination of the exact localisation and extent of infection (4, 8, 14). In the first week, CT scan identifies the inflammatory changes in the facet joint and adjacent soft tissues. Later on (2 weeks after onset), erosions and joint space narrowing or widening become visible (8, 9, 14). Sensitivity and specificity of CT scan are high in establishing the diagnosis of SAFJ (9). Contrast enhanced CT scan improves the specificity by showing abscesses in contiguous soft tissues (9, 14). CT scan also allows percutaneous guided aspiration or drainage of the involved facet joint or paraspinal muscle abscess (14, 15).

Today, gadolinium-enhanced MRI appears to be the imaging modality of choice in diagnosing SAFJ, especially in its earliest stages (11, 14, 19). In Muffoletto *et al*'s literature review, 17 out of 19 cases (89%) demonstrated MRI changes, consistent with SAFJ, as early as days after onset (15). MRI ranks high in detecting and delineating the extent of soft tissue involvement, including abscess formation (6, 7, 8, 9, 10, 14, 15). MRI was more sensitive than computed tomography in detecting an epidural abscess in a case reported by Douvrin *et al* (8). Furthermore, MRI easily rules out other affections having the same clinical presentation, especially spondylodiscitis (14).

## Treatment

There are no firm statements about the ideal treatment of SAFJ (4). Swayne *et al* have suggested that SAFJ might often heal without treatment, by spontaneous decompression of the joint effusion in the adjacent soft tissues (22). Spread to the spinal canal may lead to an epidural abscess, and eventually to a neurological deficit. There is no consensus about the management of SAFJ with epidural and paraspinal abscesses without neurological complications. In many cases, they have been successfully treated with antibiotics only (3, 6, 7, 8, 14). However, such a good evolution cannot always be guaranteed, and even paraplegia may follow. Therefore, some authors recommend percutaneous drainage,



combined with antibiotics (15). In case of epidural abscess with neurological deficit, laminectomy and decompression of the epidural space are mandatory (1, 9, 14, 15).

The optimal antibiotic regimen is not yet established. Some authors suggest that regimens designed for spondylodiscitis are also effective in SAFJ (9, 15). Intravenous anti-staphylococcal antibiotics are initiated as soon as samples are obtained. Later on, the treatment is adapted to the isolated organism and its sensitivity. Intravenous therapy is most often continued for 2 to 3 weeks, after which oral treatment is started for 4 to 16 weeks (9, 15). Some authors have recommended bracing for 2 or 3 months (4, 12). On the whole, outcome is favourable. However, persistent low back pain has been reported (2, 6, 9, 12).

## REFERENCES

1. Baltz MS, Tate DE, Glaser JA. Lumbar facet joint infection associated with epidural and paraspinal abscess. *Clin Orthop* 1997 ; 339 : 109-112.
2. Bellen P, Maldague B, Zech F. Arthrite septique d'une articulation interapophysaire vertébrale postérieure. A propos d'un cas. *Rev Chir Orthop* 1987 ; 73 : 289-291.
3. Ben Hamouda M, Rajhi H, Golli M *et al.* Arthrite septique interapophysaire postérieure lombaire. *J Radiol* 1997 ; 78 : 373-376.
4. Dauwe DM, Van Oyen JJ, Samson IR *et al.* Septic arthritis of a lumbar facet joint and a sternoclavicular joint. *Spine* 1995 ; 11 : 1304-1306.
5. David-Chaussé J, Dehais J, Boyer M *et al.* Les infections articulaires chez l'adulte : atteintes périphériques et vertébrales à germes banaux et à bacilles tuberculeux. *Rev Rhum Mal Osteoartic* 1981 ; 48 : 69-76.
6. Derouet N, Haettich B, Temmar Z *et al.* Arthrite septique inter-apophysaire postérieure à l'étage lombaire. A propos d'un cas. *Ann Méd Interne* 2001 ; 152 : 279-282.
7. Doita M, Nishida K, Miyamoto H *et al.* Septic arthritis of bilateral lumbar facet joints : report of a case with MRI findings in the early stage. *Spine* 2003 ; 28 : 198-202.
8. Douvrin F, Callonnet F, Proust F *et al.* Arthrite septique interapophysaire lombaire. A propos de 3 cas. *J Neuro-radiol* 1996 ; 23 : 234-240.
9. Ergan M, Macro M, Benhamou CL *et al.* Septic arthritis of lumbar facet joints. A review of six cases. *Rev Rhum* 1997 ; 64 : 386-395.
10. Farrokh D. Isolated septic arthritis of the articular surface of the lumbar spine. The contribution of MRI. *J Belge Radiol* 1997 ; 80 : 289-291.
11. Fujiwara A, Tamai K, Yamato M *et al.* Septic arthritis of a lumbar facet joint : report of a case with early MRI findings. *J Spinal Disord* 1998 ; 11 : 452-453.
12. Halpin DS, Gibson RD. Septic arthritis of a lumbar facet joint. *J Bone Joint Surg* 1987 ; 69-B : 457-459.
13. Heenan SD, Britton J. Septic arthritis in a lumbar facet joint : a rare cause of an epidural abscess. *Neuroradiology* 1995 ; 37 : 462-464.
14. Marson F, Cognard C, Guillem P *et al.* Arthrite septique interapophysaire postérieure lombaire avec abcès épidual et des parties molles paravertébrales. *J Radiol* 2001 ; 82 : 63-66.
15. Muffoletto AJ, Ketonen LM, Mader JT *et al.* Hematogenous pyogenic facet joint infection. *Spine* 2001 ; 26 : 1570-1576.
16. Okazaki K, Sasaki K, Matsuda S *et al.* Pyogenic arthritis of a lumbar facet joint. *Am J Orthop* 2000 ; 29 : 222-224.
17. Orpen NM, Birch NC. Delayed presentation of septic arthritis of a lumbar facet joint after diagnostic facet injection. *J Spinal Disord Tech* 2003 ; 16 : 285-287.
18. Peris P, Brancos MA, Gratacos J *et al.* Septic arthritis of spinal apophyseal joint. Report of two cases and review of the literature. *Spine* 1992 ; 17 : 1514-1516.
19. Pilleul F, Garcia J. Septic arthritis of the spine facet joint : early positive diagnosis on MRI. Review of two cases. *Joint Bone Spine* 2000 ; 67 : 234-237.
20. Smida M, Ben Youssef M, Bouchoucha S *et al.* Abcès primitif des muscles spinaux chez l'enfant. *Rev Tunisienne Santé Militaire* 2002 ; 4 : 186-189.
21. Soscia MF, Trammell TR. Pyogenic lumbar facet joint arthritis with intradural extension : a case report. *J Spinal Disord Tech* 2002 ; 15 : 526-528.
22. Swayne LC, Dorsky S, Caruana V *et al.* Septic arthritis of a lumbar facet joint : detection with bone SPECT imaging. *J Nucl Med* 1989 ; 30 : 1408-1411.