



## MRI abnormalities of the ischiopubic synchondrosis in children : A case report

Dimitri CERONI, Maryline MOUSNY, Merak ANOOSHIRAVANI-DUMONT, Anne BUERGE-EDWARDS, André KAELIN

The authors report the case of a five and a half year-old-boy with symptomatic MRI abnormalities of the ischiopubic synchondrosis. The concept of "ischiopubic osteochondritis" is reviewed in the light of modern imaging, and the importance of its differentiation from different pathological entities such as osteomyelitis, tumour, fracture or other pathologic entities is recalled.

### INTRODUCTION

The ischiopubic synchondrosis is a cartilaginous junction between the inferior ischial and pubic rami. Its closure typically begins in early childhood and is completed before puberty, without any clinical symptom. However, some children may describe pain in the hip or the gluteal region and show decreased range of motion and limping. The synchondrosis may be seen on conventional radiographs as a tumour-like radiolucent area at the ischiopubic fusion zone. These radiographic changes were recognised long ago by Odelberg (1923) and Van Neck (1924) (6,7). Despite its typical appearance, the ischiopubic synchondrosis may suggest neoplasia, osteomyelitis or a stress fracture and the differential diagnosis may be difficult. MRI findings in ischiopubic synchondrosis are nonspecific and may be misleading (4). We would like to use the opportunity of this case report to review the problem of the ischiopubic synchondrosis imaging and its clinical significance.

### CASE REPORT

A five and a half year-old-boy was admitted to our hospital because of pain involving the gluteal region, and marked limping. The onset of the symptoms was four days before admission, with no history of trauma. He had been receiving antibiotics for two days because of an acute otitis media. The patient was referred to our institution by his general practitioner with the differential diagnosis of osteomyelitis or tumour of the ischial ramus on the basis of an MRI study. Physical examination revealed a subfebrile healthy boy (37.7°C rectal). The ischiopubic synchondrosis was tender on palpation but there was no local swelling. There was

---

*From the Children's Hospital, Geneva, Switzerland*

Dimitri Ceroni, MD, Orthopaedic Surgeon

Maryline Mousny, MD, Orthopaedic Surgeon

André J. Kaelin, MD, Professor of Orthopaedic Surgery

*Division of Paediatric Orthopaedics and Traumatology, Children's Hospital (Hôpital des Enfants), 6, rue Willy Donzé, 1205 Geneva, Switzerland*

Merak Anooshiravani-Dumont, MD, Paediatric Radiologist

*Department of Radiology, Children's Hospital (Hôpital des Enfants), 6, rue Willy Donzé, 1205 Geneva, Switzerland*

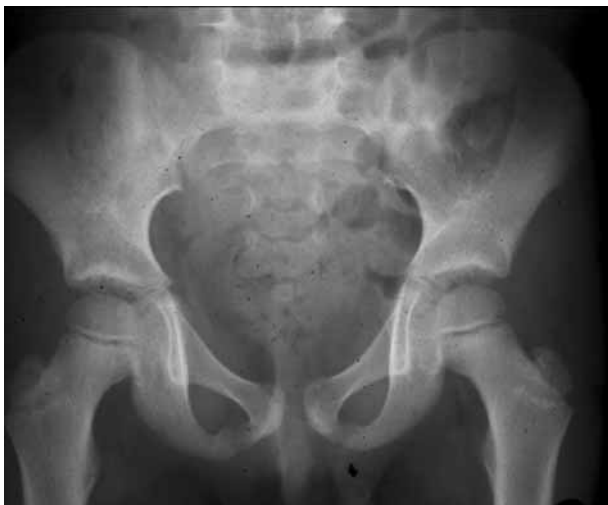Edward A. Buerge, MD, Paediatrician

*Paediatric Clinic, Children's Hospital (Hôpital des Enfants), 6, rue Willy Donzé, 1205 Geneva, Switzerland*

Correspondence : Dimitri Ceroni, Unité d'Orthopédie et de Traumatologie Pédiatrique, Hôpital des Enfants, Hôpitaux Universitaires de Genève, 6 rue Willy Donzé, 1205, Genève, Switzerland.

E-mail : dimitri.ceroni@hcuge.ch

© 2004, Acta Orthopædica Belgica.



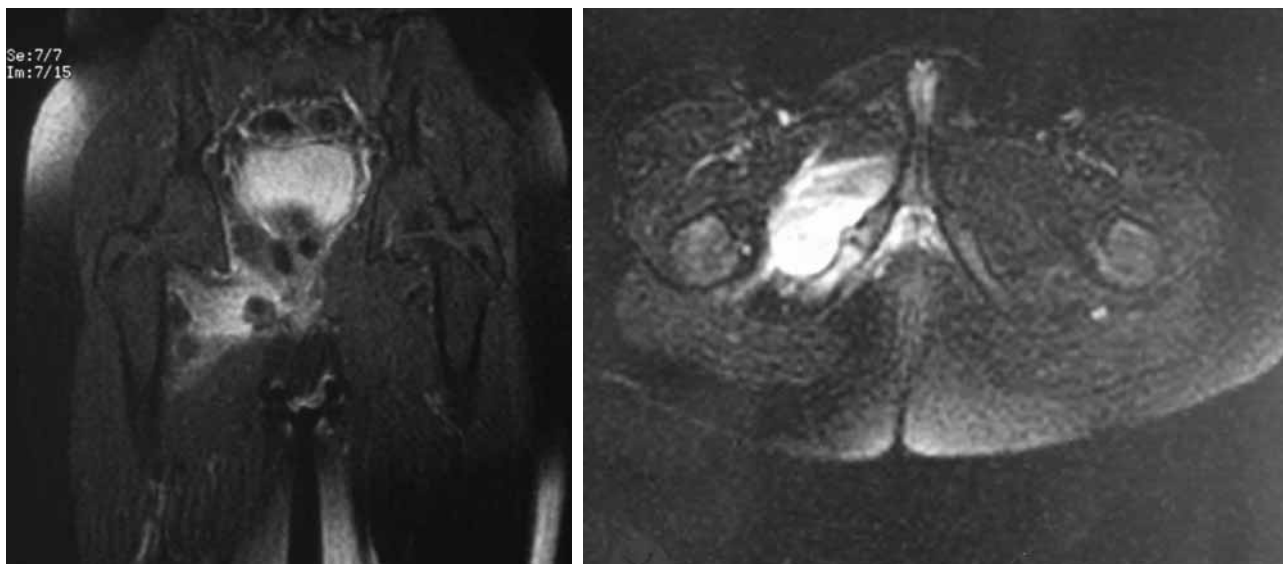
**Fig. 1.** — Plain film (AP view) of the pelvis shows a normal appearance of both ischiopubic synchondroses, with bilateral well-defined radiolucent swelling aspect, slightly more important on the right side.

moderate contracture of the adductor muscles and a limited passive range of motion of the right hip. C reactive Protein (CRP) value was 41 mg, sedimentation rate (ESR) 55 mm/h, and blood examination was normal. Anteroposterior radiographs of the pelvis showed on both sides a normal appearance

of the ischiopubic synchondrosis, with a well-defined radiolucent swelling aspect, slightly more important on the right side (fig 1). On the initial MRI (GE SIGMA 1.0T), STIR and T2 FAT SAT images (fig 2a) revealed an hyperintense signal alteration of the bone marrow of the right ischiopubic ramus as well as of the adjacent muscles. On T1-weighted images these areas were hypointense but enhanced strongly after Gadolinium infusion. The signal alteration of the right ischiopubic synchondrosis was centered by a band-like hypointense area (fig 2b). The patient was treated by bed rest and anti-inflammatory medication. Antibiotics were discontinued. Within 48 hours, we noted complete resolution of the complaints and the clinical examination was normal. Two months later, a second MRI (MARCONI PROVIEW 0.23T) was performed. STIR and particularly T2-weighted images showed decreased hyperintensity of the muscles and of the ischiopubic bone marrow (fig 3a,b).

## DISCUSSION

Odelberg first described swelling and uneven mineralisation in the ischiopubic synchondrosis on



**Fig. 2.** — MRI performed three days after the onset of symptoms.

- a) Coronal STIR sequence showing hyperintense signal alteration of muscles adjacent to the ischiopubic ramus (obturator muscles, quadratus femoris muscle and the proximal adductor magnus).
- b) Axial T2 FAT SAT sequence showing hyperintense signal alteration of the right ischiopubic bone marrow centered by a hypointense band.

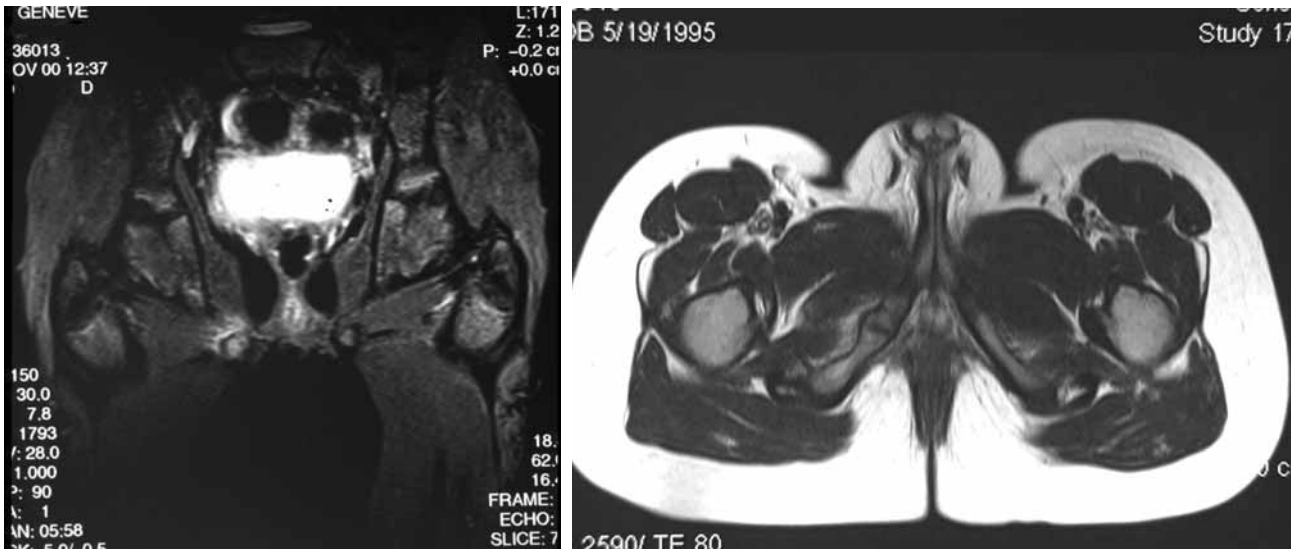


Fig. 3. — Follow-up MRI performed two months later.

- a) Coronal STIR sequence shows diminished hyperintensity of soft tissues surrounding the right ischiopubic synchondrosis.  
 b) Axial T2 sequence shows a decrease in muscle hyperintensity and no residual signal alteration of the bone marrow surrounding the hypointense linear band of the ischiopubic ramus.

radiographs in 1923 (6). One year later, Van Neck described similar radiographic changes in symptomatic young girls and proposed the term “osteochondritis of the pubis” for this entity (7). Nowadays, it is well-known that the asymptomatic ischiopubic osteochondrosis is part of the normal fusion process. But when clinical symptoms are associated with these radiographic changes, must they be regarded as part of the normal growth process or as pathological? Bernard *et al* (1) agree with the term “osteochondrosis” when clinical symptoms are associated with radiographic abnormalities and compare this entity with other osteochondroses such as Osgood-Schlatter’s disease or Sinding-Larsen-Johansson’s disease. Several authors (2,3) do not regard ischiopubic osteochondritis as a specific disease but suppose that the radiographic changes described are transitory stages in the normal fusion of the synchondrosis. Caffey and Ross found that more than 50% of asymptomatic children may present swelling and demineralisation of the ischiopubic synchondrosis (3). Neitzschman (5) considers this entity as part of the normal fusion process even though there is associated pain. MRI was thought to be helpful in the differentiation of ischiopubic synchondrosis from

other pathologic conditions because of its excellent tissue characterisation. However, most MRI findings in ischiopubic synchondrosis are non-specific and may add to the confusion concerning this physiological condition (4). According to Herneth *et al*, typical MRI features of ischiopubic osteochondrosis involve signal alteration and contrast enhancement of the bone marrow, which is hyperintense on T2-weighted and STIR sequences and hypointense on T1-weighted sequences. Irregular swelling of the adjacent soft tissue is typically present and appears hyperintense on T2-weighted and STIR sequences. But only the fibrous “bridging” described by the same authors seems to be a characteristic MRI feature of the ischiopubic synchondrosis (4). In our case report, the significant extension of the hyperintense signal abnormalities involving the bone marrow and especially the adjacent muscles seems to be unusual. As described by Herneth *et al*, we also observed a band-like area in the center of the ischiopubic synchondrosis which was hypointense on all sequences, consistent with a fibrous bridging (4). This finding, as well as the well-defined margins of the ischiopubic bone on MRI, are reassuring to rule out a neoplastic lesion. The other MRI findings, however, are non specific.

## CONCLUSION

Ischiopubic “osteochondrosis” is a well-known finding on conventional radiographs of both symptomatic and asymptomatic children. In this case report, the authors recall that the “atypical” radiologic appearance of the ischiopubic synchondrosis in children may be confused with pathology, especially if it is discovered unilaterally. MRI findings are strongly suggestive of oedema of the bone and adjacent soft tissue that may also be present in inflammation, tumour or trauma. Since MRI findings also seem to be non specific, their interpretation warrants great care and a good knowledge of the physiological nature of ischiopubic synchondrosis.

## REFERENCES

1. **Bernard C, Sirinelli D, Timores A, Fauré C.** Rubrique iconographique (cas radiologique du mois). *Arch Fr Pédiatr* 1986 ; 43 : 505-506.
2. **Byers PD.** Ischio-pubic “osteochondritis”. A report of a case and a review. *J Bone Joint Surg* 1963 ; 45-B : 694-702.
3. **Caffey J, Ross SE.** The ischiopubic synchondrosis in healthy children : some normal roentgenologic findings. *Amer Roentgen* 1956 ; 76 : 488-494.
4. **Herneth AM, Trattnig S, Bader TR et al.** MR imaging of the ischiopubic synchondrosis. *Magnetic Resonance Imaging* 2000 ; 18 : 519-524.
5. **Neitzschman HR.** Hip trauma. *J La State Med Soc* 1997 ; 149 : 186-188.
6. **Odelberg A.** Some cases of destruction in the ischium of doubtful etiology. *Acta Chir Scand* 1923 ; 56 : 273-284.
7. **Van Neck M.** Ostéochondrite du pubis. *Arch Franco-Belges Chir* 1924 ; 27 : 238-241.