



The role of Bone Morphogenetic Protein-7 (Osteogenic Protein-1®) in the treatment of tibial fracture non-unions An overview of the use in Belgium

Stefan DESMYTER, Yannick GOUBAU, Nadia BENAHMED, Alain DE WEVER, René VERDONK

From the University Hospital of Gent, Belgium

The evolution of a fracture non-union is complex ; treatment strategies are therefore challenging. The use of BMP-7 could be an interesting adjunct. We present an overview of the monitored use of this product in tibial non-unions in Belgium. Our retrospective data covers 53% (62 patients) of the cases in which it was used between 2001 and 2006.

Questionnaires were sent to surgeons who had been using BMP-7 (OP-1) in tibial non-unions in Belgium. Of 55 surgeons contacted, 27 who had been treating 62 patients with a non-union of a tibial fracture responded. These fractures were most commonly treated with an external fixator and 50% of them had already received some form of graft material. Non-union was diagnosed after a median of 365 days (range, 123-1212).

Treatment with OP-1 resulted in a clinical healing rate of 79.6% and a radiographic healing rate of 84.9%. Union was reported after a median of 230 (32-872) days clinically and 232 (32-739) days radiographically.

We documented a large number of cases of use of BMP-7 in tibial non-union in Belgium. The healing rates of around 80% are comparable to other reports on success rates with BMP-7. Many cases presented originally with open fractures, infected wounds or fractures with bone loss. This makes the reported results even more promising. Further studies are needed to analyse the socio-economical value of this relatively expensive treatment.

Keywords : non-union, tibia ; bone morphogenetic proteins ; BMP-7 ; OP-1®.

INTRODUCTION

Typically, around 10% of fractures of the tibia evolve into non-union (14). Fracture non-union occurs when the reparative sequence of fracture healing is interrupted (5). These cases could benefit from a factor that stimulates bone growth. The current gold standard for stimulating bone regeneration is reoperation with autogenous bone grafts, taken from the iliac crest, with or without replacement of the fracture fixation (17). The reported rates of successful treatment of the non-union range from 75 to 100% (1,4,8,6,11,16,18). However, harvesting of autografts has been related to a high level of morbidity.

■ Stefan Desmyter, MD, Orthopaedic Surgeon.

■ Yannick Goubau, Medicine Student.

■ René Verdonk, MD, PhD, Orthopaedic surgeon, Professor in orthopaedic surgery.

Department of Orthopaedic Surgery and Traumatology, University Hospital Ghent.

■ Nadia Benahmed.

■ Alain De Wever.

Ecole de Santé Publique - Département d'Economie de la Santé - Université Libre de Bruxelles.

Correspondence : Dr Stefan Desmyter, Vaderlandstraat 48, B-9000 Gent, Belgium.

E-mail : stefandesmyter@yahoo.com

© 2008, Acta Orthopædica Belgica.

One meta-analysis covering 1,020 patients treated with an autograft describes a general complication rate of 31% after graft harvesting from the iliac crest. Donor site pain was present after two years in 27% of the patients. This pain was described as intense in 11% of the cases (9).

Like most biological processes, fracture healing is regulated by a complex interaction of cells, mediators and tissue. 'Bone morphogenetic protein' (BMP) is a human growth factor and has several subtypes (2). It induces bone formation and probably has several unidentified functions in normal bone biology and growth. This was shown in preclinical and animal studies (3,12). The study by Friedlander *et al* confirmed that the use of recombinant BMP-7 alone in the treatment of non-union is safe, with results comparable to the use of an autograft (6). This study however was not blinded and did not consider large bone defects. BMP-7 is registered for the use in all non-unions after 9 months, especially in cases where previous autogenous bone graft has failed. In practice it is used in a much wider range of applications. The current tendency is to use it in cases of extreme bone loss, tissue loss, infection or vascular compromise. It remains unclear if the product is suitable for these purposes. According to the literature, the major advantage is avoidance of autograft use and the associated short and long term complications (9). There are indications that a faster and higher rate of healing occurs after the use of BMP-7. The high cost of this protein is one of the disadvantages. Theoretically the high costs could be counterbalanced by faster recovery rates, reduction of work impairment and lower total hospitalisation costs.

Compared to normal fracture healing, both medical and social costs are increased in fracture non-union. There is substantial social damage and reduction of quality of life due to loss of function, reduced mobility and pain (5). Reoperation rates are high and medical follow-up is typically long and intensive (10). Research on the pharmaco-economic implications of BMP-7 has not yet been conducted. In this paper we present a retrospective overview of the use of BMP-7 in the treatment of tibial non-unions in Belgian hospitals.

PATIENTS AND METHODS

Questionnaires were sent by mail to all Belgian users of BMP-7, identified by the distributor Stryker Inc. The questionnaires were developed by the health economics department of the Université Libre de Bruxelles (Free University of Brussels) to monitor economic variables. We estimate that there were a total of 117 cases of use in the period from the introduction of the product on the market in 2001, until the conclusion of the mailing in January 2006. We received data on 62 cases. These patients were treated by 27 different surgeons (out of a total of 55 users identified).

We present an overview of the treatment outcomes from these questionnaires. Clinical outcome was not documented in 8 (12.9%) cases and radiographic outcome in 9 (14.5%) cases. These cases were not included in the outcome analysis.

The data were analysed with SPSS® 14.0 software (SPSS Inc.).

The average age at the time of index treatment was 43.1 years. Age distribution was comparable between males (42.5) and females (44.8). The formal diagnosis of non-union was made a median of 365 (123-1212) days after the original injury. This delay was not significantly different between open or closed original fractures. Of these non-unions, 74% had been open fractures. The patients had all undergone some form of treatment, with a median of 2 (0-9) surgical operations before the index treatment.

Forty patients (64.5%) were treated with only one fixation method. Overall, the most common fixation method was an external fixator, which was used in 40 patients (64.5%). Figure 1 presents an overview of the last fixation method used before the patients were treated with OP-1®. The type of fixation used in 6 patients could not be retrieved.

During prior treatments, graft materials were added to fixations in 31 cases (50%). Thirty patients (48.4%) were not previously treated with any graft material. In one patient the use of graft material was not documented. Multiple types of graft materials were used in 14 patients. Twenty-five patients were treated with autografts on one or more occasions. Eight patients were treated at least once with allografts. Some patients were treated with both autograft and allograft at some point. Hydroxyapatite was used in one patient. The different types of fixation and graft materials used in the index treatment, together with OP-1®, are presented in figures 2 and 3. A combination of OP-1® with other graft material was used in 69.4 % of cases. Autograft was used in about half of these.

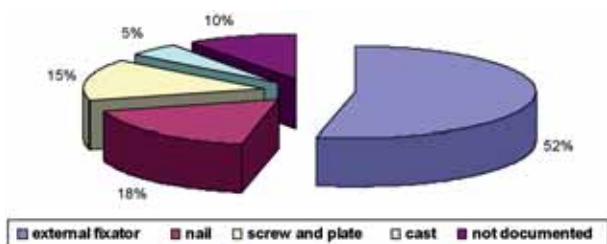


Fig. 1. — Last fixation methods before OP-1

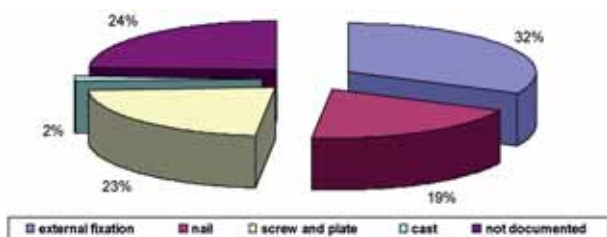


Fig. 2. — Fixations used together with OP-1

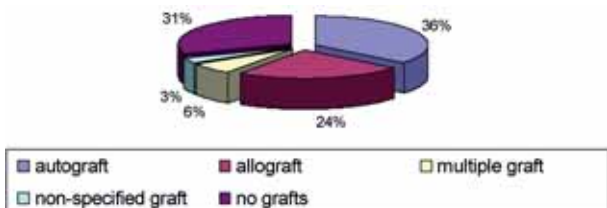


Fig. 3. — Grafts used together with OP-1 (number of operations : 62).

RESULTS

After treatment with OP-1®, clinical healing was observed in 43 cases (79.6%) after a median time of 232 (32-872) days. Forty-four patients (84.9%) showed radiographic healing, either total (consolidation) or partial (presence of a bony callus), after a median of 234 (32-739) days. In 24 cases, the surgeon answered the question about motivations for use of OP-1®. In 13 cases, the decisive factor for an OP-1® treatment was a previous graft failure. Presence of an infection was mentioned as a decisive element in 7 cases. In 4 cases, both of the above were mentioned. No significant difference in healing was observed for patients treated with OP-1® along with one or more graft materials compared to patients treated with OP-1® alone. Sex ($p = 0.087$) or the number of operations ($p = 0.173$) before the

use of OP-1® had no influence on the healing. Nine patients underwent another operation after the treatment with OP-1® had failed. Only three of these eventually healed and another three of these cases ended up in amputation. Three patients had already received treatment with OP-1® without success, before the index treatment. In all these patients a successful clinical and radiographic outcome was observed after the second use of the product.

DISCUSSION

Literature on non-union in general is at best confusing. Treatment methods are hard to compare. Vague definitions make comparisons troublesome. There is limited consensus on the accepted duration after injury or previous treatment, before the diagnosis of non-union can be made. Definitions like "No progression of clinical or radiological healing during the previous three to four months" (1) are dependent on variables such as injury, fracture and patient characteristics. Differences in local and systemic factors are of greater influence on the healing time than differences in treatment techniques. These factors are not always monitored. Definitions of healing, mainly radiological healing, are more transparent, but often differ between studies (4,6,8).

Our data have some of the same shortcomings as found in literature, but they have the advantage of being collected from a heterogenous group of practices and hospitals, which makes the overview more representative than a typical selected series from centres of excellence only.

Healing rates of 80% (clinical) and 85% (radiological) appear consistent with results in the literature (1,4,8,6,11,16,18). However, two remarks must be made. Firstly, a weakness of this study is its retrospective nature and the data collecting by means of questionnaires. Not all centres that use the product were willing to return the questionnaires. The clinical and radiological methods of observation of healing were left to the discretion of the corresponding surgeons. A specific problem was lack of documentation of prior treatment and the chronology of events. This is typical for the reporting on non-union, where the evolution extends over long periods of time and often induces medical shopping.

Secondly, the strength of the study is the relatively high proportion (53%) of all cases of use ever performed in Belgium, until the end of the data retrieval. We hypothesize that there was a negative selection bias in the indications for use : these cases do not represent a mean of tibia fractures or even non-unions, and they include a high number of open fractures, infections and bone loss. These factors could have negatively influenced the results.

One could speculate that the cost of the product and the administrative load of refunding, force the surgeon to reserve its use for difficult cases. Moreover surgeons appear to tend to use BMP-7 as a last resort : 6 out of the 9 cases that subsequently underwent further surgery, ended up with a poor result again. We might also point out that, although the presence of an infection is an exclusion criterion for the use of OP-1®, many surgeons specifically mentioned infection as a reason to use the product. This is an interesting finding, and it seems to be confirmed by recent reports. Recent concerns about a local sensitisation were not confirmed, since all three cases where OP-1 was used for the second time, went on to uneventful healing.

CONCLUSION

The figures reported represent a valuable and realistic overview of the current use of BMP-7 for tibial non-unions in Belgium. The product is being used in the most difficult cases, but seems to produce results comparable to non-union treatment in general. A prospective study is needed to provide more solid data about the use of BMP-7 in tibial non-unions. This study should preferably be randomised, in order to overcome the selection bias. An economic evaluation could answer the question whether the use of the product in primary cases would reimburse itself through reduction in medical costs and socio-economic burden.

REFERENCES

- Babhulkar S, Pande K, Babhulkar S.** Nonunion of the diaphysis of long bones. *Clin Orthop* 2005 ; 431 : 50-56.
- Chen D, Zhao M, Mundy G.** Bone morphogenetic proteins. *Growth Factors* 2004 ; 22 : 233-241.
- Cook SD, Barrack RL, Santman M, Patron LP, Salkeld SL, Whitecloud TS 3rd.** Strut allograft healing to the femur with recombinant human osteogenic protein-1. *Clin Orthop* 2000 ; 381 : 47-57.
- Dimitriou R, Dahabreh Z, Katsoulis E, Matthews SJ, Branfoot T, Giannoudis PV.** Application of recombinant BMP-7 on persistent upper and lower limb non-unions. *Injury* 2005 ; 36 Suppl 4 : S51-59.
- Einhorn TA.** Enhancement of fracture healing. *Instr Course Lect* 1996 ; 45 401-416.
- Friedlaender GE, Perry CR, Cole JD et al.** Osteogenic protein-1 (bone morphogenetic protein-7) in the treatment of tibial nonunions. *J Bone Joint Surg* 2001 ; 83-A Suppl 1(Pt 2) S151-158.
- Geesink R, Hoefnagels N, Bulstra S.** Osteogenic activity of OP-1® bone morphogenetic protein (BMP-7) in a human fibular defect. *J Bone Joint Surg* 1999 ; 81-B : 710-718.
- Giannoudis P, Tzioupis C.** Clinical applications of BMP-7 : the UK perspective. *Injury* 2005 ; 36 Suppl 3 : S47-50.
- Gupta A, Shah N, Patel T, Grauer J.** Perioperative and long-term complications of iliac crest bone graft harvesting for spinal surgery : A quantitative review of the literature. *Int Med J* 2001 ; 8 : 163-166.
- Harris I, Lyons M.** Reoperation rate in diaphyseal tibia fractures. *ANZ J Surg* 2005 ; 75 : 1041-1044.
- Jones AL, Bucholz RW, Bosse MJ et al. BMP-2 Evaluation in Surgery for Tibial Trauma-Allgraft (BESTT-ALL) Study Group.** Recombinant human BMP-2 and allograft compared with autogenous bone graft for reconstruction of diaphyseal tibial fractures with cortical defects. A randomized, controlled trial. *J Bone Joint Surg* 2006 ; 88-A : 1431-1441.
- Magin M, Delling G.** Improved lumbar vertebral interbody fusion using rhOP-1® : a comparison of autogenous bone graft, bovine hydroxylapatite (Bio-Oss), and BMP-7 (rhOP-1®) in sheep. *Spine* 2001 ; 26 : 469-478.
- Megas P.** Classification of non-union. *Injury* 2005 ; 36 Suppl 4 : S30-37.
- Praemer A, Furner S, Rice D (eds).** *Musculoskeletal conditions in the United States*. AAOS, 1992.
- Urist M.** Bone : formation by autoinduction. *Science* 1965 ; 150 : 893-899.
- Verbruggen J, Stapert J.** Failure of reamed nailing in humeral non-union ; an analysis of 26 patients. *Injury* 2005 ; 36 : 430-438.
- Westerhuis R, van Bezooijen R, Kloen P.** Use of bone morphogenetic proteins in traumatology. *Injury* 2005 ; 36 : 1405-1412.
- Wu C, Chen W.** A revised protocol for more clearly classifying a nonunion. *J Orthop Surg (Hong Kong)* 2000 ; 8 : 45-52.