

Meyer's dysplasia : delayed ossification of the femoral head as a differential diagnosis in Perthes' disease

Nasir MUZAFFAR, Hae-Ryong SONG, Kamlesh DEVMURARI, Hitesh MODI

From the Korea University Medical Center, Seoul, South Korea

Meyer's dysplasia strongly mimics Legg-Calve-Perthes' disease despite differing markedly in eventual outcome. This study presents the clinicoradiological features which differentiate it from Perthes' disease in a group of 178 children with a preliminary diagnosis of Perthes' disease, of whom nine were subsequently diagnosed with Meyer's dysplasia. All had a near normal development of the femoral head ; mild flattening was seen in two cases. Clinical initial presentation often resembles Perthes' disease. However, the presence of a granular aspect of the femoral head, often bilateral, in a male child with a preliminary diagnosis of Perthes' disease should alert the clinician to the possibility of Meyer's dysplasia. Restitution of normal capital architecture is usual ; there may however be a mild residual hypoplasia.

Keywords : Meyer's dysplasia ; delayed ossification ; Perthes' disease ; bilateral ; granular pattern.

INTRODUCTION

Meyer's dysplasia, also called dysplasia epiphysealis capitis femoris (DECF), is a rare condition that affects the capital femoral epiphysis in young children. This developmental disorder of the hip is characterized by delayed, irregular ossification of the femoral epiphyseal nucleus (5). Onset usually occurs in the second year of life, is mostly bilateral and the disorder usually disappears by the end of

the sixth year (4). Previous studies indicate that boys are affected five times more than girls (3). Patients show continuous improvement, with steady unification and growth of the epiphysis, usually over a three-year period (4). Radiographic features include smaller ossification nuclei, cracks in the ossification center, cyst formation and radiolucent defects in the femoral head (6). Bone scans are normal in patients with Meyer's dysplasia (2). Epiphyseal dysplasia and hypothyroidism should be included in the differential diagnosis whenever bilateral changes are present (7). Meyer's dysplasia may be easily confused with more serious conditions such as Perthes' disease.

-
- Nasir Muzaffar, MS, Orthopaedic surgeon
Department of Paediatric Orthopaedics, Bone and Joint Surgery Hospital, Barzalla, Srinagar, J&K, India.
 - Hae-Ryong Song, MD, PhD, Orthopaedic surgeon,
Professor of Orthopaedic Surgery
 - Kamlesh Devmurari, MS, Orthopaedic surgeon
 - Hitesh Modi, MS, PhD, Orthopaedic surgeon
Department of Orthopaedic Surgery Korea University Medical Center, Guro Hospital, Seoul, South Korea.
- Correspondence : Dr Nasir Muzaffar, MS, Bone and Joint Surgery Hospital, Barzalla, Srinagar, Kashmir, India 190005
E-mail : drnasirmuzaffar@gmail.com
© 2010, Acta Orthopædica Belgica.
-

This study was undertaken to assess and evaluate the presence of Meyer's dysplasia in a population of Legg-Calve-Perthes' Disease (LCPD) patients, determine the incidence, sex and age groups of prevalence and differential diagnosis. The clinico-radiological features, when coupled with adequate knowledge of this condition, can prevent unnecessary hospitalization and treatment. We also present a brief study of the relevant literature and its correlation with our findings.

MATERIALS AND METHODS

In the paediatric orthopaedic outpatient department, between 2003 and 2008, 9 children with delayed ossification of the head of the femur were diagnosed with DECF, out of a total of 178 children with a preliminary diagnosis of LCPD. The average presenting age was 28.7 months (range 23-36 months). The average follow-up was 3 years 5 months. The diagnosis of DECF was made on the basis of the radiological pattern and evolution of the capital femoral epiphysis over a period of time, which differed from the rest of the children in the group of LCPD patients. This was generally in the form of delayed, smaller and irregular ossification centers of the capital femoral epiphyseal nucleus at about 2 years of age that gradually coalesced and normalized within 2-4 years. No signs of epiphyseal dysplasia were observed in any other area in all cases. MRI was done in 4 cases. No bone scans were done. The haematological tests did not reveal any abnormality. Bone age estimated by the Greulich-Pyle method was less than the chronological age in all patients. Since the preliminary diagnosis was LCPD, abduction bracing was given in 6 children presenting a limp and traction in one patient who had hip pain. These patients were asymptomatic within 2-4 weeks. There was no family history of LCPD in any case.

RESULTS

Out of 178 patients with LCPD, 9 patients or 5% were diagnosed with DECF. Four children had bilateral (44%) and five unilateral (56%) involvement. Eight of the children were male (88.9%).

Symptomatically, six children presented with a limp, one had mild hip pain, one had an abnormal standing position and one was discovered incidentally while being followed up for an amniotic band syndrome. Three cases had mild limited abduction and two had limited rotation of the hip. These symptoms resolved in all cases within 2-4 weeks. Plain radiological examination at presentation showed delayed and irregular ossification centers in all capital femoral epiphyses. Metaphyseal cysts were seen in two cases (figs 1, 2). Central column radiolucency was observed in two cases and sclerosis of the capital femoral epiphysis was seen in one case (fig 2). No limb length discrepancy was seen at eventual resolution (fig 3). Two cases had mild flattening of the femoral head at follow-up (fig 4). No hip showed any subluxation, subchondral fractures or any femoral neck deformity. Fusion of the ossification centers was seen at an average age of 5 years 10 months (range : 3.5-6.2 years). MRI showed metaphyseal cysts in one patient (fig 1), multiple ossification center involvement in another, fragmentation of the capital nucleus in the third and in the fourth case which was bilateral, a low signal intensity hypoplasia with flattening on the left side was observed (fig 4). No anomaly was observed in the marrow signal in any case. There was no effusion or synovial thickening on MRI in any of the affected hips. No medication was given. There was no conversion to LCPD in any case on follow-up.

DISCUSSION

Meyer's dysplasia or dysplasia epiphysealis capitis femoris (DECF) is a rare disorder often confused with Legg-Calve-Perthes' disease (LCPD). However, it differs from LCPD in both treatment and prognosis. The ossification nucleus is not seen until 18 to 36 months of age and occasionally multiple nuclei of ossification may be present, so that the epiphysis has a "granulated" aspect ; fusion of the various ossification centers occurs at around 5 years of age (3). The epiphyseal density and structure is maintained and it does not collapse. Differential diagnosis should mainly be made with LCPD (2-5) but multiple epiphyseal dysplasia, hypothyroidism (7), dyschondroplasia, arthritis and

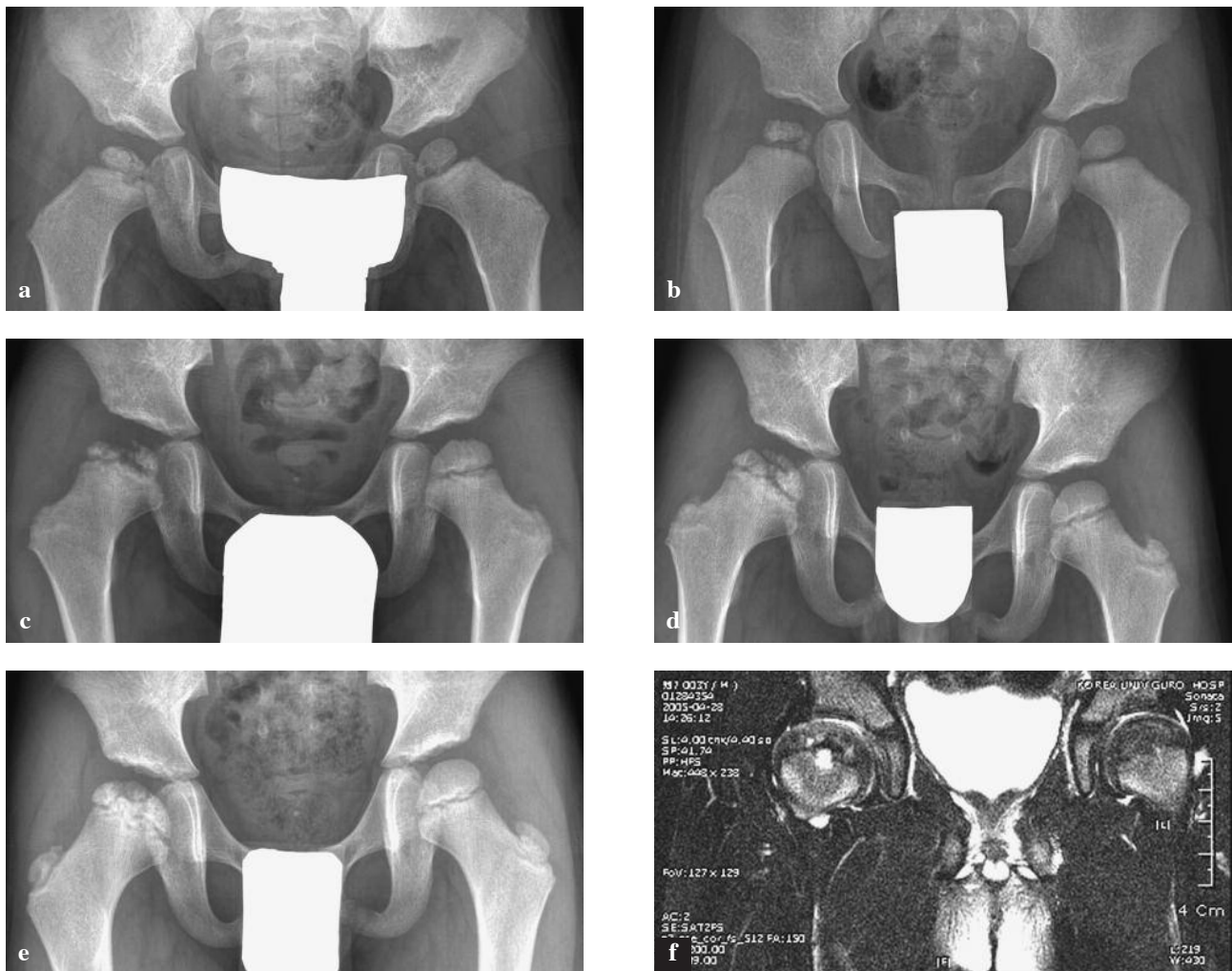


Fig. 1 — Serial radiographs of a child with DECF of the right hip showing an initial granular head pattern (a,b,c) and restoration to normal architecture (d,e). The MRI done initially is showing a metaphyseal cyst (f).

infection must be ruled out in doubtful cases. The notion that dysplasia epiphysealis capitis femoris is a separate entity distinct from LCPD was first put forward by Pedersen (5) in a study in 1960, wherein he described 42 patients in a group of 672 cases (6.2%) labeled as LCPD, having atypical pattern of radiographs showing no collapse or gross fragmentation of the capital femoral epiphysis. Meyer (4), in 1964, reported his findings of 30 cases in a group of 300, labeled as LCPD showing delayed development of the epiphyseal nucleus. These 30 cases (10%) showed ossification only after 2 years of age and the nucleus appeared as a diffuse granular structure with inconspicuous condensation, unlike

in LCPD where, according to Meyer, the first radiological sign of the disease is massive uniform condensation of the bone tissue in the epiphysis which is otherwise normal in shape and size. The femoral head and neck structure eventually normalized in about 3 years. Meyer also reported a bilateral incidence of 42% in his series. Six cases shifted from DECF to LCPD over a period of time. Khermosh and Wientroub (3) reported 18 cases of DECF with 50% bilateral involvement and boys affected five times more often than girls. They described an essentially similar clinicoradiological picture but with slight flattening of the femoral epiphysis, which they attributed to focal hypoplasia. Our

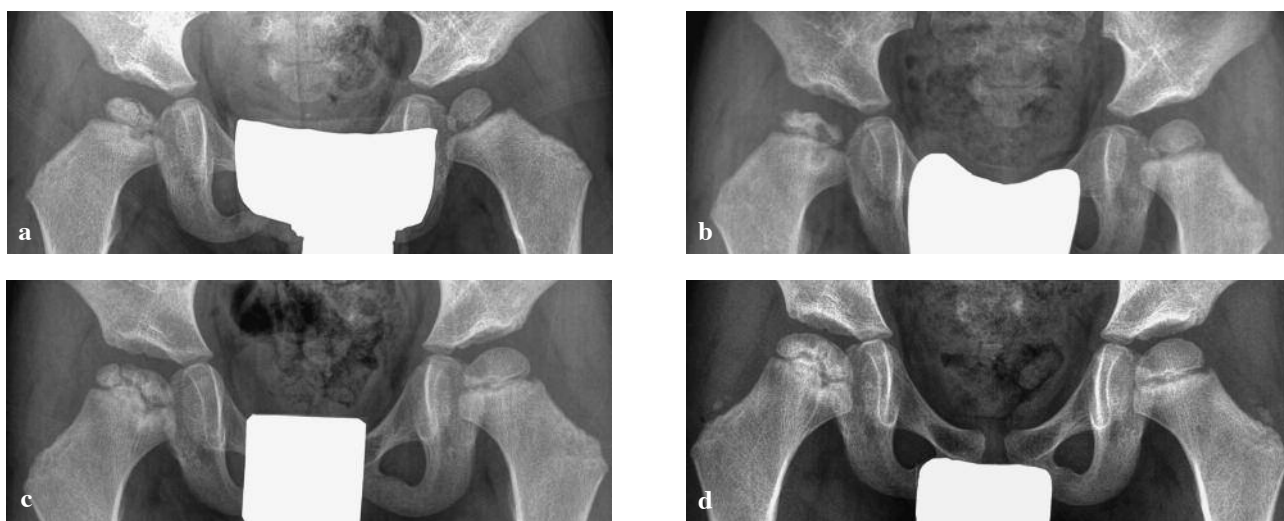


Fig. 2 — Serial radiographs of a child with DECF of the right hip showing metaphyseal cyst formation with sclerosis of the capital femoral epiphysis (a,b) and mild flattening of the restored femoral epiphysis (c,d).

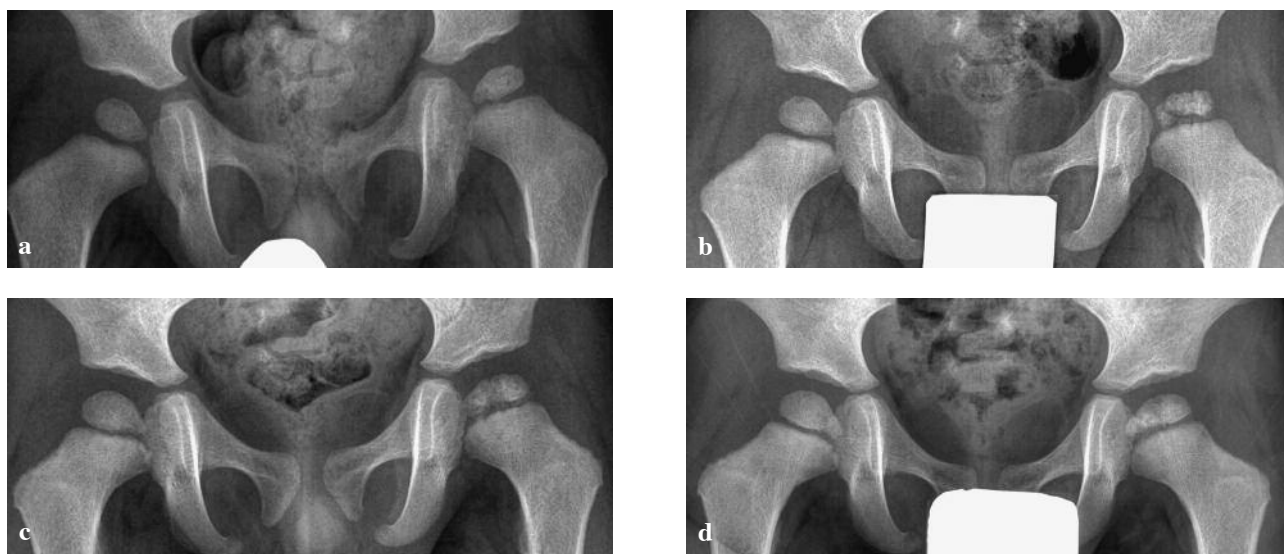


Fig. 3 — Serial radiographs of a child with DECF of the left hip with full remodelling in 1.5 years.

observations showed an incidence of 5% in a group of LCPD patients, bilateral incidence was seen in 44% of cases and 89% were male. The average age at presentation was 2.4 years. Similar figures were reported by Rowe *et al* (6); they reported a mean age at presentation of 2.5 years, an incidence of 4.4% among a group of LCPD patients and bilateral involvement in 59%. The chief presenting complaint was a limp in 6 cases (67%) which is why they were initially considered as LCPD patients.

Meyer (4) reported his patients of DCEF as having essentially a similar clinical presentation as LCPD and Harel *et al* (2) also indicated the symptoms of limp and restricted rotation as the presenting features. Our study tends to confirm these findings. Hip pain was seen in one case which has also been reported earlier (2). This led us to speculate that DECF might be a milder form or precursor of LCPD, that in a favorable environment does not deteriorate but shows resolution over time. The

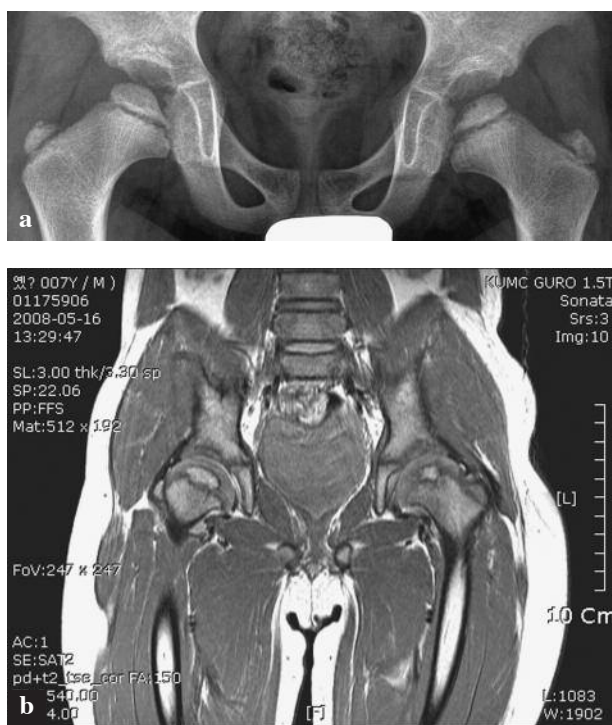


Fig. 4 — Radiograph and MRI of child with bilateral DECF. There is mild flattening of the left capital femoral epiphysis with radiolucency on the radiograph. The MRI shows low signal intensity hypoplasia with flattening of the left femoral head.

aetiology of DECF has puzzled many researchers over the years and though there are proponents of the ischaemic theory proposed by Meyer (4) and of the congenital vascular theory proposed by Batory (1), conclusive evidence for both is lacking. Our study included four MRI studies showing in one a metaphyseal cyst and in another a low signal intensity hypoplasia in the femoral head, which eventually healed normally with mild flattening on follow-up. The presence of metaphyseal cysts is one of the “head at risk” signs in LCPD; the complete resolution of the disease process in these cases points to the fact that DECF has features which are both conform and contrary to LCPD. We believe that further investigations are necessary, more specifically into a possible hormonal cause in view of the preponderance of male cases. This was out of the scope of our study at the time and may be taken up as a prospective investigation in the future.

The basic radiological features in all our patients showed a similar pattern. The ossific

nucleus appeared nearly at 2 years of age and usually consisted of a single granular structure or multiple small ossification centers. With the passage of time, these centers increased in size and coalesced. The end result was a normal appearing capital femoral epiphysis with mild flattening seen in two cases. Radiographic studies were quite demonstrative, showing delayed ossification giving the impression that there are radiolucent lytic areas producing a granular pattern of the femoral head, resembling a classic golf ball or as Meyer put it, a blackberry.

With the current knowledge of Meyer’s dysplasia, the term dysplasia seems a misnomer as the underlying pathology is a lack in development of ossification of the femoral head. The strict meaning of dysplasia is a defective development of the hip joint resulting in deformation of the shape or organization of the hip joint. In Meyer’s dysplasia, delayed ossification of the head of the femur during growth of the child eventually leads to a secondary ossified nucleus which is essentially normal without any significant sequelae or deformities. However, our results have shown that there may be flattening of the femoral head in DECF and though this may not be the case in every patient, regular and prolonged follow-up is needed to assess the long term results on the head-acetabular relationship.

REFERENCES

1. **Batory I.** [Dysplasia epiphysealis capitis femoris of primary hypoplastic vessel-development of the proximal epiphysis of femur] (in German). *Z Orthop Ihre Grenzgeb* 1982 ; 120 : 177-190.
2. **Harel L, Kornreich L, Ashkenazi S et al.** Meyer dysplasia in the differential diagnosis of hip disease in young children. *Arch Pediatr Adolesc Med.* 1999 ; 153 : 915-945.
3. **Khermosh O, Wientroub S.** Dysplasia epiphysealis capitis femoris. *J Bone Joint Surg* 1991 ; 73-B : 621-625.
4. **Meyer J.** Dysplasia epiphysealis capitis femoris. A clinical-radiological syndrome and its relationship to Legg-Calve’-Perthes disease. *Acta Orthop Scand* 1964 ; 34 : 183-197.
5. **Pedersen EK.** Dysplasia epiphysealis capitis femoris. *J Bone Joint Surg* 1960 ; 42-B : 663.
6. **Rowe, SM, Chung, JY, Moon ES et al.** Dysplasia Epiphysealis Capitis Femoris. Meyer Dysplasia. *J Pediatr Orthop* 2005 ; 25 : 18-21.
7. **Spranger J.** The epiphyseal dysplasias. *Clin Orthop Related Res* 1976 ; 114 : 46-58.