



Osteochondral defect in femoral head : Trufit ® implantation under fluoroscopic and arthroscopic control

Bart VUNDELINCKX, Kris DE MULDER, Jo DE SCHEPPER

From the Algemeen Ziekenhuis Nikolaas, Sint-Niklaas, Belgium

Under arthroscopic control and guided by fluoroscopy, a Trufit ® Plug was successfully implanted to repair an osteochondral lesion of the head of the femur. The procedure was evaluated clinically using the HOOS score and Magnetic Resonance Imaging (MRI) of the hip. The short-term (6 months) clinical results are encouraging : the HOOS score improved clearly and the patient was satisfied. Interpretation of MRI images in the early post-operative period is very difficult : in the early months history and clinical examination prevail in the evaluation.

Keywords : hip arthroscopy ; Trufit ; osteochondral lesion.

INTRODUCTION

Microfracturing, autologous chondrocyte implantation, mosaicplasty by means of autologous or allograft osteochondral plugs and synthetic osteochondral substitute grafts are the techniques used to repair chondral and osteochondral articular lesions. Trufit ® Plug (Smith & Nephew, San Antonio, TX), a synthetic resorbable biphasic implant, is one of the available matrix scaffolds. It is a bioabsorbable matrix made predominantly from polylactide-coglycolide copolymer, calcium sulfate, and polyglycolide, that immediately fills an osteochondral defect and supports the local migration of native chondrogenic or osteogenic cells that ultimately synthesize new ground substance and repair

the chondral defect. It is approved in Europe for the treatment of acute focal articular cartilage or osteochondral defects and by the Food and Drug Administration in the US for backfill of osteochondral autograft sites (3).

This device is mainly used in articular lesions of the knee. We present a technique to arthroscopically implant it in a retrograde fashion in a femoral head under control of fluoroscopy.

ILLUSTRATIVE CASE

A 34-year old employee doing mainly office work presented with a history of pain at the right hip and groin since 8 months, mostly during efforts and recreational running. There was no history of trauma. On clinical examination, the right hip had a full range of motion. No crepitus was notable and there were no signs of instability.

Magnetic resonance imaging (MRI) of the hip showed a severe osteochondral lesion with a subchondral cyst on the femoral head (Fig. 1a & b).

- Bart Vundelinckx, MD, Resident in orthopaedic surgery, *Catholic University of Leuven.*
- Kris De Mulder, MD, Consultant Surgeon.
- Jo De Schepper, MD, Consultant Surgeon. *Orthopaedic Department, AZ Nikolaas, Sint-Niklaas, Belgium.*

Correspondence : Bart Vundelinckx, Berenbroekstraat 29, 3600 Genk. E-mail : bartvundelinckx@hotmail.com

© 2012, Acta Orthopædica Belgica.

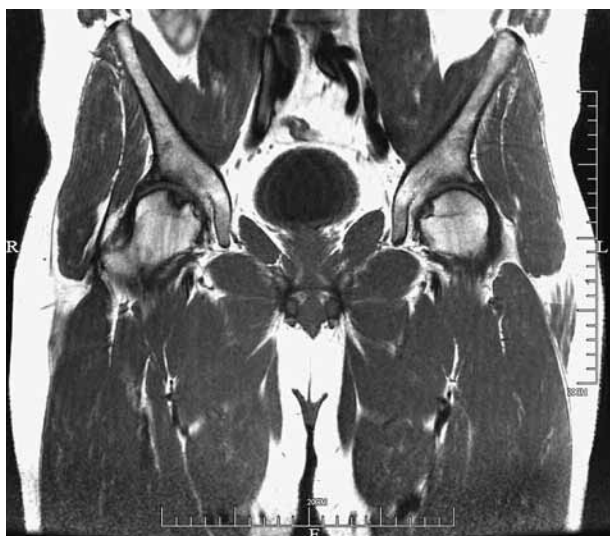


Fig. 1a. — Pre-operative MRI of the pelvis, coronal view. Osteochondral lesion of the right femoral head clearly visible as a defect on the articular side.

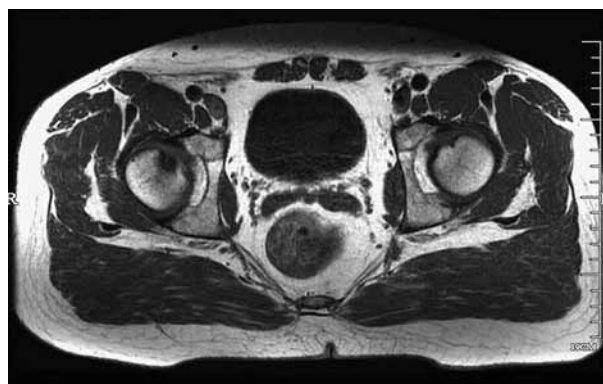

Fig. 1b. — Pre-operative MRI of the pelvis, axial view. Osteochondral lesion of the right femoral head clearly visible as a defect on the articular side.

Decision was made to perform a hip arthroscopy and treat the lesion by means of implantation of a Trufit® bioabsorbable osteochondral matrix plug.

OPERATIVE TECHNIQUE

The patient was installed on a traction table as for a classic hip arthroscopy procedure. The contralateral leg was abducted and fluoroscopy was installed above the affected hip. Classic anterolateral and mid-anterior portals were made for exploration of the articular compartment of the hip. After evaluation of the labrum and the articular cartilage of the femoral head and acetabulum, the osteochondral lesion was brought into sight. Hypertrophic synovitis was removed by shaving. A curved tip soft tissue shaver was used to remove loose flaps of the osteochondral lesion. A Kirchner guide wire was drilled under fluoroscopic and arthroscopic control starting at the lateral subtrochanteric area through the femoral neck into the osteochondral lesion. The tip of the shaver protected the acetabular cartilage surface against damage while advancing the wire through the lesion. A tunnel was drilled over the K-wire, using a 9 mm canulated drill. From within the tunnel, the border of the lesion and the subchondral cyst were debrided with a shaver. Then the

Trufit® Plug was inserted and advanced in a retrograde fashion until the cartilage side of the implant lied flush with the articular cartilage of the femoral head. No backfilling of the drilled canal was performed.

Post-operative rehabilitation consisted of restricted weight bearing during 4 weeks (walking with crutches and plantar touch), and progressive range of motion exercises. After 4 weeks, progressive loading, range of motion and tonification exercises were performed and normal activities were allowed after 3 months.

We evaluated the result of the intervention by clinical examination and MRI scan at 6 months. Functional evaluation was performed by means of the Hip Osteoarthritis Outcome Scores (HOOS) (1) with its subscales (on a maximum of 100 points) of Pain (P), Symptoms (S), Activity of Daily Life (ADL), Sports & Recreation (S&R) and Quality of Life (QOL). A score of 0 means no symptoms, a score of 100 means extreme symptoms. The score was obtained pre-operatively, at 6 months and at 1 year (Table I).

At 6 months, the right hip showed an abduction of 35°, a symmetric endorotation and exorotation of 30° and an adduction of 10°. Flexion was 95°, compared to 110° at the contralateral side.

MRI scanning at 6 months showed the Trufit plug *in situ*, without subsidence. But there still is an irregularity on the border of the articular cartilage surface. The big void of the original subchondral

Table I. — HOOS outcome scores pre-operatively, at 6 months and at 1 year (maximal scores)

Score (maximum)	Pre-operatively	At 6 months	At 1 year
Pain (100)	72.5	10	15
Symptoms (100)	60	15	0
Activity of Daily Life (100)	73.5	8.8	11.8
Sports & Recreation (100)	93.8	37.5	12.5
Quality of Life (100)	75	31.3	37.5
Total (500)	374.8	102.6	76.8

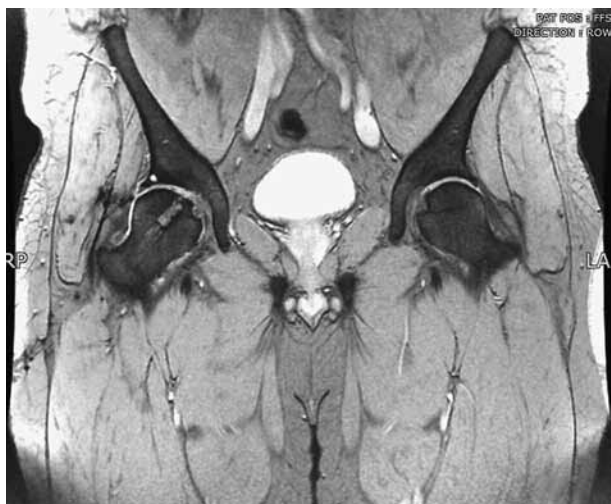

Fig. 2a. — Post-operative MRI at 6 months, coronal view. The Trufit ® Plug is visible *in situ*.

cyst was filled well by the plug. On the border however, a little spot of different intensity persisted (Fig. 2a & b). It is known to be very difficult to interpret those early MRI images of ingrowth of Trufit plugs (2).

DISCUSSION

Arthroscopic placement of a Trufit Plug in a femoral head is a procedure that was never described before, to the best of our knowledge. Technically, the most important and difficult step of the operative procedure is drilling the canal to reach the exact position of the lesion. The aiming arm of a conventional ACL guide was too short to be used in a hip joint. A specific adaptation of a guiding

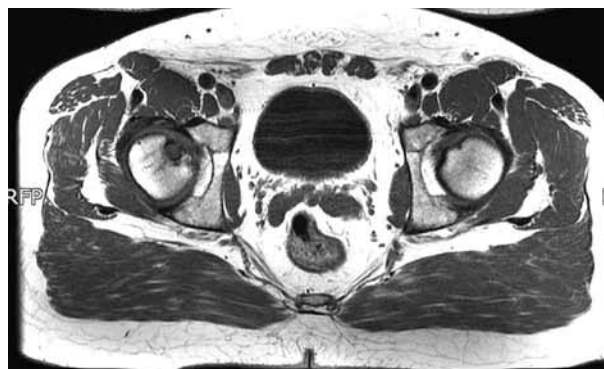


Fig. 2b. — Post-operative MRI at 6 months, axial view. The Trufit ® Plug is visible *in situ*.

instrument, as available in ACL reconstruction would be very helpful.

It is known to be very difficult to evaluate Trufit ® Plug incorporation by MRI during the first year, due to long lasting bone oedema around the plug. In the first year evaluation is mostly based on clinical data.

The short-term result in this single case is encouraging. We hope this procedure can delay degenerative changes in the joint, that probably would have been caused eventually by the severe osteochondral lesion.

In the future, we consider to backfill the rest of the drilled tunnel with autologous bone grafts. This was not done in this case, but we think it could improve rigid fixation and faster ingrowth of the Trufit ® Plug.

Longer follow-up and more cases of this rather rare condition will enable us to evaluate the results of this procedure on the long term.

REFERENCES

1. **Klässbo M, Larsson E, Mannevik E.** Hip disability and osteoarthritis outcome score. An extension of the Western Ontario and McMaster Universities Osteoarthritis Index. *Scand J Rheumatol* 2003 ; 32 : 46-51.
2. **Shindle MK, Foo LF, Kelly BT *et al.*** Magnetic resonance imaging of cartilage in the athlete : Current techniques and spectrum of disease. *J Bone Joint Surg* 2006 ; 88-A : 27-46.
3. **Williams RJ, Gamradt SC.** Articular cartilage repair using a resorbable matrix scaffold. *Instr Course Lect* 2008 ; 57 : 563-571.