



## Glenoid fractures : A review of pathology, classification, treatment and results

Dirk P.H. VAN OOSTVEEN, Olivier P.P. TEMMERMAN, Bart J. BURGER, Arthur VAN NOORT, Mike ROBINSON

*From Jeroen Bosch Ziekenhuis, Den Bosch, The Netherlands*

Glenoid fractures are rare, and relatively little is known about their mechanism, fracture pattern and optimal treatment strategies. The avulsions and rim fractures are strongly associated with anterior shoulder dislocations. Fossa fractures are mostly seen in high energy trauma patients as direct impact of the humeral head against the glenoid fossa. CT-scanning can be very useful in diagnosing the extend of injury and relation of humeral head with the main fragment of the glenoid. Fracture classification systems, have been designed mainly based on trauma mechanism, location and severity of fracture pattern. Treatment depends on instability, the degree of displacement and the articular surface fragment size, but is conservative in most cases. Due to the increase of arthroscopic fixation possibilities, operative treatment may increase. In this review, we have tried to summarize the available evidence into a treatment algorithm for different types of glenoid fractures. With regard to best functional outcome, an anatomical and concentric joint restoration should be the goal of treatment. Outcome is generally good in conservative and operative treatment, but exact data is difficult to appreciate, due to heterogeneity and comorbidities in different studies.

**Keywords :** Glenoid, scapula, fracture, classification, diagnosis, treatment, prognosis, algorithm

### INTRODUCTION

Fractures of the glenoid are uncommon (34,48) and publications regarding these fractures have

only been described in case series often as part of a scapular fracture series, and is therefore difficult to interpret (23,28,31,36,40). However, since the glenohumeral joint plays a key role in shoulder mobility, knowledge regarding diagnostic tests, treatment options and functional outcome are a prerequisite. Fracture patterns are diverse, and divided into avulsions, rim fractures and fossa fractures (6,12,18,28,31). Throughout literature various glenoid classification systems are described but lack a clear correlation with the fracture patterns found in clinical cases (3) or surgical decision making and functional outcome (31). Although most glenoid fractures do not require surgical intervention, understanding the

---

■ Dirk P.H. van Oostveen, MD, ing.

*Department of Orthopaedics, Jeroen Bosch Hospital, The Netherlands.*

■ Olivier P.P. Temmerman, MD, PhD.

■ Bart J. Burger, MD, PhD.

*Department of Orthopaedics, Medical Centre Alkmaar, The Netherlands.*

■ Arthur van Noort, MD, PhD.

*Department of Orthopaedics, Spaarne Hospital, Hoofddorp, The Netherlands.*

■ Mike Robinson, BMed Sci, FRCSEd (Orth).

*Department of Orthopaedics, Royal Infirmary of Edinburgh, Scotland.*

Correspondence : Dirk van Oostveen, Orthopaedic department, Jeroen Bosch Ziekenhuis, H. Dunantstraat 1, Den Bosch, The Netherlands.

E-mail : d.v.oostveen@jzbz.nl

© 2014, Acta Orthopædica Belgica.

---

common fracture patterns is of great importance to facilitate right surgical strategies for those fractures that do require surgery. Purpose of this review is to summarize relevant literature on the various types of glenoid fractures, including mechanisms of injury and preferred treatment options and reported results of conservative and operative treatment. The non-articular scapular fractures will not be addressed.

### EPIDEMIOLOGY

Fractures of the scapula comprise 0.4 -1 per cent of all fractures. Fractures of the glenoid make up around 10 percent of scapular fractures (5,12,48,49). Of all glenoid fractures, approximately 10 per cent are substantially displaced (12,15,18). Operative treatment therefore is a relatively rare procedure. Most common are the anterior avulsion and rim fractures, accounting for 75-85% of all glenoid fractures (18,40).

In studies on all types of scapular fractures, an average age of 35 years and a 4 : 1 male : female ratio has been reported. Although a similar age distribution is expected in the glenoid fracture group (25,40), there is a greater variety : the average age of patients with rim fractures is between 40-50 years (19,24,28,33,46), whereas the majority of fossa fractures occurs in young males (19).

Of all anterior dislocations, between 5-75% rim or avulsion fracture incidence is reported (11,16,19,20,41,44). This large variation in incidence might be caused by different definitions of rim and avulsion fractures, and influenced by different imaging techniques. On plain X-rays avulsions can easily be missed. Posterior glenoid rim fractures occur in 4-11% of patients with an acute posterior dislocation, with a higher incidence if caused by a seizure (11).

### ANATOMY

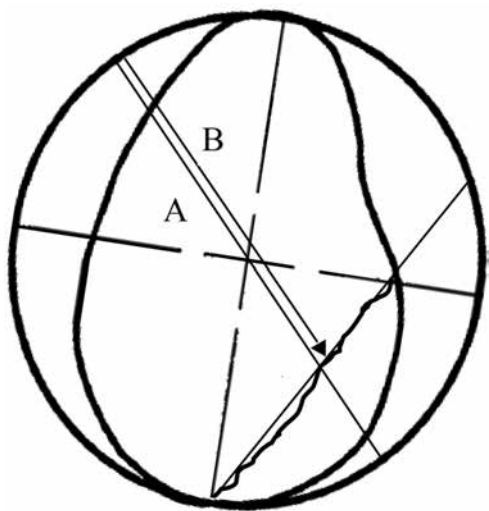
The glenoid is an oval shaped portion on the lateral border of the scapula that articulates with the circular rounded end of the humeral head. The glenoid surface is orientated in a near perpendicular orientation to the scapular blade (27,38). The inclination ranges from 1-5 degrees in vertical plane. The

scapula is oriented 30 degree anterior in the frontal plane. The superior portion of the glenoid is narrow and has a more anterior orientation compared to the inferior segment (38). The inferior part of the glenoid is a circle, with the bare spot as centre point (17). The vertical diameter of the glenoid fossa is longer (35 mm) than the horizontal diameter (25 mm) and the slightly concave surface is covered by hyaline cartilage, lined by the circular fibrocartilage labrum (38). Within the surrounding capsule, strong fibrous folds form ligaments, mainly on the anterior side. Superiorly the glenoid is part of the Superior Shoulder Suspensory Complex (SSSC), consisting of superior glenoid, coracoid process, coracoclavicular ligaments, distal end of the clavicle, acromioclavicular joint, coracoacromial ligament and acromial process (13,38). Subsequently, stability of the shoulder is a complex mechanism in which muscles, ligamentous and capsular restraints, the labrum and joint vacuum, each play a role depending on position and activity (38).

### MECHANISM OF INJURY AND FRACTURE PATTERNS

In describing trauma mechanisms of the glenoid distinction should be made between glenoid avulsions, rim fractures and fossa fractures.

The *avulsions and rim fractures* are strongly associated with anterior shoulder dislocations and typically seen following injury due to sports- or simple low energy trauma (6,28). In both cases, continuity with the ligament complex remains (28,48). Bony avulsions occur by indirect force, due to excessive traction of the capsulo-labral-ligament-complex during shoulder dislocation or are contributed to a forced abduction-external rotation movement (11). True inferior avulsion fractures are associated with contraction of the triceps during a forceful movement (49). The rim fracture in contrast, is a chisel-like fracture that can be as large as 1/3 of the articular surface and occurs as a result of direct impact of the humeral head into the glenoid rim (12,47,49). This fracture is often associated with sport accidents in younger patients (6,36) or due to traffic accidents in the older patients (28,36). Although Maquiera defines these fractures as rela-



**Fig. 1.** — Schematic overview of glenoid fracture percentage as total of glenoid surface

tively stable when the shoulder is centralized, several other authors describe a tendency to recurrent dislocations for these fractures (14,15,49). The size of the fragment can be expressed as percentage of the glenoid diameter, as was described by Itoi (20,33,46), (Fig. 1). A line with 45 degrees inclination is drawn through the fracture gap. A represents the diameter of the outer fitting circle and B the length of the diameter from the outer circle to the fracture line.

The *glenoid fossa fractures* are mostly seen in high energy trauma patients in which the humeral head impacts on the glenoid fossa (12,14,47). These fractures are often transverse, creating a fracture line in the direction of the applied force: either through the lateral-inferior part causing an inferior displacement due to the forces of the triceps, or through the superior part that includes the coracoid process, resulting in an antero-inferior displacement, due to the long head of the biceps and the conjoint tendon (5). The fracture can also extend through the body into the medial border of the scapula (12,48). Direct forces in blunt trauma, causing a scapular fracture, may also extend into the articular surface (3). Up to 60% of these high energy fractures are associated with concomitant injuries to chest, clavicle, humerus, head and brachial plexus (7,12,25,26). The severity of these injuries may distract the attention from the glenoid fracture leading to a delay in its diagnosis.

A rare and difficult injury pattern in which a glenoid fracture might be involved, is the double disruption of the SSSC. In this situation there is a double disruption in the superior bony-ligamentous complex, leading to a potentially unstable situation that is referred to as floating shoulder (15,38).

## DIAGNOSTICS

*The history* of patients with glenoid fractures will mostly consist of either shoulder dislocation or direct trauma to the humeral head. The affected arm is “pseudo-paralysed” and supported in adduction and internal rotation. Because of a thick layer of soft tissue, only mild swelling and ecchymosis may be seen (12,48)

*Physical examination* of the shoulder is often restricted by the acute pain, which inhibits movement of the shoulder. Documentation of the neurovascular status is important to exclude associated injury.

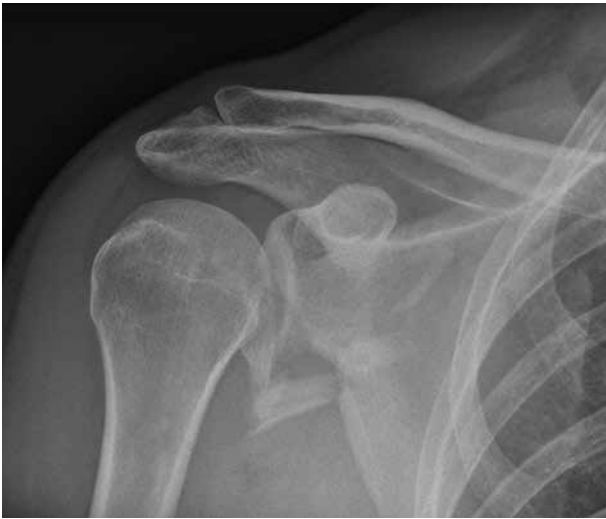*Radiographs* in true anteroposterior (in the scapular plane) and axillary view allow best visualization of disruptions of the glenoid fossa and associated articular incongruity (Fig. 2a and 2b) (9,12). The transscapular projection is mainly used to determine dislocation. The apical oblique view and West Point view are specific for rim fracture detection (38).

*Computerized tomographic scanning* is usually necessary due to the complex osseous anatomy in the region (12,22,49). Most important aspects concerning the fracture are the size and number of fragments, the fracture gap, and centricity of the glenohumeral joint (Fig. 2c). A 3D CT reconstruction can be of added value (3,31,34,45,48).

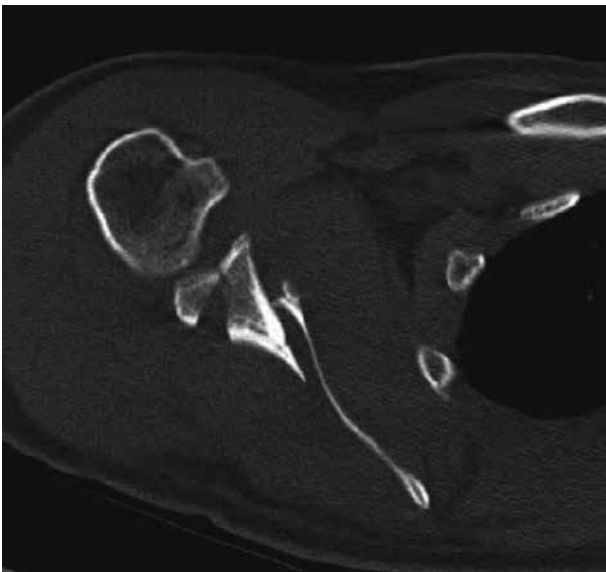
## CLASSIFICATIONS

A number of classification systems for glenoid fractures have been described. None of these systems have been proven to be superior, nor has any system been validated for intra- and inter-observer reliability.

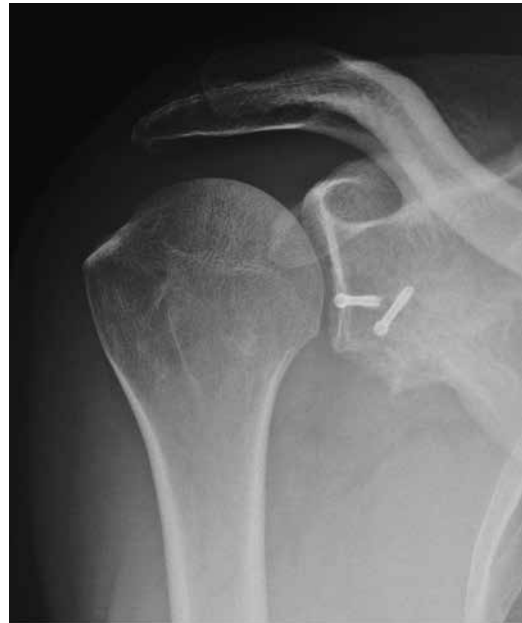*The Ideberg classification* (Fig. 3) is the most widely used classification, later modified by Goss (12,18). This classification consists of 6 main frac-



*Fig. 2a.* — X-ray combined glenoid and scapula fracture



*Fig. 2c.* — CT combined glenoid and scapula fracture



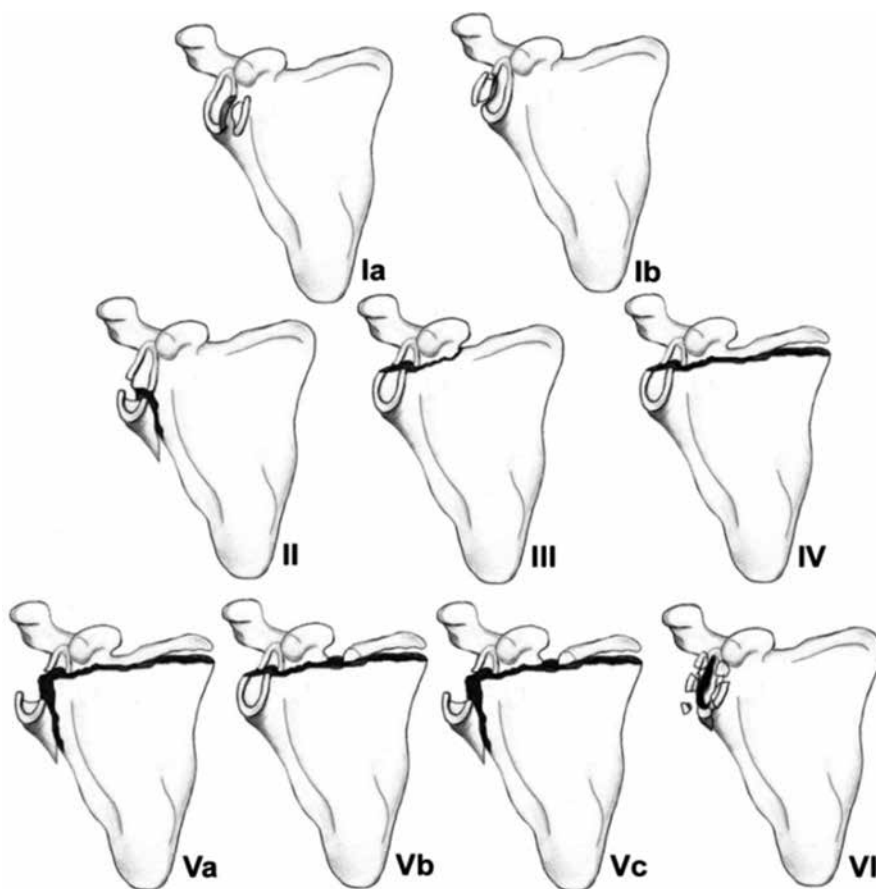
*Fig. 2b.* — postoperative AP and axial X-rays after posterior glenoid screw fixation

ture types, originally based on X-rays of 200 glenoid fractures (5,12,18). The classification has not been shown to be of prognostic value (12). For each type of fracture, operative indication and approach and method of fixation has been described (12,32,48).

An overall fracture classification system, with a separate glenoid part was developed by the Orthopaedic Trauma Association, which was build on AO standards (29,30). It is based on anatomic location and morphology of the fracture. AO/ATO

aims to be a world-wide classification system, though its complexity and inter-observer reliability in other fractures, sometimes obstructs clinical practice (22). Recently a new AO/OTA glenoid fracture classification has been proposed and validated by an international group of shoulder experts, but this has not been validated yet (21).

The scapula fracture classification by *Euler and Habermeyer* is a modification to Rüedi's initial work, and has a subset of glenoid fractures (10,11,



**Fig. 3.** — Ideberg's classification, modified by Goss. Image reprinted with permission from Medscape Reference (<http://emedicine.medscape.com>), 2013, available at : <http://emedicine.medscape.com/article/1263076-overview>

42,49). It has the advantage of simplicity, and fractures can be scored as a combination of one or more types of fracture patterns (42).

## TREATMENT

### General considerations

Most glenoid fractures are small or minimally displaced and can be treated conservatively. Historically only 10% was treated operatively. Although closed reduction has been described (14), it is now uncommonly performed (48). In a recent review, 80% of glenoid fractures were treated operatively, although there were a small number of selected patients, non-standardized fracture management and a low level of evidence (25,52).

Various reports describe treatment algorithms in glenoid fractures (5,12,18,48). In figure 4, a summary of current literature is summarized into a schematic treatment algorithm. Main parameters defining operative treatment are instability, the articular surface fragment size and to lesser extend the degree of displacement (1,3,12,20,23,31,33,40,46,48). However, concomitant injuries (eg thorax, head, extremity fractures, plexus lesion), age, occupation, level of activity and dominance, play a key role in determining the method and timing of treatment (10,12,23,25).

### Avulsions and rim fractures (Ideberg Ia and Ib)

Avulsion fractures (size less than 5 mm) are generally well tolerated (39,50). Treatment of acute

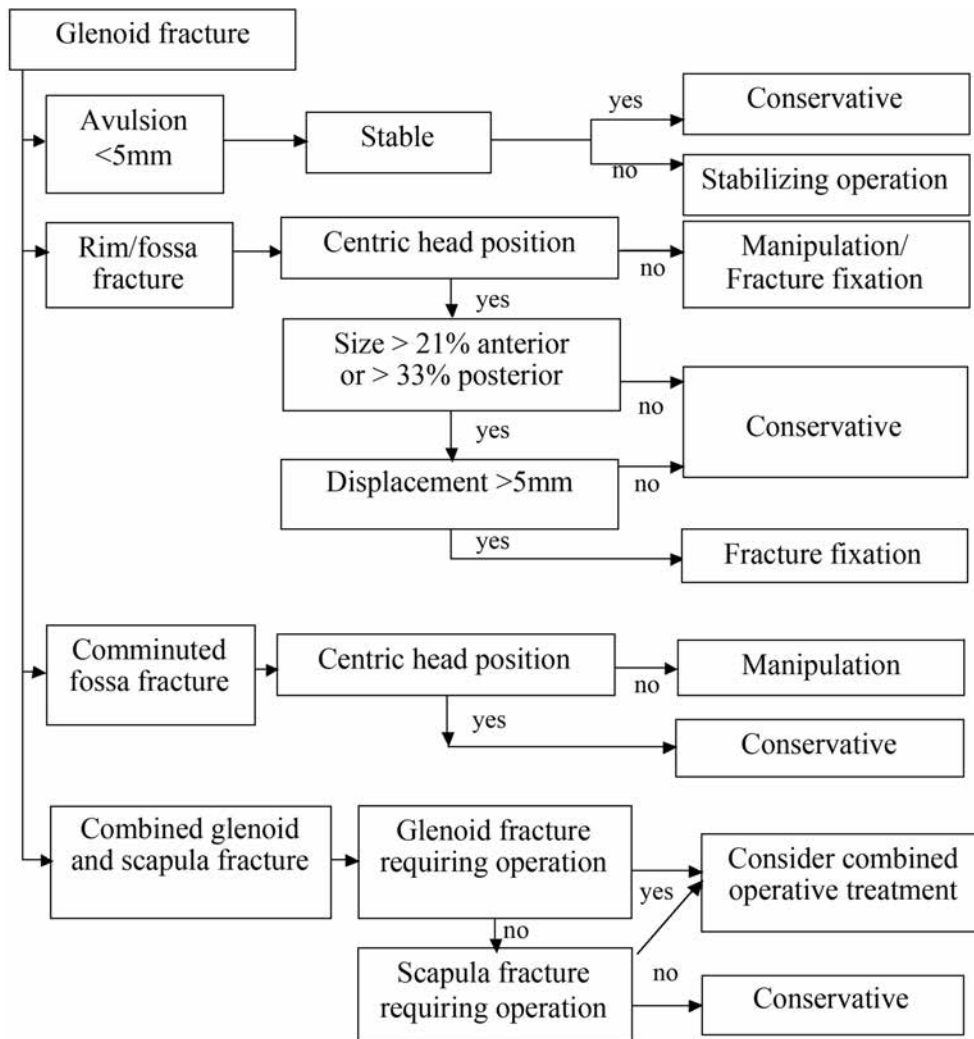


Fig. 4. — Algorithm for treatment of glenoid fractures

cases is guided by either persistent instability or by age and sex. For young (under 30) male patients, arthroscopic reconstruction is the preferred option (37,47).

Rim fractures with displacement of 0-5 mm can be treated with immobilization for a short period (12,24,28). Radiographic and clinical follow-up is necessary as there is risk of progressive instability or displacement (12,47). If concentric reduction cannot be realized, operative treatment should be considered (28). In addition, instability can be expected with displaced anterior rim fractures exceeding 20-

25% of articular surface or more than 33% posterior articular surface (8,12,20,34,36,50). If displacement is more than 4-5 mm, operative treatment should be considered, whereas in cases in which the displacement exceeds 10 mm, surgical intervention is recommended (1,8,23,25,33,34,40,43,48).

**Fossa fracture (Ideberg II-VI)**

In fossa fractures, similar criteria concerning instability and displacement can be applied as for rim fractures : if the humeral head is not centred on

the non-fractured glenoid part, operative treatment is appropriate (34). With regard to displacement, distinction should be made between fracture gap and articular step-off. A fracture gap exceeding 5 mm is indicative for operative reconstruction (Fig. 2a) (43). Regarding step-off in this more central part of the glenoid, a 2 mm limit is generally used in most joints and might be applicable to the glenohumeral joint as well. However, Soslowsky argued to accept a 5 mm step-off because this is the thickness of the glenoid cartilage (43).

With regard to the complex intra-articular scapular fractures, a total reconstruction of the scapula has been described to be the best way to restore anatomy and the basis for glenoid reconstruction (32). A possible contraindication for surgery in these types of fractures are extensive comminuted glenoid fractures (23,49) or the existence of a brachial plexus neuropathy (11).

## SURGICAL TECHNIQUE

### Arthroscopic Approach

The last decade there has been an immense increase in arthroscopic fixation (48). However, indications are limited to fresh rim or avulsion fractures, involving up to 35% of articulating surface (5,25,34-36,44,46,48,51). It can be done either using a suture anchor or by direct percutaneous screw fixation, or a combination of techniques (26,36,40,44,46). In larger fossa fractures reposition can be performed with arthroscopic assistance (49).

### Open approach

In case of an anterior or superior glenoid fractures, the deltopectoral approach is used (5,12,26,34,36,48,49). In the Ideberg classification, this includes type Ia, some II, III, IV and Vb (12,34,48). The patient is placed in a beach chair position. Fixation can be performed by extra-articular cannulated bicortical osteosynthesis (36,46,49). Superior fossa fractures can be reduced either by percutaneous screw fixation after resection of the lateral end of the clavicle (10) or by open reduction extend-

ing the anterior or superior approach, with split of deltoid and/or supraspinatus muscle fibres (34).

A posterior approach is used in about 80% of all glenoid fracture fixations, specifically for posterior and inferior glenoid fractures and scapula wing fractures (Ideberg-Goss type Ib, II, III, IV and V) (5,12,23,25,31,32,34,48). For this procedure, the patient is positioned in lateral decubitus position or prone with the arm in abduction (31,32). There are a number of variations in the posterior approach, all of which use the neuromuscular interval between infra-spinatus and teres minor (Fig. 2b) (5,25).

In the more complex fracture patterns, a combined anterior and posterior approach is required, where the patient is placed in a lateral position (5,25,31). In these cases a variety of fixation techniques is reported, using cannulated screws, plates, bone grafting, cerclage wiring, suture anchors or a combination of these options (29,47).

### Additional fixation

In case of severe anterior comminution, excision of the fragments and replacement by the coracoid process or an iliac crest graft or can re-establish bony stability (12,47). In case of irreparable destruction of the glenoid in combination with major disruption the superior shoulder suspensory complex (SSSC), the SSSC reconstruction can indirectly restore congruity (12). In case of redundancy of the capsule, a capsular shift can be performed (36). To facilitate early postoperative motion, operative treatment of all concomitant shoulder girdle injuries should be considered (31).

## POSTOPERATIVE AND POST-TRAUMA TREATMENT

There is little evidence regarding the treatment protocol for either conservative or post-operative treatment. Protocols vary depending on the type of fracture, the treatment and expected stability. Nowadays there is a tendency for early passive motion exercises (14,34).

For rigidly fixed fractures and conservatively treated minimally displaced fractures, passive cir-

cumduction exercise may start few days after trauma or post-operatively (12,24,28,34,40). Radiographic and clinical follow-up is necessary to monitor displacement (12,47). After 2 weeks, isometric shoulder strengthening and passive assisted motion is started, moving on to active muscle training and full range of motion from 6 weeks onwards (28,31,34). After 4-6 months more active physical rehabilitation can be started (23,34).

In open approaches where tendinous structures have been violated, these will need time to heal. In deltopectoral approach, external rotation is limited to 0-15 degrees, while anteflexion and abduction is limited to 60-90 degrees for the first few weeks (12, 24,28). In patients treated with a posterior approach, an abduction bracing device can limit internal rotation, forward flexion and adduction in the first few weeks (11,12,23). Arthroscopically operated patients will be given less restrictions in passive range of movement, assuming a rigid fixation has been established.

Final rehabilitation result can be expected after 6-12 months (12).

## RESULTS

Unfortunately, most reported results are difficult to interpret due to differences in fracture types, small patient numbers, patient selection, non-standardized treatment protocols and lack of long-term results concerning osteoarthritic changes (34,48). Furthermore the different functional outcome scoring systems which have been used are often not standardized, validated or extensively described (52). In poly-traumatised patients, the clinical outcome of the glenoid fracture mainly depends on concomitant injuries (31). Isolated glenoid fractures generally have a good clinical outcome, irrespective of the treatment method, with good function and little risk to early degeneration (12,28,36,40).

### Conservative treatment

#### *Rim fractures :*

In 1984 Ideberg published a series of 130 rim fractures in which the majority of patients were

treated non-operatively with good results (18). Maquiera published a series of 14 extensive anterior rim fractures with a concentric glenohumeral joint (28). With a mean step-off of 3 mm and a mean displacement of 8 mm, he reported good results after 5.6 years and 3 patients with mild osteoarthritic changes. Kraus had a smaller group with anteroinferior fractures with good results after 2 years (24).

#### *Fossa fractures :*

Around 90% of the glenoid cavity fractures can be treated conservatively with good to excellent results (12). The severely comminuted glenoid fractures however (Ideberg VI) often lead to early osteoarthritic changes or instability (12,47,48).

### Operative treatment

#### *Rim fractures :*

The majority of current reports describe good results in stability and satisfying functional results (18,33,48,52). The arthroscopic approach may lead to improved clinical outcome results and a shift towards operative care. Good results after arthroscopic fixation, even for large fractures have been reported in terms of function and stability (6,35, 44,46).

Raiss reported a series of 29 large anterior rim fractures after open surgery, with excellent results and no significant differences between the conservative versus the operative group in the Constant score after a mean 6.5 years (36). This study has a similar patient population, fracture type and follow-up with very comparable results to the conservative treated population Maquiera (28). Raiss therefore concludes that both conservative and operative treatment in concentrically reduced rim fractures have similar good results.

#### *Fossa fractures :*

A number of case series report on operatively treated fossa fractures, generally with good to excellent functional and longer term radiological results (1,2,4,15,23,26,31,40). This is supported by a



systematic review of 22 studies including 107 glenoid fractures. 80% of these fractures, both rim and fossa, were treated operatively and resulted in good to excellent results in 82% of the patients, versus 67% in the conservatively treated group (52). However, selection -and publication bias should be taken in to account when interpreting all these studies. In some reports a relation between degree of reduction and clinical outcome seems evident since 80% of patients with good clinical outcome had a fracture reduction with a step-off less than 2 mm (23,31). Negative predicting factors are concomitant nerve injury or infections (31,40).

### COMPLICATIONS

Postoperative complications after glenoid fractures consist of hardware failure, infection, stiffness or muscle weakness due to retraction or tenotomy of the rotator cuff (23,31,34,40). Heterotopic bone formation has been reported in 1-10 % of cases and therefore prophylaxis should be considered in all operatively-treated patients (23,25,31). Nerve palsies may occur but it may be difficult to distinguish whether these are caused by the original injury or the operative treatment (25,31). A careful pre-operative clinical examination is therefore essential. Complications for both operative and conservative groups include shoulder instability, pain, loss of reposition, post traumatic osteoarthritis (2%), non-union and persisting limitations in the range of motion 9.

### CONCLUSIONS

Glenoid fractures are relatively rare. Reported data is difficult to appreciate, due to heterogeneity and comorbidities in different studies. Bony avulsions in instability are sometimes included in glenoid fractures, but have been excluded in other glenoid fractures studies. There is lack of clear definition and proven classification regarding glenoid fracture and there is limited scientific evidence on treatment. Clinical outcome of glenoid fractures is generally good in both conservative and operative treatment. As a treatment guideline we summarized available evidence into an algorithm (Fig. 4). More

research is needed on fracture classification, treatment methods and outcome.

### REFERENCE LIST

1. **Adam FF.** Surgical treatment of displaced fractures of the glenoid cavity. *Int Orthop* 2002 ; 26 : 150-153.
2. **Anavian J, Gauger EM, Schroder LK, Wijdicks CA, Cole PA.** Surgical and functional outcomes after operative management of complex and displaced intra-articular glenoid fractures. *J Bone Joint Surg Am* 2012 ; 94 : 645-653.
3. **Armitage BM, Wijdicks CA, Tarkin IS, Schroder LK, Marek DJ, Zlowodzki M, Cole PA.** Mapping of scapular fractures with three-dimensional computed tomography. *JBone Joint Surg Am* 2009 ; 91 : 2222-2228.
4. **Aulicino PL, Reinert C, Kornberg M, Williamson S.** Displaced intra-articular glenoid fractures treated by open reduction and internal fixation. *J Trauma* 1986 ; 26 : 1137-1141.
5. **Bahk MS, Kuhn J E, Galatz LM, Connor PM, Williams GR Jr.** Acromioclavicular and sternoclavicular injuries and clavicular, glenoid, and scapular fractures. *J Bone Joint Surg Am* 2009 ; 91 : 2492-2510.
6. **Bigliani LU, Newton PM, Steinmann SP, Connor PM, McIlveen SJ.** Glenoid rim lesions associated with recurrent anterior dislocation of the shoulder. *Am J Sports Med* 1998 ; 26 : 41-45.
7. **Cole PA, Gauger EM, Schroder LK.** Management of scapular fractures. *J Am Acad Orthop Surg* 2012 ; 20 : 130-141.
8. **De Palma A.** Fracture and fracture dislocations of the shoulder. In: *Surgery of the shoulder*. Lippincott Williams and Wilkins, Philadelphia, 1983 ; 3 : 366-367.
9. **Ebraheim NA, Mekhail AO, Haman SP.** Axillary view of the glenoid articular surface. *J Shoulder Elbow Surg* 2000 ; 9 : 115-119.
10. **Euler E, Habermeyer P, Kohler W, Schweiberer L.** Scapula fractures-classification and differential therapy. *Orthopade* 1992 ; 21 : 158-162.
11. **Goebel M, Seebauer L.** [Open operative treatment of acute glenoid fractures following anterior and posterior shoulder dislocation]. *Oper Orthop Traumatol* 2008 ; 20 : 228-238.
12. **Goss TP.** Fractures of the glenoid cavity. *J Bone Joint Surg Am* 1992 ; 74 : 299-305.
13. **Goss TP.** Double disruptions of the superior shoulder suspensory complex. *J Orthop Trauma* 1993 ; 7 : 99-106.
14. **Guttentag JJ, Reichtine G R.** Fractures of the scapula. A review of the literature. *Orthop Rev* 1988 ; 17 : 147-158.
15. **Hardegger FH, Simpson L A, Weber BG.** The operative treatment of scapular fractures. *J Bone Joint Surg Br* 1984 ; 66 : 725-731.

16. **Hovellius L, Korner L, Lundberg B, Akermark C, Herberts P, Wredmark T, Berg E.** The coracoid transfer for recurrent dislocation of the shoulder. Technical aspects of the Bristow-Latarjet procedure. *J Bone Joint Surg Am* 1983 ; 65 : 926-934.
17. **Huysmans PE, Haen PS, Kidd M, Dhert WJ, Willems JW.** The shape of the inferior part of the glenoid : a cadaveric study. *J Shoulder Elbow Surg* 2006 ; 15(6) : 759-763.
18. **Ideberg R.** Fractures of the scapula involving the glenoid fossa. In : *Surgery of the shoulder.* (Eds. Bateman JE, Welsh RP). Philadelphia, 1984 ; 63-66.
19. **Ideberg R, Grevsten S, Larsson S.** Epidemiology of scapular fractures. Incidence and classification of 338 fractures. *Acta Orthop Scand* 1995 ; 66 : 395-397.
20. **Itoi E, Lee SB, Berglund L J, Berge L L, An KN.** The effect of a glenoid defect on anteroinferior stability of the shoulder after Bankart repair : a cadaveric study. *J Bone Joint Surg Am* 2000 ; 82 : 35-46.
21. **Jaeger M, Lambert S, Sudkamp NP, Kellam JF, Madsen JE, Babst R, Andermahr J, Li W, Audige L.** The AO Foundation and Orthopaedic Trauma Association (AO/OTA) scapula fracture classification system : focus on glenoid fossa involvement. *J Shoulder Elbow Surg* 2013 ; 22 : 512-520.
22. **Jeray KJ, Cole PA.** Clavicle and scapula fracture problems : functional assessment and current treatment strategies. *Instr Course Lect* 2011 ; 60 : 51-71.
23. **Kavanagh BF, Bradway JK, Cofield RH.** Open reduction and internal fixation of displaced intra-articular fractures of the glenoid fossa. *J Bone Joint Surg Am* 1993 ; 75 : 479-484.
24. **Kraus N, Gerhardt C, Haas N, Scheibel M.** Conservative therapy of antero-inferior glenoid fractures. *Unfallchirurg* 2010 ; 113 : 469-475.
25. **Lantry JM, Roberts CS, Giannoudis PV.** Operative treatment of scapular fractures : a systematic review. *Injury* 2008 ; 39 : 271-283.
26. **Leung KS, Lam T P, Poon KM.** Operative treatment of displaced intra-articular glenoid fractures. *Injury* 1993 ; 24 : 324-328.
27. **Lewis GS, Armstrong AD.** Glenoid spherical orientation and version. *J Shoulder Elbow Surg* 2011 ; 20 : 3-11.
28. **Maquieira GJ, Espinosa N, Gerber C, Eid K.** Non-operative treatment of large anterior glenoid rim fractures after traumatic anterior dislocation of the shoulder. *J Bone Joint Surg Br* 2007 ; 89 : 1347-1351.
29. **marra G, Stover M.** Glenoid and scapular body fractures. *Current opinion in orthopedics* 1999 ; 10 : 283-288.
30. **Marsh JL, Slongo TF, Agel J, Broderick JS, Creevey W, DeCoster TA, Prokuski L, Sirkin MS, Ziran B, Henley B, Audige L.** Fracture and dislocation classification compendium - 2007 : Orthopaedic Trauma Association classification, database and outcomes committee. *J Orthop Trauma* 2007 ; 21 (Suppl 10) : S1-133.
31. **Mayo KA, Benirschke SK, Mast JW.** Displaced fractures of the glenoid fossa. Results of open reduction and internal fixation. *Clin Orthop Relat Res* 1998 ; (347) : 122-130.
32. **Nork SE, Barei DP, Gardner MJ, Schildhauer TA, Mayo KA, Benirschke SK.** Surgical exposure and fixation of displaced type IV, V, and VI glenoid fractures. *J Orthop Trauma* 2008 ; 22 : 487-493.
33. **Osti M, Gohm A, Benedetto KP.** Results of open reconstruction of anterior glenoid rim fractures following shoulder dislocation. *Arch Orthop Trauma Surg* 2009 ; 129 : 1245-1249.
34. **Owens BP, Goss TP.** Surgical approaches for glenoid fractures. techniques in shoulder & elbow surgery 2004 ; 5 : 103-115.
35. **Porcellini G, Campi F, Paladini P.** Arthroscopic approach to acute bony Bankart lesion. *Arthroscopy* 2002 ; 18 : 764-769.
36. **Raiss P, Baumann F, Akbar M, Rickert M, Loew M.** Open screw fixation of large anterior glenoid rim fractures: mid- and long-term results in 29 patients. *Knee Surg Sports Traumatol Arthrosc* 2009 ; 17 : 195-203.
37. **Robinson CM, Howes J, Murdoch H, Will E, Graham C.** Functional outcome and risk of recurrent instability after primary traumatic anterior shoulder dislocation in young patients. *J Bone Joint Surg Am* 2006 ; 88 : 2326-2336.
38. **Rockwood C, Matsen FAI, Wirth M, Lippitt S.** The Shoulder. In : Saunders Elsevier, Philadelphia, 2009 ; 4<sup>th</sup> ed. : 333-380.
39. **Salomonsson B, von H A, Dahlborn M, Abbaszadegan H, Ahlstrom S, Dalen N, Lillkrona U.** Bony Bankart is a positive predictive factor after primary shoulder dislocation. *Knee Surg Sports Traumatol Arthrosc* 2010 ; 18 : 1425-1431.
40. **Schandelmaier P, Blauth M, Schneider C, Krettek C.** Fractures of the glenoid treated by operation. A 5- to 23-year follow-up of 22 cases. *J Bone Joint Surg Br* 2002 ; 84 : 173-177.
41. **Scheibel M, Magosch P, Lichtenberg S, Habermeyer P.** Open reconstruction of anterior glenoid rim fractures. *Knee Surg Sports Traumatol Arthrosc* 2004 ; 12 : 568-573.
42. **Schofer MD, Sehrt AC, Timmesfeld N, Stormer S, Kortmann HR.** Fractures of the scapula : long-term results after conservative treatment. *Arch Orthop Trauma Surg* 2009 ; 129 : 1511-1519.
43. **Soslowsky LJ, Flatow EL, Bigliani LU.** Articular geometry of the glenohumeral joint. *Clin Orthop Relat Res* 1992 ; 285 : 181-190.
44. **Sugaya H, Kon Y, Tsuchiya A.** Arthroscopic repair of glenoid fractures using suture anchors. *Arthroscopy* 2005 ; 21 : 635.
45. **Tadros AM, Lunsjo K, Czechowski J, Corr P, Abu-Zidan FM.** Usefulness of different imaging modalities in the assessment of scapular fractures caused by blunt trauma. *Acta Radiol* 2007 ; 48 : 71-75.

46. **Tauber M, Moursy M, Eppel M, Koller H, Resch H.** Arthroscopic screw fixation of large anterior glenoid fractures. *Knee Surg Sports Traumatol Arthrosc* 2008 ; 16(3) : 326-332.
47. **Theivendran K, McBryde CW, Massoud SN.** Scapula fractures : a review. *Trauma and Orthopaedics* 2008 ; (10) : 25-33.
48. **van Noort A.** Scapular fractures. In : Rockwood and Green's Fractures in Adults. (Eds. Bucholz RW, Court-Brown CM, Heckman JD, Tornetta P). Wolters Kluwer, Philadelphia, 2010 ; 7th ed : 1144-1164.
49. **Wiedemann E.** Fractures of the scapula. *Unfallchirurg* 2004 ; 107(12) : 1124-1133.
50. **Yamamoto N, Itoi E, Abe H, Kikuchi K, Seki N, Minagawa H, Tuoheti Y.** Effect of an anterior glenoid defect on anterior shoulder stability : a cadaveric study. *Am J Sports Med* 2009 ; 37(5) : 949-954.
51. **Yang HB, Wang D, He XJ.** Arthroscopic-assisted reduction and percutaneous cannulated screw fixation for Ideberg type III glenoid fractures : a minimum 2-year follow-up of 18 cases. *Am J Sports Med* 2011 ; 39(9) : 1923-1928.
52. **Zlowodzki M, Bhandari M, Zelle BA, Kregor P J, Cole PA.** Treatment of scapula fractures : systematic review of 520 fractures in 22 case series. *J Orthop Trauma* 2006 ; 20(3) : 230-233.