



## Fixation of the greater tuberosity in proximal humeral fractures : FiberWire® or wire cerclage ?

Benjamin BOCKMANN, Benjamin BUECKING, Daphne Asimonia ESCHBACH, Daniel FRANZ,  
Steffen RUCHHOLTZ, Juliane MOHR

*From Department for Trauma, Hand and Reconstructive Surgery, University Medical Center Marburg (site of study),  
Marburg, Germany*

Proximal humeral fractures remain a surgical challenge, and scientific discussions are commonly focused on their ideal treatment. One possible treatment involves the use of an angle stable plate osteosynthesis. However, which material can most feasibly be used to attach the greater tuberosity to the implant remains unknown. In two prospective, non-randomized trials, we compared the results of a FiberWire® and a wire cerclage. A total of 104 patients with 3- and 4-part fractures were included in this examination. In 25 cases, the greater tuberosity was fixated with a FiberWire®, size 2, while 79 cases received a wire cerclage. Plate osteosynthesis was constantly performed via the anterolateral delta-split approach using the NCB®-PH-plate by Zimmer®. The patients were followed clinically at discharge, 6 weeks and 6 months postoperatively and were examined for relevant complications. Age and gender were equally distributed in both groups. Concerning the follow-up after 6 weeks, a significant benefit concerning shoulder function was observed in the FiberWire®- group (wire cerclage :  $39.20 \pm 11.85$ , 95% CI 32.37-44.56, FiberWire® :  $45.84 \pm 16.80$ , 95% CI 28.34-61.56 ;  $p = 0.049$ ). After 6 months, the difference between the groups was not significant (wire cerclage :  $58.13 \pm 18.73$ , 95% CI 50.25-72.40, FiberWire® :  $68.85 \pm 23.10$ , 95% CI 46.83-99.53 ;  $p = 0.06$ )

**Keywords :** proximal humeral fracture ; polyaxial locking plate ; greater tuberosity.

## INTRODUCTION

Representing 5% of all fractures, humeral head fractures are common and are becoming increasingly relevant. The United Nations estimate a yearly increase of 2% in patients older than 60 and an increase of 50% within the next 40 years (16). Typical trauma mechanisms of humeral head fractures include impacts due to falling on the elongated arm. In cases of reduced bone quality, minor trauma can cause the fracture, which is why more than 76% of all humeral fractures are seen in patients older than 60 years (2,6). Women are affected 3 times as often as men due to their predisposition for osteoporosis (12,14).

- 
- Benjamin Bockmann.
  - Benjamin Buecking.
  - Daphne Asimonia Eschbach.
  - Daniel Franz.
  - Steffen Ruchholtz.
  - Juliane Mohr.

*Department for Trauma, Hand and Reconstructive Surgery,  
University Medical Center Marburg (site of study),  
Marburg, Germany.*

Correspondence : Benjamin Bockmann, Department for Trauma, Hand and Reconstructive Surgery, University Medical Center Marburg (site of study), Baldingerstraße, 35043 Marburg, Germany.

E-mail : Benjamin\_bockmann@hotmail.com

© 2015, Acta Orthopædica Belgica.

The optimal treatment for proximal humeral fractures is still under discussion. Depending on the dislocation, number of fragments, bone quality and patient expectations, wires, nails and angle stable plate osteosynthesis are used (4,9,22). Additionally, conservative treatments represent a further important option ; they are preferred in cases of mild dislocation and good bone quality (13). In cases of severe dislocation, total shoulder replacement can be discussed.

Especially in cases with a severe dislocation of the greater tuberosity, the additive use of cerclages to secure the rotator cuff is recommended (8,20). However, the most suitable material for these cerclages remains unknown.

On the one hand, wire cerclages might withstand higher strain, thus securing the reduction of the fracture. They are easily accessible for the surgeon and have been used for many different purposes. On the down side, they traumatize the rotator cuff and are rather stiff.

On the other hand, fiber materials are being used. Due to their greater flexibility and smaller diameter than wire cerclages, they are supposedly more compatible and gentle in their relation to neighboring anatomical structures like the rotator cuff. Unfortunately, no comparing biomechanical studies have been published to this point.

The aim of analyzing the data from patients with humeral head fractures, including dislocations of the greater tuberosity, in two trials was to compare the materials used to attach the greater tuberosity to the angle stable implant, paying particular attention to complication rates and functional results (3,18).

## PATIENTS AND METHODS

In this analysis, 104 patients from two prospective studies were included after their full approval. Their procedures were performed between May 2008 and November 2011, and only patients with a dislocated, proximal humeral fracture with more than 2 fragments were admitted. We considered dislocations as a radiological tilting of the greater tuberosity of more than 10 mm.

Not included were patients with the following :

- 2-fragment fractures
- age younger than 18

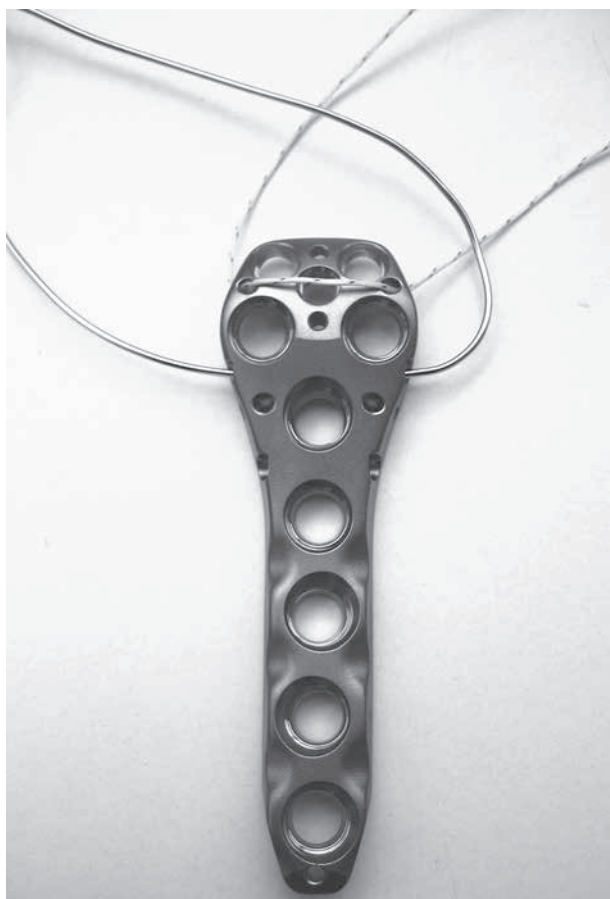- multiple trauma
- pathological fractures
- combined fractures of the upper extremity
- a duration between trauma and surgery of more than 10 days
- preoperative nerve or vessel lesions that persisted after reposition
- II- and III-grade open fractures
- revision osteosynthesis
- fractures combined with shoulder dislocations

Both trials were approved by the local ethics committee (file number 150/09, 142-69192).

According to the standards of our clinic, we used a FiberWire<sup>®</sup>, size 2 to refixate the greater tuberosity. Due to 2 postoperative dislocations of the tuberosity, we used a wire cerclage of 1 mm for the following 79 patients. Further changes to the surgical technique or the postoperative treatment were not applied.

The procedures were performed in the beach chair position using the NCB<sup>®</sup>-PH-plate by Zimmer<sup>®</sup> with an anterolateral deltoid splitting approach. This approach is completed in our clinic according to the following nine defined steps (18) :

1. Minimally invasive approach via anterolateral deltoid splitting and incision of the bursa
2. Digital identification of the axillary nerve and marking of its course on the skin
3. Control and fixation of the greater and lesser tuberosity
4. Reposition of the fracture by slight axial traction. Only complete reduction of the greater tuberosity to its initial anatomical position was accepted in both treatment groups. Correct reduction was evaluated by the respective surgeons, using intraoperative fluoroscopy from a.p. and axial view. Additionally, postoperative control radiographs were performed.
5. Temporary fixation of the fracture via Kirschner wires
6. Temporary fixation of the plate
7. Fixation of the plate on the diaphysis
8. Application of the head screws
9. Fixation of the greater tuberosity via wire cerclage or FiberWire<sup>®</sup>. The respective material is gently pulled through the lateral aspect of the supraspinatus tendon at the tendino-osseous transition and then pulled through the designated holes in the implant (Fig. 1). Surgical knots are then applied in the usual technique using just slight manual traction, thus preventing over-tightening of the tuberosities.



**Fig. 1.** — The NCB®-PH-plate by Zimmer® Inc. including attachment possibilities for FiberWire® and cerclage wire.

The operative shoulder was immobilized for the first 2 days after surgery. Only limited assisted abduction up to 90° was allowed for the first 6 weeks after surgery.

Pain and subjective shoulder function were recorded using a visual analog scale (VAS) at discharge, 6 weeks and 6 months postoperatively (1). Our patients chose a value on a graphic scale from 0 to 10 according to their personal perception of pain and shoulder function. Thus, a low value showed a low degree of pain or bad shoulder function, and a high value showed a high degree of pain or good shoulder function. At 6 weeks and 6 months, the Activities of Daily Living (ADL), Constant Score – adapted to gender and age as described by Katolik– and the American Shoulder and Elbow Surgeons Score (ASES) were registered as well (5,10-11). Apart from these data, relevant complications were recorded at all times.

Results were documented on each patient sheet and registered in a database. Eventually, an analysis was performed using SPSS 17 (SPSS Inc, Chicago, IL, USA), and graphics were generated via GraphPad Prism 6 (GraphPad Software Inc., La Jolla, CA, USA). The peri-operative parameters demonstrated a standard deviation and were thus treated with an analysis of variances with respect to age and gender. Functional parameters (pain, shoulder function, Constant Score, ADL, ASES) were also examined via an analysis of variances. Complications were evaluated using the  $\chi^2$ -test. A difference was considered significant if the p-value was < 0.05.

## RESULTS

Of the 104 analyzed patients, 25 received a FiberWire®, and 79 received a wire cerclage. In the FiberWire® group, 18 patients (72%) showed a 3-fragment and 7 (28%) showed a 4-fragment fracture. In the wire cerclage group, 69 (87%) presented with a 3-fragment and 10 (13%) presented with a 4-fragment fracture. However, there was no significant difference between the 3- and 4-fragment fractures ( $p = 0.43$ ). The mean age was  $67 \pm 13$  years in the wire cerclage group and  $63 \pm 13$  years in the FiberWire® group, without a significant difference ( $p = 0.27$ ). The gender deviation showed 20 males (25%) and 59 females (75%) in the wire cerclage group, whereas 4 males (16%) and 21 females (84%) were seen in the FiberWire® group (Tab. I). There was no significant difference between the two groups concerning the length of the procedure (wire cerclage  $66 \pm 26$  min, FiberWire® :  $65 \pm 21$  min,  $p = 0.88$ ), fluoroscopy time (wire cerclage  $1.7 \pm 1.1$  min, FiberWire® :  $1.7 \pm 1.0$  min,  $p = 0.93$ ) or hospital stay (wire cerclage  $10 \pm 4$  d, FiberWire® :  $10 \pm 3$  d,  $p = 0.62$ ). Good reduction of the greater tuberosity could be reached in all cases.

At 6 weeks postoperatively, 93 patients (89%) and, at 6 months postoperatively, 74 patients (71%) completed follow up.

The VAS for pain showed no significant difference at any point of examination (discharge : wire cerclage :  $4.52 \pm 1.79$ , FiberWire® :  $4.59 \pm 1.53$ ,  $p = 0.79$  ; 6 weeks : wire cerclage :  $3.88 \pm 1.97$ , FiberWire® :  $3.34 \pm 2.04$ ,  $p = 0.22$  ; 6 months : wire cerclage :  $2.99 \pm 2.06$ , FiberWire® :  $2.38 \pm 1.52$ ,  $p = 0.32$  ; fig. 2).

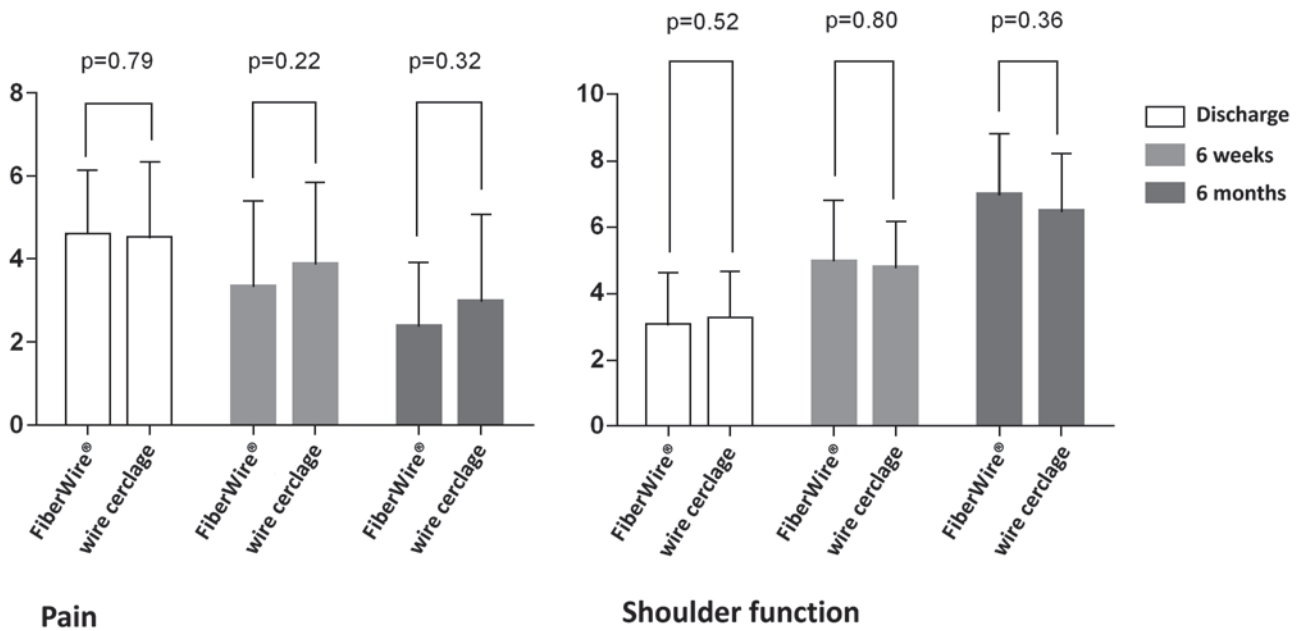


Fig. 2. — Pain and shoulder function at dismissal, after 6 weeks and 6 months

Table I. — Demographic results of patient groups (mean average and 95% confidence interval)

	Wire cerclage (n = 79)	FiberWire® (n = 25)
Age [years]	67 (64-70)	63 (58-69)
Gender	m: 20 (25%) f: 59 (75%)	m: 4 (16%) f: 21 (84%)

The VAS for shoulder function showed a significant improvement for both materials ; however, no significant difference could be seen between the two treatment groups at any point (discharge : wire cerclage :  $3.22 \pm 1.40$ , FiberWire® :  $3.05 \pm 1.54$ ,  $p = 0.52$  ; 6 weeks : wire cerclage :  $4.77 \pm 1.35$ , FiberWire® :  $4.96 \pm 1.82$ ,  $p = 0.80$  ; 6 months : wire cerclage :  $6.47 \pm 1.70$ , FiberWire® :  $6.97 \pm 1.80$ ,  $p = 0.36$  ; fig. 2).

The ADL were equal in both groups before the fracture (wire cerclage :  $27.19 \pm 4.50$ , FiberWire® :  $29.04 \pm 1.52$ ,  $p = 0.11$ ). After 6 weeks and 6 months, both groups were able to approach their previous level of activity ; again, there was no difference between the 2 materials (6 weeks : wire cerclage :  $13.19 \pm 3.90$ , FiberWire® :  $14.42 \pm 5.71$ ,  $p = 0.21$  ;

6 months : wire cerclage :  $17.98 \pm 5.68$ , FiberWire® :  $20.59 \pm 6.65$ ,  $p = 0.15$ ).

With regard to shoulder function in the Constant Score (Fig. 3), the FiberWire® group showed significantly better results after 6 weeks than the wire cerclage group (wire cerclage :  $39.20 \pm 11.85$ , FiberWire® :  $45.84 \pm 16.80$ ,  $p = 0.049$ ). After 6 months, the FiberWire® group still showed better results ; however, no significance was reached at this point (wire cerclage :  $58.13 \pm 18.73$ , FiberWire® :  $68.85 \pm 23.10$ ,  $p = 0.06$  ; Tab. II).

In the FiberWire® group, 5 patients (20%) were revised. In 2 cases, postoperative dislocation of the greater tuberosity was seen (Fig. 4) ; in 1 of these cases, an additional perforation of a head screw was observed. The third case showed a loosening of a head screw ; the fourth showed a single perforation of a head screw. In the fifth case, a secondary infection of the rotator cuff was followed by a total shoulder replacement.

In the wire cerclage group, 16 patients (20%) had to undergo revision, and 9 cases showed screw perforation. 1 case showed a primary malpositioning of the implant, leading to a revision with the correction of the implant position. Furthermore, we recorded

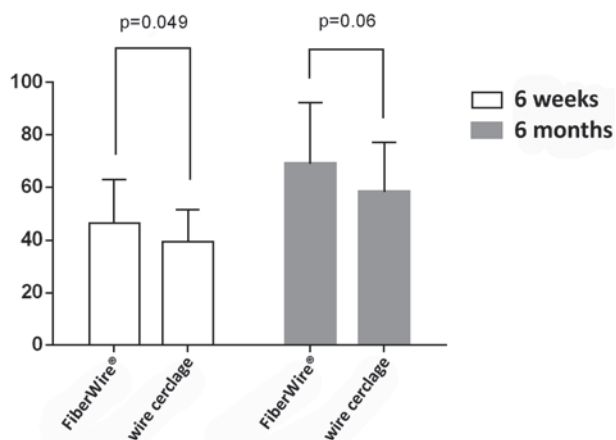


Fig. 3. — Age and gender dependent Constant Score after 6 weeks and 6 months.

one case of a late dislocation of the greater tuberosity and another case with a deep wound infection. In 4 cases, sintering with consecutive implant failure led to total shoulder replacement. 1 patient died due to reasons that were not related to the procedure.

Lesions of the axillary nerve were not seen in any patient.

The complication rates between the groups showed no significant difference ( $\chi^2$ -Test:  $p = 0.98$ ).

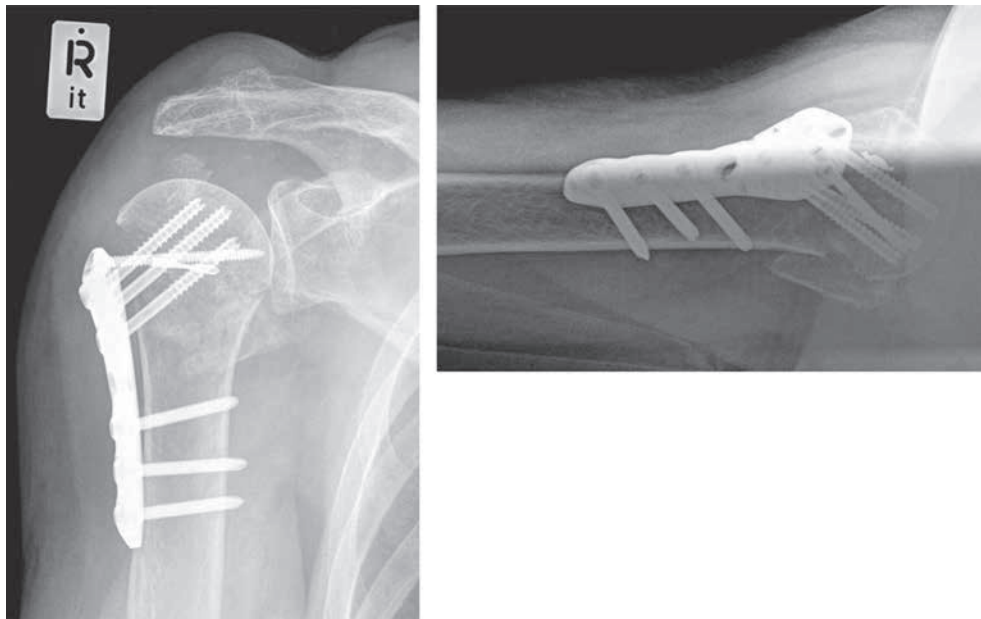
### DISCUSSION

This analysis examined the influence of 2 different materials used to refixate the greater tuberosity in multifragmental humeral fractures.

A series of trials has already outlined the importance of angle stable implants and the correct refixation of the greater tuberosity. In a 2004 prospective trial including 35 patients, Hente showed that secondary dislocation and subacromial impingement are more often seen if additional fixation with wire material is omitted. He recorded this outcome in 2 of his patients (8). In 2007, Smith postulated that a consequent refixation of the greater tuberosity is essential to prevent secondary complications. He performed a trial including 82 patients (19). However, a biomechanical study performed by Voigt in 2009 showed that additional wire material does not improve the reposition stability in PHILOS

Table II. — Perioperative results and clinical outcome of both treatment groups (mean average and 95% confidence interval)

	Wire Cerclage (n = 79)	FiberWire® (n = 25)	Significance
Duration [min]	66 (55-74)	65 (34-72)	$p = 0.88$
Fluoroscopy [min]	1.7 (1.2-2.5)	1.7 (1.0-1.6)	$p = 0.93$
Hospital stay [d]	10 (9-14)	10 (8-12)	$p = 0.62$
VAS Pain			
- Discharge	4.52 (3.80-5.70)	4.59 (3.57-4.60)	$p = 0.79$
- 6 weeks	3.88 (3.41-5.48)	3.34 (2.61-5.06)	$p = 0.22$
- 6 months	2.99 (2.46-4.32)	2.38 (0.87-4.13)	$p = 0.32$
VAS Shoulder function			
- Discharge	3.22 (2.38-4.01)	3.05 (3.08-4.78)	$p = 0.52$
- 6 weeks	4.77 (4.23-5.49)	4.96 (3.57-6.93)	$p = 0.80$
- 6 months	6.47 (5.70-7.38)	6.97 (5.47-9.36)	$p = 0.36$
ADL			
- Before trauma	27.19 (25.67-29.55)	29.04 (28.62-30.38)	$p = 0.11$
- 6 weeks	13.19 (11.18-15.04)	14.42 (7.61-22.39)	$p = 0.21$
- 6 months	17.98 (15.38-21.18)	20.59 (11.55-29.78)	$p = 0.15$
ASES			
- 6 weeks	52.95 (43.18-56.06)	58.09 (42.07-69.59)	$p = 0.09$
- 6 months	63.39 (56.63-70.40)	72.38 (49.31-94.59)	$p = 0.07$
Constant- Score			
- 6 weeks	39.20 (32.37-44.56)	45.84 (28.34-61.56)	$p = 0.049$
- 6 months	58.13 (50.25-72.40)	68.85 (46.83-99.53)	$p = 0.06$



*Fig. 4.* — Dislocation of the greater tuberosity, female patient, 6 weeks after surgery

implants (21). In 2011, Foruria demonstrated that a secondary dislocation of the greater tuberosity in the cranial direction is the main source of postoperative dysfunction, naming subacromial impingement as the main cause. Furthermore, he found an increase of pain of 0.8 points on the VAS per 10 mm dislocation (7). Ruchholtz *et al* confirmed the same year that the use of the NCB<sup>®</sup>-PH plate in minimally invasive surgery, as performed in our hospital, can provide good clinical results. He measured a Constant Score of 67 points after 6 months (18). Another work by our group revealed that there is no significant difference between the deltopectoral and deltoid splitting approach regarding shoulder function or complication rates, especially concerning dislocations of the greater tuberosity (15). Our results can be interpreted as follows : the perioperative results were comparable in both groups and were in line with the data from other similar trials (9,17-18,22). Regarding pain and shoulder mobility on both the VAS and ADL, both groups showed a significant improvement during the course of our trials. However, no significant difference was seen between the two groups. Our patients show similar results to those of patients from other trials ; thus, a further lowering of pain levels and improvement in

the ADL can be expected in the following months (9,22). Concerning shoulder function in the age- and gender-related Constant Score, the FiberWire<sup>®</sup> group showed significantly better results after 6 weeks. The reason for this could be the smaller strain in the neighboring anatomical structures because the FiberWire<sup>®</sup> has a smaller diameter and better gliding properties than the wire cerclage. After 6 months, a difference could still be seen, although no statistical significance was achieved. This lack of significance could have been caused by the small number of patients in the FiberWire<sup>®</sup> group.

The complication rate was 20%. This rather high amount could be explained by the fact that we only included multifragment fractures. Our results are comparable with those in the literature and confirm the status of the humeral fracture as a surgical challenge (20). A major problem we encountered was the dislocation of the greater tuberosity in patients from the FiberWire<sup>®</sup> group. This was seen in two of the 25 cases and is probably because the 'holes' in the plate are cutting the wire. Especially in geriatric patients with potentially low bone densities, the reliability of the refixation plays a decisive role in the restoration of shoulder mobility. Thus, our

hospital's treatment strategy was changed. By using wire cerclages, we were able to identify a material that offered a better consistency in the refixation of the greater tuberosity. However, the disturbance of neighboring anatomical structures weakened the shoulder's function after 6 weeks.

Further research should consider the usage of more compliant materials that will not compromise primary stability, shoulder function or pain levels. Until further results can be obtained, wire cerclages remain our first choice. Major limitations of this study included the uneven size of the treatment groups, the low follow-up rates (89% after 6 weeks, 71% after 6 months), the non-randomized study design and the short observation period. Especially the follow up rate is a problem- of those patients that were not followed, some might show dislocations of the greater tuberosity that were not detected. Prospective, randomized trials could be helpful for future investigations.

## CONCLUSION

In summary, the use of both materials leads to adequate clinical results. Pain levels and shoulder mobility showed significant improvements in both groups. Regarding the preoperative ADL, patients generally approached their previous levels after the procedure. Complication rates did not differ significantly between the two materials, and all clinically relevant lesions of the axillary nerve were prevented.

The use of FiberWire® may facilitate better results concerning shoulder function during the first 6 weeks. Still, the higher dislocation rate of the greater tuberosity remains an obstacle.

## REFERENCES

- Aitken RC.** Measurement of feelings using visual analogue scales. *Proc R Soc Med* 1969 ; 62 : 989-993.
- Boileau P, Trojani C, Walch G, Krishnan SG, Romeo A, Sinnerton R.** Shoulder arthroplasty for the treatment of the sequelae of fractures of the proximal humerus. *J Shoulder Elbow Surg* 2001 ; 10 : 299-308.
- Buecking B, Mohr J, Bockmann B, Zettl R, Ruchholtz S.** Deltoid-split or Deltopectoral Approaches for the Treatment of Displaced Proximal Humeral Fractures ? *Clin Orthop Relat Res* 2014 : 472 (5) : 1576-1585.
- Cai JF, Yuan F, Ma M, Zhou W, Luo SL, Yin F.** Anterolateral acromial approach in locking plate fixation of proximal humerus fractures in elderly patients. *Acta Orthop Belg* 2013 ; 79 : 502-508.
- Constant CR, Murley AH.** A clinical method of functional assessment of the shoulder. *Clin Orthop Relat Res* 1987 : 160-164.
- Court-Brown CM, Garg A, McQueen MM.** The translated two-part fracture of the proximal humerus. Epidemiology and outcome in the older patient. *J Bone Joint Surg Br* 2001 ; 83 : 799-804.
- Foruria AM, de Gracia MM, Larson DR, Munuera L, Sanchez-Sotelo J.** The pattern of the fracture and displacement of the fragments predict the outcome in proximal humeral fractures. *J Bone Joint Surg Br* 2011 ; 93 : 378-386.
- Hente R, Kampshoff J, Kinner B, Fuchtmeier B, Nerlich M.** [Treatment of dislocated 3- and 4-part fractures of the proximal humerus with an angle-stabilizing fixation plate]. *Unfallchirurg* 2004 ; 107 : 769-782.
- Hepp P, Theopold J, Voigt C, Engel T, Josten C, Lill H.** The surgical approach for locking plate osteosynthesis of displaced proximal humeral fractures influences the functional outcome. *J Shoulder Elbow Surg* 2008 ; 17 : 21-28.
- Katolik LI, Romeo AA, Cole BJ, Verma NN, Hayden JK, Bach BR.** Normalization of the Constant score. *J Shoulder Elbow Surg* 2005 ; 14 : 279-285.
- King GJ, Richards RR, Zuckerman JD, Blasier R, Dillman C, Friedman RJ, Gartsman GM, Iannotti JP, Murnahan JP, Mow VC, Woo SL.** A standardized method for assessment of elbow function. Research Committee, American Shoulder and Elbow Surgeons. *J Shoulder Elbow Surg* 1999 ; 8 : 351-354.
- Kollig E, Kutscha-Lissberg F, Roetman B, Dielenschneider D, Muhr G.** [Complex fractures of the humeral head : which long-term results can be expected ?]. *Zentralbl Chir* 2003 ; 128 : 111-118.
- Koval KJ, Gallagher MA, Marsicano JG, Cuomo F, McShinawy A, Zuckerman JD.** Functional outcome after minimally displaced fractures of the proximal part of the humerus. *J Bone Joint Surg Am* 1997 ; 79 : 203-207.
- Lill H, Josten C.** [Proximal and distal humerus fractures in advanced age]. *Orthopade* 2000 ; 29 : 327-341.
- Mohr J, Bockmann B, Buecking B, Zettl R, Kuehne CA, Ruchholtz S.** Plattenosteosynthese von proximalen Humerusfrakturen. Minimal-invasiver Deltasplit vs deltoideopektoraler Zugang : Bestehen Vorteile für einen Zugangsweg ? *Obere Extremität* 2012 ; 7 (3) : 144-149.
- Nations U.** United Nations Department of Economic and Social Affairs/Population Division 87 World Population Prospects. New York, 2008.
- Roderer G, Erhardt J, Kuster M, Vegt P, Bahrs C, Kinzl L, Gebhard F.** Second generation locked plating of proximal humerus fractures – a prospective multicentre observational study. *Int Orthop* 2011 ; 35 : 425-432.

- 18. Ruchholtz S, Hauk C, Lewan U, Franz D, Kuhne C, Zetl R.** Minimally invasive polyaxial locking plate fixation of proximal humeral fractures : a prospective study. *J Trauma* 2011 ; 71 : 1737-1744.
- 19. Smith AM, Mardones RM, Sperling JW, Cofield RH.** Early complications of operatively treated proximal humeral fractures. *J Shoulder Elbow Surg* 2007 ; 16 : 14-24.
- 20. Voigt C, Woltmann A, Partenheimer A, Lill H.** [Management of complications after angularly stable locking proximal humerus plate fixation]. *Chirurg* 2007 ; 78 : 40-46.
- 21. Voigt C, Hurschler C, Rechi L, Vosshenrich R, Lill H.** Additive fiber-cerclages in proximal humeral fractures stabilized by locking plates : no effect on fracture stabilization and rotator cuff function in human shoulder specimens. *Acta Orthop* 2009 ; 80 : 465-471.
- 22. Wu CH, Ma CH, Yeh JJ, Yen CY, Yu SW, Tu YK.** Locked plating for proximal humeral fractures : differences between the deltopectoral and deltoid-splitting approaches. *J Trauma* 2011 ; 71 : 1364-1370.