



The Müller acetabular reinforcement ring – still an option in acetabular revision of Paprosky 2 defects ? Longterm results after 10 years

C. KÖSTERS, B. SCHLIEMANN, D. DECKING, U. SIMON, M. ZURSTEGGE, J. DECKING

From Department of Trauma-, Hand- and Reconstructive Surgery, University Hospital, University of Muenster, Muenster, Germany

Introduction : Aim of this study was to measure the clinical and radiological longterm outcome after acetabular revision arthroplasty (RTHA) using the Müller acetabular reinforcement ring.

Materials and Methods : 86 patients with 90 revision arthroplasties and a mean age of 68 years (41 to 84) were included. The mean follow-up was 10 years (range 7-12). The Harris Hip Score and the WOMAC Index were used to assess pain and functional outcome. Furthermore clinical examination of range of motion and radiologic examinations were performed in 34 patients.

Results : The radiologic analysis reports no signs of loosening in 79%, 15% showed possibly loosening and 6% probable loosening. Definite radiologic loosening has not been detected. In the meantime 12 patients (13.3%) of 90 revision total hip arthroplasty underwent a revision of the acetabulum with change of the acetabular component which means a survival rate of 86.7% after 10 years follow-up. The mean center of rotation of the hip moved 0.15 cm (SD 0.74 cm) laterally and 0.1 cm (SD 0.97 cm) cranially based on the geometrically reconstructed center of rotation. A mean score of 58 points for the Harris Hip Score (range 14-93) indicated a poor functional outcome, while a mean value of 96 points (range 0-223) for the WOMAC Index indicated good results for functional outcome in daily living.

Conclusions : The revision arthroplasty in cases with acetabular defects using the Müller acetabular reinforcement ring shows acceptable longterm results.

Level of Evidence : Level IV.

Keywords : revision total hip arthroplasty ; Müller Ring ; acetabular reinforcement ring ; clinical outcome ; Paprosky classification.

INTRODUCTION

The restoration of bone stock and the reconstruction of the original center of rotation are the main goals of revision total hip arthroplasty (RTHA) of

-
- C. Kösters.
■ B. Schliemann.
Department of Trauma-, Hand- and Reconstructive Surgery, University Hospital, University of Muenster, Muenster, Germany.
 - D. Decking.
■ U. Simon.
Department of Orthopedic Surgery, St. Franziskus Hospital, Muenster, Germany.
 - M. Zurstege.
Department of Orthopedic and Trauma Surgery, Asklepios Clinic, Bad Tölz, Germany.
 - J. Decking.
Department of Orthopedic Surgery, Kantonsspital, Luzern, Switzerland.

Correspondence : Dr med Clemens Kösters, Department of Trauma-, Hand- and Reconstructive Surgery, University Hospital, University of Muenster, Albert Schweitzer Campus 1, Building W1, 48149 Muenster, Germany.

E-mail : Clemens.Koesters@ukmuenster.de

© 2015, Acta Orthopædica Belgica.

the acetabulum. The first specialized revision device was developed by Eichler in 1973 (6). M.E. Müller engineered the acetabular reinforcement ring (ARR) in 1976. Further advancements were the Ganz reinforcement hook ring and the Burch-Schneider reinforcement ring. These last devices are at present commonly used in acetabular RTHA. Most frequently surgeons have to restore acetabular defects classified Paprosky 2 a, b or c. In these cases the acetabulum shows increasing central cavitory defects with preserved continuity of the pelvis (17).

Starker *et al* in 1998 showed that the ARR will lead to a more cranial reconstruction of the center of rotation when substantial loss of structural bone in the cranial part of the acetabulum is present. Furthermore they postulated that the ARR design may lead to a horizontal malpositioning of the implant and subsequent loosening (27). They recommend the use of the ARR only in cases with segmental continuity of the acetabulum.

Therefore, the aim of this study was to analyze the functional and radiological outcome after acetabular revision with the ARR and to investigate whether there is still a warranty for the use of this device.

PATIENTS AND METHODS

86 patients treated for 90 RTHA between January 1991 and December 1995 and a mean age at operation of 68 years (41 to 84 years) were included. Data was collected in 2003. The mean follow-up was 10 years (range 7-12).

82 cases were first RTHA, in 5 cases the acetabulum was revised for the second time, in 2 cases for the third time and in 1 case it was the fourth RTHA. 73% of the patients were female, 27% male.

Indications for acetabular RTHA were isolated acetabular loosening (55%), complete loosening of stem and cup (40%), periprosthetic acetabular fracture (4%) and recurrent hip dislocations (1%). Patients with septic loosening of the acetabular component were excluded from this study.

35 (41%) of 86 patients (37 RTHA) were clinically and radiologically examined. The dropout rate was high as 20 patients (23%) died in the meantime and 31 (36%) patients didn't want to participate in the study. Outcome scores and additional data of each of these patients were collected by telephone calls.

Data regarding type of operative treatment and comorbidities was extracted from the medical charts.

In all cases the original ARR according to M. E. Müller (Centerpulse Orthopedics, now Zimmer Inc., Warsaw, IN) (Fig. 1a and b) was used to reconstruct the acetabulum.

Acetabular bone defects were augmented in all cases with femoral head allografts. Bone grafts were used either as morselized bone (8.3%) or as bulky structural grafts (13.4%) or as a combination of both (78.3%). In none of the cases autogenous cancellous iliac crest bone grafts were added. In all cases a posterior approach to the hip was used. All RTHA were performed by two senior orthopaedic surgeons.

Clinical evaluation included the assessment of anamnestic data as well as documentation of bilateral range of motion of the hip (ROM) measured by a goniometer, Trendelenburg's sign, and limp.

Functional outcome was assessed with two frequently-used questionnaires and outcome-scores. The Harris-Hip-Score was used to determine hip pain and function. A maximum of 100 points can be reached evaluating the four categories "pain", "function", "range of motion" and "absence of deformities" (10). We considered 100-90 points as "very good" result, 89-80 points as "good" result, 79-70 points as "fair" result and less than 70 points as "poor" result.

The subjective contentment of the patients was evaluated by a questionnaire. Patients had to choose between the options "very satisfied", "predominantly satisfied", "less satisfied" and "not satisfied".

A german version of the Western Ontario und McMaster Universities osteoarthritis index (WOMAC) is commonly performed to evaluate symptoms and physical disorders in daily living after RTHA. The WOMAC was validated in several pharmacological, surgical and rehabilitative studies as a reliable and process sensible instrument to determine differences in pain, stiffness and limitations of physical function in patients with osteoarthritis (1).

To mainly address the clinical and functional outcome parameters we formed a summary score of the only three domains "pain", "stiffness" and "function". Each of the 24 questions was valued with a maximum value of 10 points summarizing a maximum score of 240 points of all 24 questions. We defined 0 to 60 points a "very good result", 61 to 120 points a "good result", 121 to 180 points a "fair result" and 180 to 240 points a "poor result".

Standardized radiographs were obtained with anteroposterior views of the pelvis and lateral views of the hip

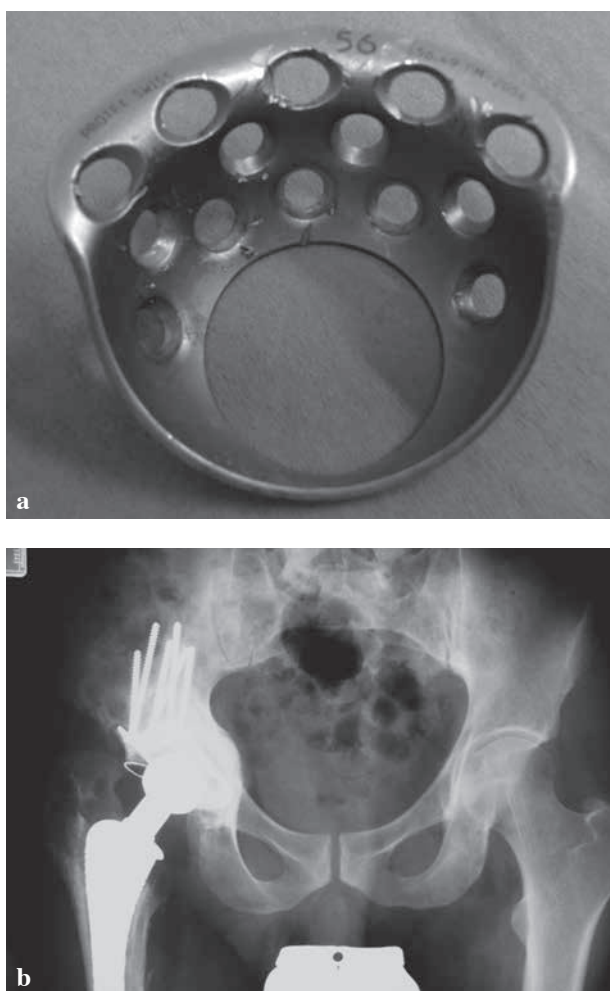


Fig. 1a and b. — Müller acetabular reinforcement ring after explantation (a) and on postoperative radiograph (b).

and were evaluated by two senior orthopedic surgeons. None of the cases got a CT scan examination.

The Paprosky classification was used intraoperatively by the surgeons to grade the acetabular bone stock deficiency (17).

Radiographs were surveyed regarding radiologic signs of loosening of the reinforcement rings according to the classification of Gill (7). Therefore complete radiographic loosening of the ARR (type 3) was defined as breakage of the ARR fixating screws, a complete radiolucent line medial and cranial of the ring or a migration of the implant more than 5 mm.

The measurement of the center of rotation (COR) of the hip was performed according to Pagnano and Stans (15,26)

Heterotopic ossifications were classified with the Brooker-Classification (3).

Clinical data and data of the measurement of the center of rotation were described by mean, range and standard deviation.

RESULTS

Range of motion of the operated hip showed a mean flexion of 91° (standard deviation (sd) 20°) and a mean extension of -4° (sd 7°) detecting a moderate flexion contracture. The data regarding abduction, adduction, internal rotation and external rotation is demonstrated in table I.

In 12 patients (34%) a strong limp and in 8 patients (23%) a moderate limp was detected. 14 patients (40%) showed just a slight limp, while in 1 patient (3%) no limp was present. 26 patients (74%) demonstrated a positive Trendelenburg's sign.

At follow-up the mean score of the Harris Hip Score was 58 points (14-93), while a mean value of 96 points (0-223) was reached for the WOMAC index. In the Harris Hip Score 61% of the patients were graded into the category " < 70 points", which is considered a poor result. Figure 2 shows the percental distribution of the Harris Hip Score.

The distribution of patients into the four categories of the WOMAC index was more balanced compared to the Harris Hip Score. 33.9% were grouped into "0-60 points", 32.2% were graded into "61-120 points" and 23.7% of the patients reached the interval of "121-180 points". This means that more than 55% of the patients achieved a "very good" or "good" result for functional outcome in daily living (Fig. 3).

Subjective contentment was "satisfied" or "predominant satisfied" in 92%, 5% of the patients were "less satisfied" and 2% were "not satisfied".

In the meantime 12 patients (13.3%) of 90 RTHA which were clinically examined or the data was collected by telephone calls underwent a revision of the acetabulum with change of the acetabular component which means a survival rate of 86.7% after 10 years follow-up. 8 of these patients were revised in cause of septic loosening, in 4 patients reason for revision was aseptic loosening.

Table I. — Mean value of range of motion

Direction of motion	Mean value in degree	Standard deviation indegree
Flexion	91	20
Extension	-4	7
Abduction	22	9
Adduction	11	6
Internal Rotation	8	6
External Rotation	9	7

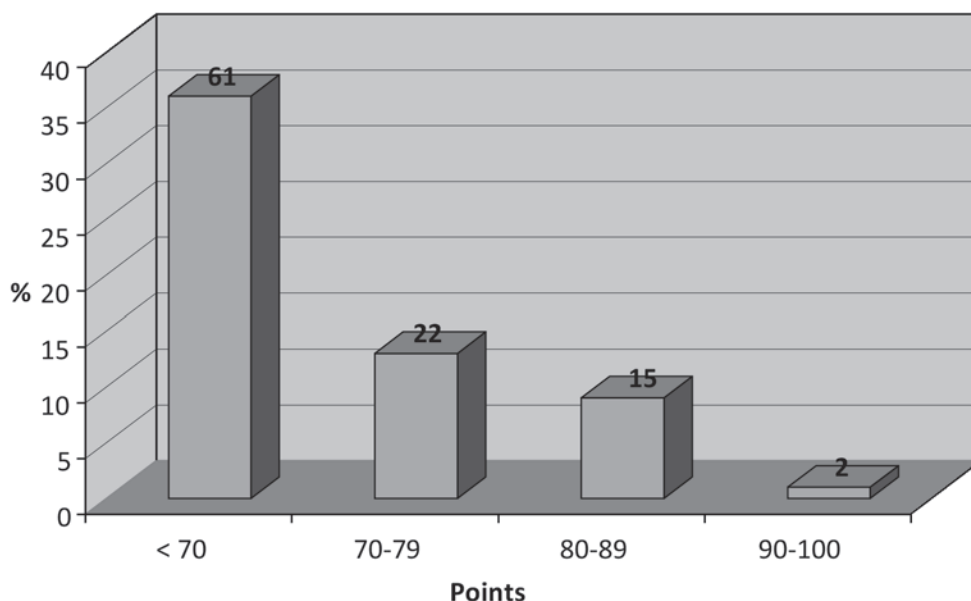


Fig. 2. — Percental distribution of the Harris Hip Score

Evaluating the radiographs at follow-up grade 1 heterotopic ossifications according to Brooker were found in more than half (53%) of the radiographs examined. Grade 2 ossifications were identified in 32% of cases and grade 3 ossifications were detected in 16% of the radiographs. There was no case of ankylosis corresponding a grade 4 according to Brooker (Fig. 4).

In 79% of the radiographs there were no signs of loosening corresponding to the Gill classification. Loosening signs grade 1 were present in 15% and grade 2 in 6% of the radiographs at follow-up. Signs of complete loosening were not detected (Fig. 5).

The center of rotation (COR) showed a mean lateral migration of 0.15 cm (sd 0.74 cm) and a mean cranial migration of 0.1 cm (sd 0.97 cm)

coming from the geometrically reconstructed original center of rotation. The maximum medial displacement of COR was 1 cm, the maximum lateral displacement was 2.4 cm. The maximum value of cranial migration of COR was 2.5 cm and maximum caudal migration was 1.2 cm.

DISCUSSION

The acetabular reconstruction in RTHA is still a challenging problem. In the last years porous tantalum augments and jumbo cups are more and more used to fill and reconstruct large acetabular defects. Several studies reported good short and midterm results (2,4,12,14,25,29). Porous tantalum seems to provide high primary stability (11,12). Disadvantages of

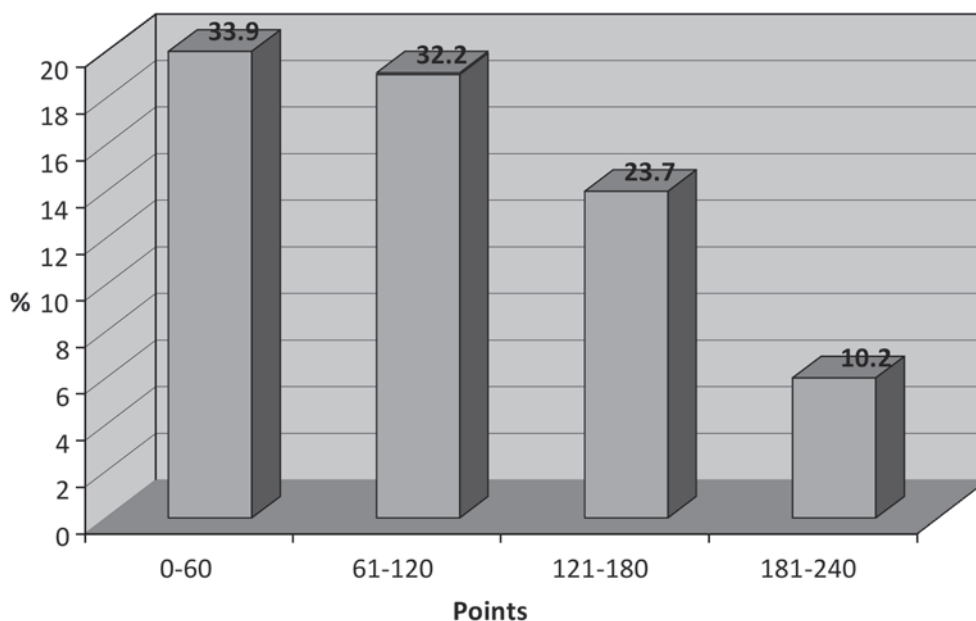


Fig. 3. — Percental distribution of the WOMAC

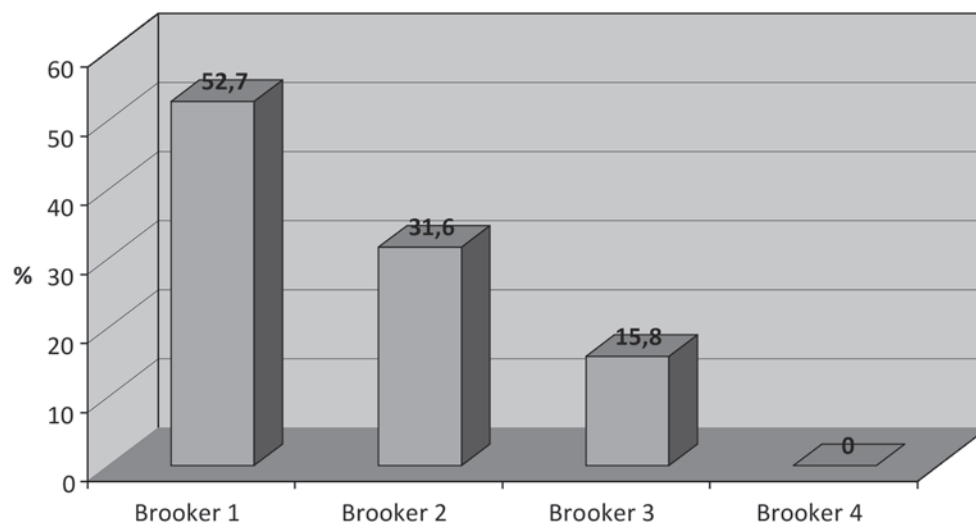


Fig. 4. — Percental distribution of heterotopic ossifications according to Brooker

these implants are proportionally much higher costs in comparison to conventional revision implants like cages or jumbo cups.

The Müller ARR was designed to restore acetabular bone stock in combination with bulky structural or morselized allografts and to allow the cement fixation of the polyethylene cup.

The aim of the present study was to measure the clinical and radiological longterm outcome after acetabular RTHA using the ARR.

Former reviews of midterm to longterm results reported different failure rates for this implant (27). Starker *et al* have shown in this review 11 published studies with an overall failure rate of 11% after

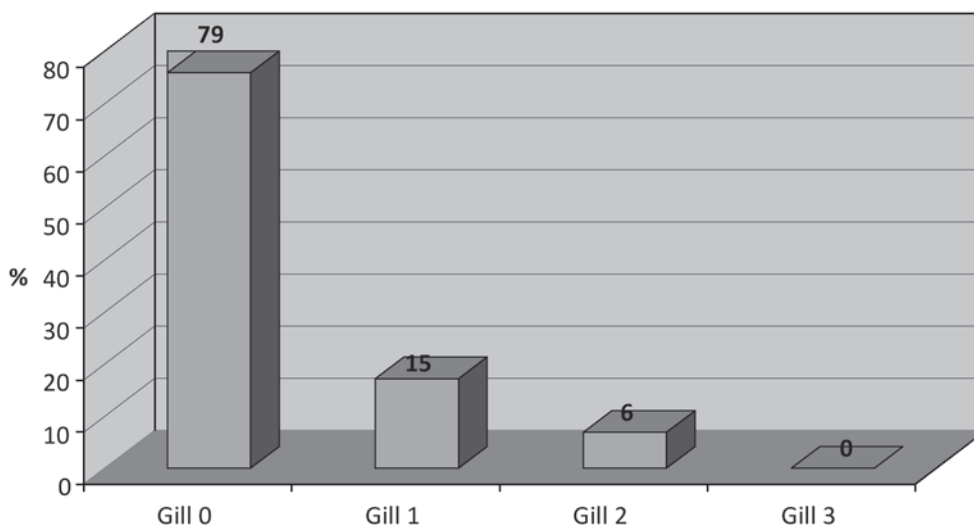


Fig. 5. — Percental distribution of loosening grades according to Gill

6 years. Furthermore in 8% of the cases an acetabular revision had already been performed in the same follow up period (5,8,9,13,16,21,28). Studies with large series of 150 and 141 cases have shown low failure rates of 13% after 7 years and 1% after 5 years. More recent studies with similar follow up periods and comparable case quantity rather confirm loosening rates around 10% (23,24).

Few studies reported longterm results with follow up periods over 10 years. The failure rate in the study from Philippe *et al* was 22.1% after 14 years (18). In our data these higher failure rates were confirmed with 15.7% after 10 years. Similar results were published by Regis *et al* showing a failure rate of 12.5% after 12 years (19).

Overviewing the more recent literature, functional and clinical outcome after acetabular RTHA using acetabular reinforcement rings is poor. Schlegel *et al* reported poor findings with an average HHS of 70 points as well as Philippe *et al* (18,24). The HHS shows a strong correlation between length of follow up time and worsening of the results. Former studies with short to midterm follow up periods demonstrated explicit better outcomes with 87 and 85 points (20,22). In our study the HHS with an average of 58 points was even worse than the recently published outcomes.

In contrast to these findings our data has shown better outcomes for the WOMAC. A mean value of

96 points (0-223) was reached which means in our summary score analysis a “good result”. One explanation of these unexpected results could be a misjudgement of the activities of daily life of the patients coming from a long preoperative period with a very low activity level or immobilization. This could also be the reason for the high rate of “satisfied” or “predominant satisfied” subjective contentment in our study.

The retrospective design and the associated inherent biases and the high drop out rate are weaknesses of this study. In addition outcome scores could be influenced by concomitant morbidities especially in old patients.

While outcome scores show poor results, radiologic analysis and subjective contentment of the patients demonstrate better outcomes. The acetabular RTHA in cases with acetabular defects classified Paprosky 2 using the Müller ARR shows acceptable longterm results. Therefore, this implant can still be regarded as a good option in acetabular revision surgery.

REFERENCES

1. Bellamy N, Kean WF, Buchanan WW *et al*. Double blind randomized controlled trial of sodium meclofenamate (Meclomen) and diclofenac sodium (Voltaren): post validation reapplication of the WOMAC Osteoarthritis Index. *J Rheumatol* 1992 ; 19 : 153-9.

2. **Borland WS, Bhattacharya R, Holland JP et al.** Use of porous trabecular metal augments with impaction bone grafting in management of acetabular bone loss. *Acta Orthop* 2012 ; 83 : 347-52.
3. **Brooker AF, Bowerman JW, Robinson RA et al.** Ectopic ossification following total hip replacement. Incidence and a method of classification. *J Bone Joint Surg Am* 1973 ; 55 : 1629-32.
4. **Davies JH, Laflamme GY, Delisle J et al.** Trabecular metal used for major bone loss in acetabular hip revision. *J Arthroplasty* 2011 ; 26 : 1245-50.
5. **Dihlmann SW, Ochsner PE, Pfister A et al.** [Analysis of migration of screwed acetabular components following revision arthroplasty of the hip joint. Results of single-image roentgen analysis]. *Z Orthop Ihre Grenzgeb* 1994 ; 132 : 286-94.
6. **Eichler J** A reinforcement ring for acetabular revision total hip replacement. *Medizinisch-Orthopädische Technik* 1973 ; 93 : 28-31.
7. **Gill TJ, JB Sledge, Muller ME** The Burch-Schneider antiprotrusion cage in revision total hip arthroplasty : indications, principles and long-term results. *J Bone Joint Surg Br* 1998 ; 80 : 946-53.
8. **Gurtner P, Aebi M, Ganz R** [The acetabular roof cup in revision arthroplasty of the hip]. *Z Orthop Ihre Grenzgeb* 1993 ; 131 : 594-600.
9. **Haentjens P, Handelberg F, Casteleyn PP et al.** The Muller acetabular support ring. A preliminary review of indications and clinical results. *Int Orthop* 1986 ; 10 : 223-30.
10. **Harris WH** Traumatic arthritis of the hip after dislocation and acetabular fractures : treatment by mold arthroplasty. An end-result study using a new method of result evaluation. *J Bone Joint Surg Am* 1969 ; 51 : 737-55.
11. **Hasart O, Perka C, Lehnigk R et al.** [Reconstruction of large acetabular defects using trabecular metal augments]. *Oper Orthop Traumatol* 2010 ; 22 : 268-77.
12. **Joglekar SB, Rose PS, Lewallen DG et al.** Tantalum acetabular cups provide secure fixation in THA after pelvic irradiation at minimum 5-year followup. *Clin Orthop Relat Res* 2012 ; 470 : 3041-7.
13. **Korovessis P, Spastris P, Sdougos G et al.** Acetabular roof reinforcement rings. *Clin Orthop Relat Res* 1992 ; 283 : 149-55.
14. **Kremers HM, Howard JL, Loechler Y et al.** Comparative long-term survivorship of uncemented acetabular components in revision total hip arthroplasty. *J Bone Joint Surg Am* 2012 ; 94 : 82.
15. **Pagnano W, Hanssen AD, Lewallen DG et al.** The effect of superior placement of the acetabular component on the rate of loosening after total hip arthroplasty. *J Bone Joint Surg Am* 1996 ; 78 : 1004-14.
16. **Panski A, Tauber C.** Acetabular supporting ring in total hip replacement. *Arch Orthop Trauma Surg* 1997 ; 116 : 233-5.
17. **Paprosky WG, Perona PG, Lawrence JM.** Acetabular defect classification and surgical reconstruction in revision arthroplasty. A 6-year follow-up evaluation. *J Arthroplasty* 1994 ; 9 : 33-44.
18. **Philippe R, Gosselin O, Sedaghatian J et al.** Acetabular reconstruction using morselized allograft and a reinforcement ring for revision arthroplasty with Paprosky type II and III bone loss : survival analysis of 95 hips after 5 to 13 years. *Orthop Traumatol Surg Res* 2012 ; 98 : 129-37.
19. **Regis D, Magnan B, Sandri A et al.** Long-term results of anti-protrusion cage and massive allografts for the management of periprosthetic acetabular bone loss. *J Arthroplasty* 2008 ; 23 : 826-32.
20. **Rosson J, Schatzker J.** The use of reinforcement rings to reconstruct deficient acetabula. *J Bone Joint Surg Br* 1992 ; 74 : 716-20.
21. **Schatzker J, Glynn MK, Ritter D.** A preliminary review of the Muller acetabular and Burch-Schneider antiprotrusion support rings. *Arch Orthop Trauma Surg* 1984 ; 103 : 5-12.
22. **Schatzker J, Wong MK.** Acetabular revision. The role of rings and cages. *Clin Orthop Relat Res* 1999 ; 369 : 187-97.
23. **Schlegel UJ, Bitsch RG, Pritsch M et al.** [Acetabular reinforcement rings in revision total hip arthroplasty : midterm results in 298 cases]. *Orthopade* 2008 ; 37 : 904, 906-13.
24. **Schlegel, UJ, Bitsch RG, Pritsch M et al.** Mueller reinforcement rings in acetabular revision : outcome in 164 hips followed for 2-17 years. *Acta Orthop* 2006 ; 77 : 234-41.
25. **Sporer SM, Paprosky WG.** The use of a trabecular metal acetabular component and trabecular metal augment for severe acetabular defects. *J Arthroplasty* 2006 ; 21 : 83-6.
26. **Stans AA, Pagnano MW, Shaughnessy WJ et al.** Results of total hip arthroplasty for Crowe Type III developmental hip dysplasia. *Clin Orthop Relat Res* 1998 ; 348 : 149-57.
27. **Starker M, Kandziora F, Jager A et al.** [Acetabular reconstruction using acetabular reinforcement rings]. *Orthopade* 1998 ; : 366-74.
28. **Stockl B, Beerkotte J, Krismer M et al.** Results of the Muller acetabular reinforcement ring in revision arthroplasty. *Arch Orthop Trauma Surg* 1997 ; 116 : 55-9.
29. **Van Kleunen JP, Lee GC, Lementowski PW et al.** Acetabular revisions using trabecular metal cups and augments. *J Arthroplasty* 2009 ; 24 : 64-8.