



## Results of one-stage surgical treatment in children with Tönnis grade 4 developmental dysplasia of the hip: is it worse when it is bilateral?

Kubilay BENG, Timur YILDIRIM, Ilhan A. BAYHAN, Evren AKPINAR, Cagri OZCAN, Mehmet Firat YAGMURLU

*Metin Sabanci Baltalimani Bone Diseases Training and Research Hospital, Turkey*

**This retrospective study compared the results of one-stage surgery of unilateral and bilateral Tönnis grade 4 hips (high dislocation in developmental hip dysplasia, DDH) : 41 hips, 30 patients. Mean follow-up was 56 months. Pelvic radiographs were evaluated at three time points. Acetabular inclination angle improved significantly in both groups. Results were satisfactory (Severin classes I-II) in 13 hips (68.5%) (unilateral group) and 21 hips (89.5%) (bilateral group). Functional evaluation (McKay classification) at final follow-up revealed satisfactory results in 94.8% (unilateral group) and 63.6% (bilateral group). One-stage surgery is a reliable method for treating children with unilateral or bilateral DDH.**

**Keywords :** developmental dysplasia ; hip ; acetabular osteotomy ; hip dysplasia.

### INTRODUCTION

Despite the extensive use of hip ultrasonography as a screening tool in the diagnosis of developmental dysplasia of the hip (DDH), neglected cases are still seen that may remain undiagnosed until walking age (5). Successful treatment is possible with conservative methods in the early term, especially in those diagnosed within the first 6 months of life (7). More extensive surgery is needed with advancing age. Soft tissue contractures, evidence of more

The authors received no financial support for the research, authorship, and/or publication of this article. The authors declared no potential conflicts of interest with respect to the research, authorship, and/or publication of this article.

substantial acetabular dysplasia, and high dislocation of the hip are the main problems in children with late-term DDH (1,7).

One of the leading reasons for encountering high-risk avascular necrosis (AVN) after walking age is the presence of soft tissue contractures (4,7). This risk could be eliminated with soft tissue release and femoral shortening. Inadequate soft tissue release may lead to compression of the femoral head and transient or permanent ischemia (1,5,15). Because of the lack of the stimulant effect of the femoral head, acetabular dysplasia manifests more significantly in children with Tönnis grade 3 and 4 DDH (15). Osteotomy of the pelvis is required to increase coverage of the femoral head and add stability to the hip joint. Successful results have been reported with single-session pelvic osteotomy, open reduction, and femoral shortening in children with DDH diagnosed in the late term (1,5,9,15).

---

■ Kubilay Beng, M.D.  
■ Timur Yildirim  
■ Ilhan A. Bayhan  
■ Evren Akpinar  
■ Cagri Ozcan  
■ Mehmet Firat Yagmurlu  
*Metin Sabanci Baltalimani Bone Diseases Training and Research Hospital, Turkey*  
Correspondence : Kubilay Beng, Metin Sabanci Baltalimani Bone Diseases Training and Research Hospital, Turkey  
E-mail : kubilaybeng@yahoo.com  
© 2016, Acta Orthopaedica Belgica.

---

Bilateral dislocation is another problem encountered in late-term DDH patients. Surgical outcomes are worse in children with bilateral DDH than in those with unilateral DDH (2,14). As far as we know, there is no study in the current literature that reported the results of treating only Tönnis type 4 DDH and compared the results between unilateral and bilateral DDH patients in a similar age group.

In the current study, we tried to answer the question of whether bilateral DDH makes one-stage treatment more difficult in patients with unilateral or bilateral Tönnis grade 4 disease high dislocation of the hip(s).

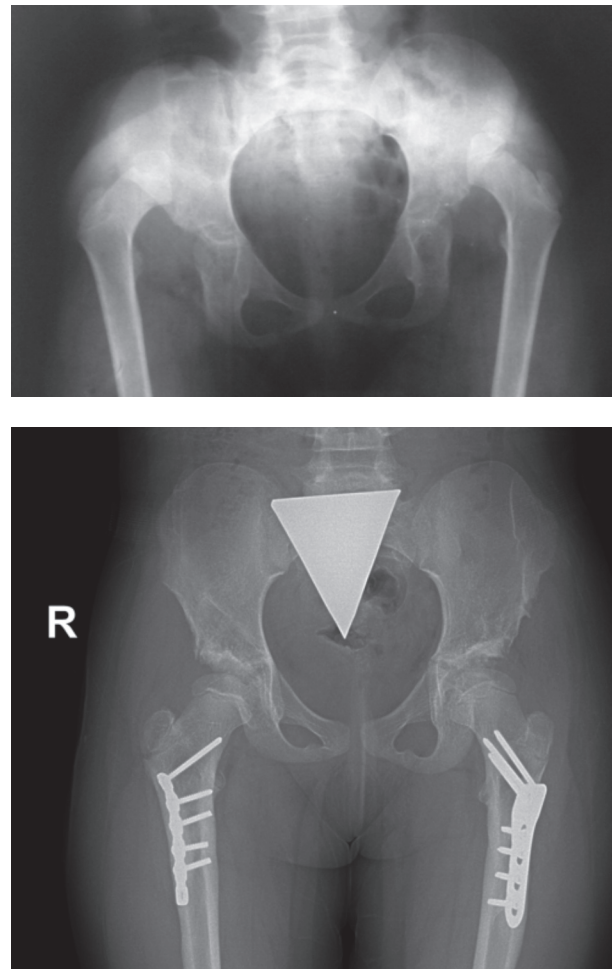
### PATIENTS AND METHODS

The institutional review board of our institution approved the study protocol. Between 2000 and 2012, 30 patients who have Tönnis grade 4 DDH (25 girls, 5 boys) had been treated with one-stage open reduction, lateral acetabular osteotomy, and femoral shortening. 41 hips of this 30 patients were reviewed retrospectively. Age, sex, site of involvement, additional co-morbidities, surgical information, and complications were collected by a chart review. Patients were divided into two groups according to the disease location (bilateral versus unilateral DDH). Children with neuromuscular and chromosomal disorders and those who had undergone closed reduction and surgery previously were excluded.

Preoperative, early postoperative, and final follow-up anteroposterior pelvic radiographs of the patients were assessed. The acetabular inclination (AI) angle was measured on all of the radiographs. The mean percentage of improvement was calculated for each group (preoperative AI – final AI/preoperative AI). At the final follow-up, the center-edge angle (CEA) was measured, and the hips were classified according to the Severin classification system (8). A single orthopedic surgeon (KB) performed all of the angle measurements. The presence of AVN was determined based on the Kalamchi and McEwan classification (4). The patients were further clinically evaluated at the final follow-up by a single surgeon (KB) and were categorized in accordance with McKay's criteria (6).

### Surgical technique

Traction was not applied to any patient before surgery. All patients underwent open reduction, femoral shortening, and lateral acetabular osteotomy (3,11,12,13). The bikini approach was preferred for the incision. Open reduction and capsulorrhaphy were performed distal to the bikini incision and lateral acetabular osteotomy through a proximal point. As pelvic osteotomy was performed prior to femoral shortening, the shortening amount could be optimally determined. Femoral shortening was done



**Fig. 2** — (A) Anteroposterior radiograph of the pelvis of a 76-month-old girl with bilateral, Tönnis grade 4 developmental hip dysplasia. (B) The right hip was operated on at 76 months of age and the left hip at 82 months of age and both hips were operated with one-stage surgery. Follow-up radiograph of the patient at the 55th postoperative month.

Table I. — Patient characteristics

Characteristic		Unilateral		Bilateral		p*
		Mean ± s.d /n- %	Med. (Min-Max)	Mean ± s.d /n- %	Med. (Min-Max)	
Age (month)		61.3 ± 27.1	62 (25 - 132)	63.2 ± 21.5	65 (33 - 106)	0.797
Gender	Girl	14 (73.7%)		11 (100%)		
	Boy	5 (26.3%)		0 (0%)		
F/U (months)		61.2 ± 32.3	62 (24 - 108)	51.6 ± 20.7	54 (24 - 95)	0.257

Independent sample t test / Chi-square test.

s.d: Standart deviation, Med.: Median, Min: Minimum, Max: Maximum, F/U: follow-up

via a separate lateral incision. The first osteotomy was performed in the subtrochanteric region. The hip was placed in the acetabulum, and shortening was finalized by osteotomy of the overriding shaft length. Fixation at the osteotomy site was performed using 3.5-mm 4-5 perforated plates (Fig. 2a and b).

### Postoperative care

A hip spica cast was applied at 20-60° of flexion, 30-60° of abduction, and 15° of internal rotation for 6 weeks postoperatively. Following removal of the cast at the sixth week, a Denis Browne abduction brace was applied. This brace was removed 4 weeks later.

### Statistical analysis

The means, standard deviations, medians, and minimum and maximum values were used in descriptive statistics of the data. Data distribution was checked with the Kolmogorov-Smirnov test. Quantitative data were analyzed with the independent samples t-test. The repeated measures were analyzed with the paired samples t-test and qualitative data with the  $\chi^2$  test. Statistical analyses were done using the SPSS version 20.0 software (SPSS, Chicago, IL, USA).

## RESULTS

### Demographics

Altogether, 19 patients had unilateral hip involvement (11 right, 8 left), and 11 had bilateral hip involvement. The mean follow-up period was

56 months (range 24-108 months). No statistically significant difference was found between the ages and follow-up period parameters of the groups in the demographics analysis ( $P>0.05$ ). The unilateral hip group consisted of 14 girls and 5 boys. The bilateral hip group consisted of 11 girls and no boys (Table I).

### Radiology

The mean acetabular inclination (AI) angle in the unilateral hip group was  $44.9^\circ \pm 7.7^\circ$  preoperatively and  $19.4^\circ \pm 5.2^\circ$  on the early postoperative radiographs. The mean AI angle in the bilateral hip group was  $40.3^\circ \pm 8.2^\circ$  preoperatively and  $17.0^\circ \pm 4.9^\circ$  on the early postoperative radiographs. Compared with the preoperative values, the early postoperative and final follow-up AI angles improved significantly in both groups ( $p<0.05$ ). Although the mean AI angle of the unilateral hip group at the final follow-up was significantly higher than that of the bilateral group ( $p<0.05$ ), the mean percentage of AI improvement was higher in the unilateral group (Fig. 1, Table II).

The mean CEA was measured as  $27.0^\circ \pm 10.6^\circ$  in the unilateral group and  $29.0^\circ \pm 7.6^\circ$  in the bilateral group. Satisfactory results (Severin classes Ia, Ib, II) were achieved in 13 hips (68.5%) in the unilateral group and in 21 hips (89.5%) in the bilateral group. The number of patients with Severin class III (fair) results in the unilateral group was significantly higher than in the bilateral hip group: 6 (31.5%) vs. 1 (4.5%) hip ( $P=0.004$ ). No poor results (Severin classes IV-VI) were noted in either group.

AVN was observed in 8 of 19 (42.1%) hips in the unilateral group and in 15 of 22 (68.1%) hips in the bilateral group. There was no statistically

Table II. — Acetabular inclination measurements

	Unilateral hip group (°)		Bilateral hip group (°)		p*
	Mean.±s.d	Med. (Min-Max)	Mean.±s.d	Med. (Min-Max)	
Preop AI	44.9 ± 7.7	43 (31-60)	40.3 ± 8.2	40 (31-60)	
Early Postop AI	19.4 ± 5.2	20 (10-27)	17 ± 4.9	17 (9-29)	
Last Follow up AI	17.5 ± 5.2	19 (7-26)	14 ± 4.8	15 (4-23)	0.034
Mean Percentage of AI Improvements	61.0 ± 6.8	60 (45-71)	56.0 ± 7.6	57 (45-71)	0.045

Independent sample t test/ paired sample t test

AI: acetabular inclination angle, s.d: standart deviation, Med.: Median, Min: Minimum, Max: Maximum

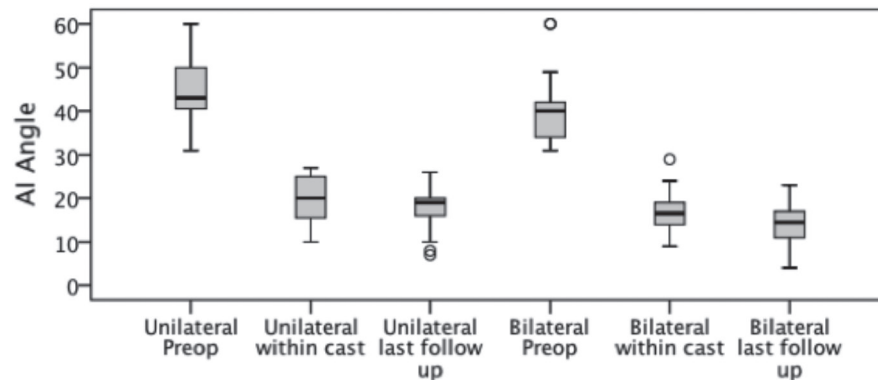


Fig. 2 — Acetabular inclination (AI) distribution.

significant difference in AVN rates between the two groups ( $P=0.115$ ) (Table III).

### Clinical outcomes

According to the McKay classification, functional evaluation at the final follow-up revealed satisfactory results (class I-II) in 18 of 19 (94.8%) hips in the unilateral group and 14 of 22 (63.6%) hips in the bilateral group. There were significantly more patients with McKay class III-IV results in the bilateral group than in the unilateral group ( $P=0.016$ ).

No early postoperative redislocation or triradiate cartilage closure was observed in any patient. In one case, one of the grafts of the acetabular osteotomy site was found to be dislocated on early postoperative radiographs. Although a second graft was fixing the osteotomy site, revision surgery was done.

### DISCUSSION

The objective in the treatment of DDH is to achieve a painless, stable hip with no gait pathology or limitation. The hip should be reduced concentrically to achieve this objective. Bilateral dislocation makes the disorder more challenging among late-term DDH patients. In this study, we evaluated the results of one-stage treatment for high dislocation with DDH in patients with unilateral versus bilateral hip dislocation. We tried to answer the question of whether patients with bilateral dislocation had worse outcomes.

The Severin classification is the most widely used index for evaluating radiology results in patients with DDH. Vallamshetta et al. reported satisfactory results in all of their unilateral and bilateral DDH patients treated with lateral acetabular osteotomy

as a means to accomplish pelvic osteotomy (13). Wang et al. did not observe a significant difference between unilateral and bilateral hip patients and reported a high rate of satisfactory results (14). In our study, there were significantly more Severin class 3 (fair) patients (six patients, 31.5%) in the unilateral hip group than in the bilateral hip group. Upon examination of these six patients, we detected severe dysplasia (AI angle 60°) in three cases and inadequate correction of the AI angle in three cases. No poor results were observed in either group.

Green and Drennan reported a higher incidence of AVN in unilateral hip patients (2). Subasi et al. found AVN in 12 of 22 (54.5%) hips in patients with bilateral DDH and 18 of 29 (62%) hips in patients with unilateral DDH (10). In a study by Wang et al., 38% of AVN was observed in patients with unilateral DDH, and 55% of AVN was observed in patients with bilateral DDH (14). Likewise, we noticed a higher incidence of AVN in the bilateral group, but found no statistically significant difference between the two groups. As noted in the abovementioned studies, different results are found when assessing unilateral and bilateral cases.

Despite the higher rate of AVN occurrence in the bilateral hip group, Wang et al. suggested that the Tönnis grade, age at the time of surgery and long follow-up were the main risk factors according to their multiple logistic regression analysis (14).

Although several scoring methods for evaluating clinical outcomes are available in the literature, the one most widely used is the McKay scoring system (1,7,9,10). McKay scores are evaluated according to age in the literature. Based on this scoring system, Karakaş et al. reported satisfactory results in 72.3% of the patients aged 4-7 years and in 57.9% of patients aged 8-17 years (5). Yağmurlu et al. had satisfactory results in 77.8% of patients <8 years of age and in 33.3% of patients >8 years of age (15). In the study by Wang et al., McKay scores were compared between unilateral and bilateral hip patients. Satisfactory scores were achieved in 71% of the patients with unilateral DDH and in 46% of the patients with bilateral DDH (14). We had satisfactory results in 94.8% of the patients in the unilateral group and 63.6% of the patients in the bilateral group. Similar to our study, fair and poor

Table III. — Compare of unilateral and bilateral groups last follow up

		Unilateral		Bilateral		p*
		Mean ± s.d / n-%	Med. (Min-Max)	Mean ± s.d / n-%	Med. (Min-Max)	
CEA		27,0 ± 10,6	25 (12-56)	29,0 ± 7,6	28 (13-43)	0,480
MacKay Score	Excellent	9 47,4%		7 31,8%		0,016
	Good	9 47,4%		7 31,8%		
	Fair	1 5,2%		7 31,8%		
	Poor	0 0%		1 4,5%		
Severin Classification	IA	8 42,2%		10 45,4%		0,004
	IB	3 15,8%		4 18,2%		
	II	2 10,5%		7 31,9%		
	III	6 31,5%		1 4,5%		
	IV, V, VI	0 0%		0 0%		
Kalamchi Classification	AVN Absent	11 57,9%		7 31,8%		0,115
	I	3 15,8%		5 22,7%		
	II	4 21,1%		5 22,7%		
	III	1 5,3%		4 18,2%		
	IV	0 0%		1 4,5%		

Independent sample t test / Chi square test

s.d : Standart deviation, Med. : Median, Min : Minimum, Max : Maximum

results were found significantly more often in the bilateral group, in accordance with the literature.

Clinical and radiologic results showed some inconsistency when evaluated together. We found that this situation is due to the fact that there are more Severin class 3 cases in the unilateral group. Clinical examination of these cases revealed no Trendelenburg sign, and the patients had McKay clinical scores of 1-2. When Severin type 3 hips (defined as acetabular dysplasia without femoral head subluxation) (8) are taken into account, the absence of the Trendelenburg sign in the unilateral group is not unexpected. In the study where Kalamchi and McEwen described their classification, they showed a correlation between functional results and AVN. They mentioned that when the AVN grade and severity increased, the functional scores got worse because of osteoarthritis. Although we could not find a statistical significance, the AVN rate was higher in the bilateral hip group, which also included more type III and IV AVN cases (4). This was similar to the results of the Kalamchi and McEwen study, which showed worse McKay scores in the bilateral hip group. Wang et al mentioned that having bilateral DDH is not a risk factor for AVN, but they found that the McKay scores worsened with age progression and having bilateral DDH. We found that low McKay scores in the bilateral group, with statistical significance, are similar to those in the literature.

Although the selection of a small group of patients with Tönnis grade 4 hip may be considered a limitation of this study, our study is different from previous studies because it investigated the efficacy of an uniform treatment method in patients with Tönnis grade 4 hip involvement (1,2,5,7,9,10,14).

## CONCLUSION

It is well known that the treatment outcomes of DDH worsen with age progression. In our study we tried to evaluate the one-stage treatment outcomes of late-diagnosed, high dislocated hips between patients with unilateral versus bilateral DDH. Our results showed the worst radiologic scores in the unilateral hip dislocation group and similar AVN rates in the two groups. We believe that having bi-

lateral hip dislocation does not affect the outcome of one-stage surgical treatment of DDH. One-stage treatment is still a reasonable surgical option for the treatment of DDH in hips with high dislocation, regardless of whether it is unilateral or bilateral DDH.

## REFERENCES

1. Galpin RD, Roach JW, Wenger DR, Herring JA, Birch JG. One-stage treatment of congenital dislocation of the hip in older children, including femoral shortening. *The Journal of bone and joint surgery American volume* 1989, 71(5) : 734-741.
2. Greene WB, Drennan JC. A comparative study of bilateral versus unilateral congenital dislocation of the hip. *Clinical orthopaedics and related research* 1982 (162) : 78-86.
3. Gunel U, Daglar B, Tasbas BA, Delialioğlu O, Bayraktar K. Results of Tönnis-type acetabuloplasty in patients with developmental hip dysplasia. *J Orthop Sci* 2012, 17(6) : 705-709.
4. Kalamchi A, MacEwen GD. Avascular necrosis following treatment of congenital dislocation of the hip. *The Journal of bone and joint surgery American volume* 1980, 62(6) : 876-888.
5. Karakas ES, Baktir A, Argun M, Turk CY. One-stage treatment of congenital dislocation of the hip in older children. *J Pediatr Orthop* 1995 ; 15 : 330-336.
6. McKay DW. A comparison of the innominate and the pericapsular osteotomy in the treatment of congenital dislocation of the hip. *Clinical orthopaedics and related research* 1974(98) : 124-132.
7. Ryan MG, Johnson LO, Quanbeck DS, Minkowitz B. One-stage treatment of congenital dislocation of the hip in children three to ten years old. Functional and radiographic results. *The Journal of bone and joint surgery American volume* 1998, 80(3) : 336-344.
8. Severin E. Congenital dislocation of the hip; development of the joint after closed reduction. *The Journal of bone and joint surgery American volume* 1950, 32-A(3) : 507-518.
9. Shih CH, Shih HN. One-stage combined operation of congenital dislocation of the hips in older children. *Journal of pediatric orthopedics* 1988, 8(5) : 535-539.
10. Subasi M, Arslan H, Cebesoy O, Buyukbebeci O, Kapukaya A. Outcome in unilateral or bilateral DDH treated with one-stage combined procedure. *Clinical orthopaedics and related research* 2008, 466(4) : 830-836.
11. Tönnis DBK, Heinecke A. Lateral Acetabular Osteotomy. *Journal of Pediatric Orthopaedics Part B* 1994(3) : 40-46.
12. Tönnis D. In: Congenital Hip Dislocation. *New York: Thieme-Stratton*; 1982.
13. Vallamshetla VR, Mughal E, O'Hara JN. Congenital dislocation of the hip. A re-appraisal of the upper age limit for treatment. *J Bone Joint Surg Br* 2006, 88(8) : 1076-1081.

14. Wang TM, Wu KW, Shih SF, Huang SC, Kuo KN. Outcomes of open reduction for developmental dysplasia of the hip: does bilateral dysplasia have a poorer outcome? *The Journal of bone and joint surgery American* volume 2013, 95(12) : 1081-1086.
15. Yagmurlu MF, Bayhan IA, Tuhanioglu U, Kilinc AS, Karakas ES. Clinical and radiological outcomes are correlated with the age of the child in single-stage surgical treatment of developmental dysplasia of the hip. *Acta orthopaedica Belgica* 2013, 79(2) : 159-165.