



Short-term outcome trapeziectomy with ligament reconstruction and tendon interposition versus trapeziometacarpal prosthesis : a literature review

Karen VERHULST, Jan DAUWE, Maarten VAN NUFFEL, Luc DE SMET

From the Department of Orthopaedic Surgery, University Hospitals Leuven, Belgium

Trapeziectomy with ligament reconstruction and tendon interposition and trapeziometacarpal prosthesis are two commonly used procedures for first carpometacarpal joint osteoarthritis. The purpose of this study is to compare the short-term outcome of trapeziectomy with ligament reconstruction and tendon interposition to trapeziometacarpal prosthesis. Pubmed, Cochrane library and science direct database were searched with adequate search terms. Used parameters were force, pain, mobility, functionality and complication. All papers describing short-term outcome of ligament reconstruction and tendon interposition or trapeziometacarpal prosthesis were included in this review. Trapeziometacarpal prostheses showed faster pain relief compared with trapeziectomy and ligament reconstruction and tendon interposition. Overall, there was a better strength in the trapeziometacarpal prosthesis group. A lack of information was found about the short-term functionality. The mobility recovers faster in the prosthesis group, although different scoring scales were used for measurement. We could confirm the faster pain relief in the prosthesis group and generally a faster recovery of strength and mobility. In the prosthesis group were more short-term complications. More studies are required to evaluate the short-term recovery of strength, the mobility, functionality and satisfaction.

Keywords : Trapeziometacarpal prosthesis ; LRTI.

INTRODUCTION

Osteoarthritis of the base of the thumb is a common disease and it affects up to 25% of postmenopausal women. Twenty-five percent of the postmenopausal women have radiological osteoarthritis of the base of the thumb and 33% of these women had basal thumb pain (2,3). Trapeziometacarpal (TMC) osteoarthritis can cause weakness, stiffness, instability of the joint, severe pain and impaired force. Most of the patients can be treated conservatively. Conservative treatment consists of injections with cortisone or hyaluronate, analgesics, patient education, strengthening exercises, assistive devices and orthosis (31). If the targeted pain relief is not achieved after at least three months of conservative treatment or if the conservative treatment fails, surgical management is indicated (15). Several surgical options have been described, such as metacarpal osteotomy, carpometacarpal arthrodesis, carpometacarpal pros-

-
- Karen Verhulst, MD
 - Jan Dauwe, MD
 - Maarten Van Nuffel, Consultant Orthopaedic Surgeon
 - Luc De Smet, Professor in Orthopaedic Surgery
Department of Hand surgery, University Hospitals Leuven, Pellenberg, Belgium.
- Correspondence : Jan Dauwe, University Hospitals Leuven, Pellenberg, Belgium. Tel : 0032 16 33 22 11.
E-mail : dauwejan@gmail.com
© 2020, Acta Orthopædica Belgica.
-

*No benefits or funds were received in support of this study.
The authors report no conflict of interests.*

Acta Orthopædica Belgica, Vol. 86 - 1 - 2020

thesis, volar ligament reconstruction, trapeziectomy alone, trapeziectomy in combination with tendon interposition (TI), ligament reconstruction (LR) or ligament reconstruction and tendon interposition (LRTI) (35).

LRTI (Fig. 1) and prostheses (Fig. 2) are two commonly used procedures. De Smet et al (13) found no difference between both techniques regarding pain, satisfaction and function at long-term follow-up. Prostheses have a high long-term complication rate, including aseptic loosening, subluxation, dislocation, infection and periprosthetic fracture. Implant loosening and dislocation were found to be the two main long-term complications (21). The De Smet et al study (12) shows radiological loosening in 44% in a 24 months follow-up. Loosening of the prostheses does not necessarily correlate with clinical failure or pain. Younger patients have more loosening of the prostheses in comparison with older patients (9,12,33).

The question remains whether prostheses do have an advantage in short-term in comparison with LRTI, known that prosthesis do have greater complication rates, and the same outcome for pain, satisfaction and functionality on long term. Ulrich-Vinther et al (32) proved an earlier recovery of function with a prosthesis in comparison with trapeziectomy and LRTI. No difference in complication rate was found between the two groups. A second study, Jager et al (24), compared TMC prosthesis with trapeziectomy plus a synthetic implant. This study confirms the earlier recovery of function with a prosthesis.

In this review, we evaluated whether other studies confirm the findings of Ulrich-Vinther et al. (32).

MATERIALS AND METHODS

Pubmed, the Cochrane library and science direct database were searched with following search terms: thumb base osteoarthritis, LRTI, trapeziectomy, trapeziometacarpal osteoarthritis, surgical management, trapeziometacarpal arthrosis, rhizarthrosis, joint prosthesis, thumb arthroplasty, short term outcome. Used parameters were force, pain, mobility, functionality and complication. The articles were selected by containing information about the short-term outcome (3-6 months) of

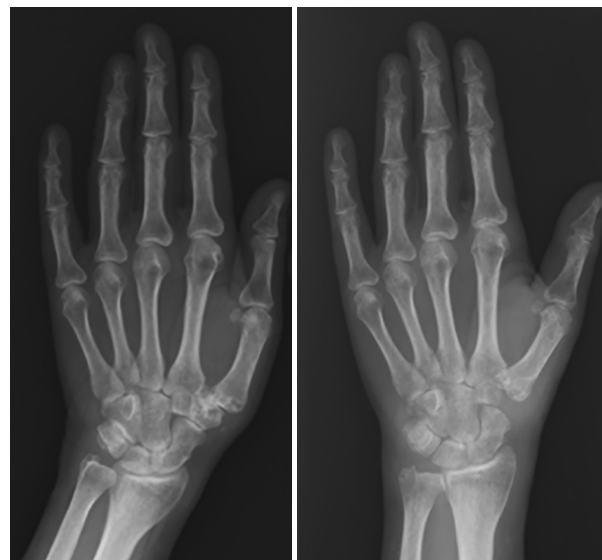

Fig. 1. — Trapeziectomy with LRTI.
Left : preoperative. Right : postoperative.

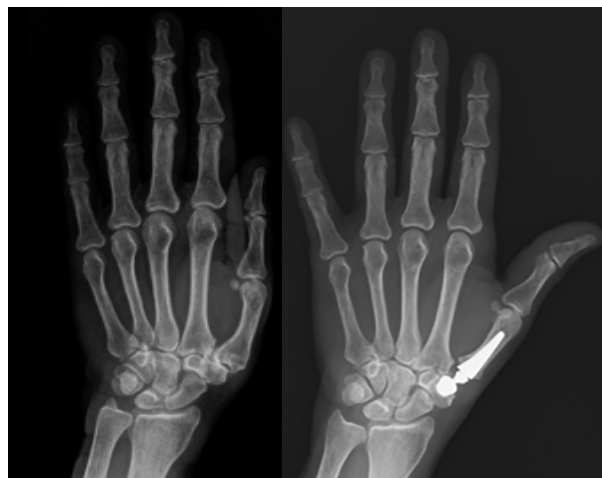

Fig. 2. — Carpometacarpal (CMC) I Prosthesis, type Ivory.
Left : preoperative. Right : postoperative.

LRTI or TMC prosthesis. We obtained one study (32) comparing those two techniques at short-term follow-up. The other studies presented short-term outcome of only one procedure. One case series (1) reported short-term functionality of LRTI. An overview of included articles can in shown in table I.

Table I. — Overview of included articles

	Sat ^o	Str ^o	P ^o	F ^o	Mob ^o	C ^o	Sat ^o	Str ^o	P ^o	F ^o	Mob ^o	C ^o
Jager et al (24)	X	X	X	X	X	X						
Hansen et al 2013 (20)		X	X	X		X						
Hansen et al 2016 (18)		X	X	X		X						
Ulrich-Vinther et al (32)		X	X		X	X		X	X		X	X
Davis et al (2004) (11)								X	X			
Davis et al (1997) (10)								X	X			
August et al (4)			X									
Abbas et al (2012) (1)										X		
Brutus et al (7)						X						
Martin Ferrero et al (27)						X						
Vander Eecken et al (34)						X						
Van Capelle et al (33)						X						
Goubau et al (16)						X						
Bricout et al (6)						X						
Hansen et al (2008) (19)						X						
Lemoine et al (26)						X						
Jacoulet et al (23)												
Belcher and Nicholl (5)												X
Langenhan et al (25)												X
Burton and Pellegrini (8)												X
Garcia-Mass et al (14)												X
Werthel et al (37)												X
Raven et al (30)												X

^o Sat = Satisfaction ; Str^o = Strength ; P^o = Pain ; F^o = Functionality ; Mob^o = Mobility ; C^o = Complications.

RESULTS

Only a small amount of evidence was found in current literature reporting on short-term outcome regarding force, satisfaction, pain, functionality or mobility. Several studies reported short-term complications.

Satisfaction (Fig. 3)

Jager et al (24) compared total trapeziometacarpal prosthesis and trapeziectomy-interposition with a synthetic implant in two similar groups of female patients to determine which procedure lead to the shortest recovery. Forty-seven patients were treated by trapeziometacarpal joint prosthesis and 27 patients were treated by trapeziectomy-interposition. The satisfaction was measured in each domain (pain, mobility, force, esthetics) at six months. The results are shown in Fig. 3. Overall, patients with the trapeziometacarpal prosthesis were

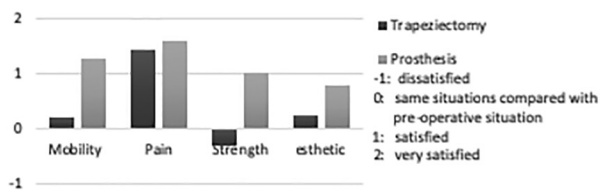


Fig. 3. — Satisfaction 6 months after surgery (24)

more satisfied in comparison with the trapeziectomy with synthetic implant interposition at six months.

There were no studies found reporting short-term satisfaction of trapeziectomy with LRTI.

Pain (Fig. 4, 5)

Three studies (10,11,32) presented the evolution of pain in the LRTI group. Five studies (4,18,20,24,32) ligament reconstruction, spacer implantation, etc. reported short-term pain evolution in the prosthesis group. Four studies (18,20,24,32) used the VAS-score

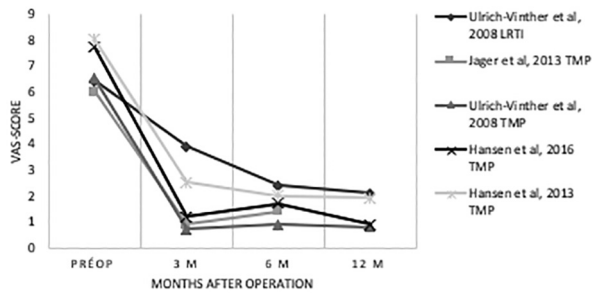


Fig. 4. — Summary pain

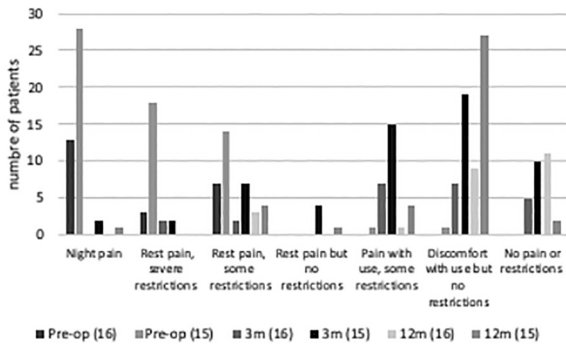


Fig. 5. — Summary pain (Davis et al, 1997 (10) ; Davis et al, 2004 (11))

(Visual Analog Scale) to determine the pain. Two studies (10,11) did not use this scoring scale.

Ulrich-Vinther et al. compared the two procedures and found a faster pain relief in the prosthesis group (Fig. 4). Three studies (18,20,24) confirmed that patients with prosthesis reached the maximum pain reduction after three months (Fig. 4). Two studies (10,11) confirmed the fact that the maximum pain reduction with trapeziectomy and LRTI is not reached after three months (Fig. 5).

Functionality

Three studies contained data of short-term functionality of the prosthesis group (18,20,24). Only one report of case series (1) had some short-term data of functionality of LTRI. The Jager et al study used the Moineau’s prehension score (29) to evaluate the functionality over time. This score is a simplified version of the DASH score (22), used in both studies of Hansen (18,20) and the case series of Abbas et al (1). At three months, there was an

increased functionality in patients with a prosthesis in the Jager et al study, which was confirmed by the studies of Hansen. In the case series of Abbas et al, there was an increased functionality at three and six months compared to the preoperative phase in the LRTI group.

More data is required about the short-term functionality of trapeziectomy with LRTI.

Strength

Preoperative and short-term postoperative strength was measured in multiple studies (10,11,18,20,25,32). Hand-grip, key-pinch and tip-pinch strength were measured in all studies, except two studies (18,20) who solely recorded grip strength. Three studies (10,11,32) used the same dynamometer (Jamar Hand dynamometer) to determine the grip strength. Both studies of Davis (10,11) used the same dynamometer (Jamar Hand dynamometer) to determine the thumb key-pinch and tip-pinch strength. The key-pinch and tip-pinch strength in the Ulrich-Vinther study were determined by a goniometer (North Coast Medical). Hansen et al (20) and Jager et al (24) did not specify the device they used to measure the strength.

In the Ulrich-Vinther study (32) the patients with trapeziectomy and LRTI achieved less strength compared to those patients with trapeziometacarpal joint prostheses at all postoperative visits. Three months, six months and one year postoperatively, the prosthesis group had an increased tip-pinch, key-pinch and hand-grip pressure in comparison with preoperatively. In contrast to the patients with trapeziometacarpal prosthesis, patients with trapeziectomy and LRTI had a decreased tip-pinch and key-pinch pressure at all postoperative visits. The hand-grip pressure in the LRTI group was slightly decreased at three months postoperative compared with preoperatively, but six months and twelve months after surgery the hand-grip pressure was higher compared with preoperatively.

Hand-grip strength (Fig. 6)

Both studies of Davis (10,11) did not confirm the findings of Ulrich-Vinther about the hand-grip strength at three months. In contrast to the three months decreased hand-grip strength of the Ulrich-

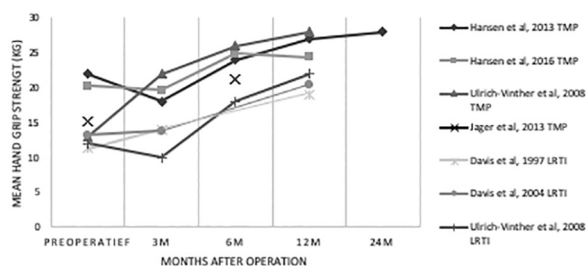


Fig. 6. — Summary hand grip strength

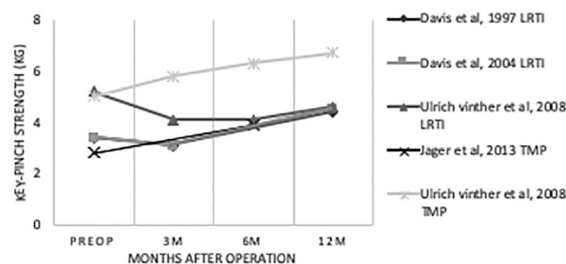


Fig. 7. — Summary key-pinch strength

Vinther study, in these two studies they found a stable or slightly increased hand-grip strength in the LRTI group at three months. Both studies of Davis (10,11) did confirm the findings of Ulrich-Vinther about the increased hand-grip strength one year postoperative.

Both studies of Hansen (18,20) did not confirm the findings of Ulrich-Vinther about the hand-grip strength of trapeziometacarpal prosthesis three months postoperatively. They showed a decreased hand-grip strength at three months postoperatively and an increased hand-grip strength after six months and one year postoperatively. The studies of Hansen (18,20) did confirm the 6 months postoperative increased hand-grip strength. The study of Jager (24) confirmed the increased force six months postoperatively.

Overall, all the studies found an increased hand-grip strength six and twelve months postoperative. The TMP had an increased hand-grip strength at three months postoperatively. We cannot draw any definitive conclusion about the three months postoperative strength in the LRTI group, given the contradictory findings.

Key-pinch strength (Fig. 7)

Two studies of Davis (10,11) did not completely confirm the findings of Ulrich-Vinther (32) about the key-pinch strength of the LRTI procedure. These studies contained information of three months and one year postoperatively and they both showed a minimal decreased key pinch strength three months after surgery, but an increased key-pinch strength one year postoperatively. The Ulrich-Vinther (32) showed a decreased key-pinch grip one year postoperatively.

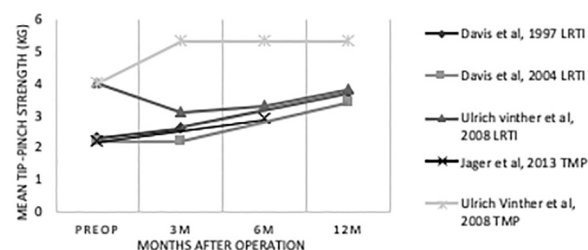


Fig. 8. — Summary Tip-pinch strength

To our knowledge, we were unable to find other evidence about the key-pinch strength three months postoperatively in the prosthesis group than the Ulrich-Vinther study (32). Jager et al (24) confirmed the increased key-pinch strength six months postoperatively.

Tip-pinch strength (Fig. 8)

The Davis et al studies (10,11) showed a stable or slightly increased tip-pinch strength three months postoperative in the LRTI group and one year postoperative there was clearly an increased tip-pinch strength. The Ulrich-Vinther study (32) showed a decreased tip-pinch strength at three months and after one year.

We could not find much information about the three months postoperative tip-pinch strength in the prosthesis group. Jager et al (24) confirmed the increased tip-pinch strength six months postoperative.

Mobility

Ulrich-Vinther et al (32) measured the mobility of the thumb three months, six months and one year after surgery and Jager et al (24) measured the

mobility of the thumb six months after surgery. Both studies used another technique to measure the mobility. Ulrich-Vinther used a goniometer to measure the flexion/extension and abduction/adduction. The thumb opposition was measured by determining the minimal distance of the pulp of the thumb and the palm at the base of the little finger by active motion. Jager et al used the Kapandji score to measure the opposition and retropulsion. Abduction was measured by the angle between MCPI-III, and for antepulsion, the angle between MCPI-II was measured. These two studies are difficult to compare because of the different measurements that are used. Only opposition and abduction were measured in the two studies. Ulrich-Vinther showed an increased opposition in the prosthesis and LRTI group three, six and twelve months. The prosthesis group showed a larger increase of opposition in comparison with the LRTI group. Whereas, Jager et al. found a slightly increased opposition, retropulsion, antepulsion and abduction in the prosthesis group at six months postoperative.

More data are needed to compare the short-term evolution of mobility between the prosthesis and LRTI group.

Complications

After literature search, several short-term complications were found. A detailed summary of the complications is enlisted in table II.

Most common complications were complex regional pain syndrome (CRPS), tenosynovitis and dysesthesia of the radial nerve (table II). CRPS equally occurred in the LRTI and prosthesis group. Tenosynovitis occurred more in the prosthesis group. De Quervain's tenosynovitis and tenosynovitis of the flexor carpi radialis muscle was described in the prosthesis group. Dysesthesia of the radial nerve was more common in the LRTI group.

Some complications only occurred in one of the two procedures. In the LRTI group, scar pain did occur in 2,7%-8% of the patients. In the prosthesis group, dislocation, peroperative trapezium fracture and aseptic loosening of the cup occurred. Scar pain in the prosthesis group was not reported. In the group of patients with dislocation or aseptic loosening of the cup, 50% of them needed revision of the prosthesis. Van Cappelle et al (33) found a higher revision rate in men and young women and not all the patients with loosening were symptomatic.

Table II. — Summary of complications

	Prosthesis		LRTI	
Scar pain			2,7% - 8,0%	(8,14,25)
CRPS	2,3 - 4,5%	(6,16,26,34)	1,8-5,9%	(8,14,30,37)
De Quervain tenosynovitis FCR Tenosynovitis	5,6 - 15% (DQ + FCR)	(6,32,33)	7,2% (DQ)	(33)
Dysesthesia				
- Terminal branches radial nerve	- 1,6 - 4,5%	(6,7,9,16)	- 23,5%	(30)
- Palmar cutaneous branch of the median nerve			- 2,7%	(14)
- Musculocutaneous nerve			- 1,8%	(14)
Tendon rupture FCR			1-2%	(5,33)
Dislocation	1,3-9,5%	(6,7,9,27,34)		
Peri-operative trapezium fracture	2,3 - 5,9%	(19,27,34)		
Aseptic loosening cup	1,3 - 4,8%	(7,9,20)		
Traumatic fracture/dislocation	1,7 - 3,7 %	(1,6,23,33)		
Intra-operative cementing failure	1,4-3,7%	(1,20)		
Secondary tendon rupture EPL	1,2%	(26)		
Peroperative tendon rupture EPB	1,3%	(9)		
Periprosthetic infection/allergy	1,3%	(6)		

CRPS = complex regional pain syndrome, FCR = flexor carpi radialis, EPL = extensor pollicis longus, EPB = extensor pollicis brevis.

DISCUSSION

The systematic review of Wajon et al (36) compared trapeziectomy with ligament reconstruction and tendon interposition (LRTI), trapeziectomy with ligament reconstruction, trapeziectomy with interpositional arthroplasty (IA), trapeziectomy, Artelon joint resurfacing, arthrodesis and Swanson joint replacement. No technique superior to another in the treatment of trapeziometacarpal arthritis was found in terms of physical function, patient global assessment, treatment failure, trapeziometacarpal joint imaging, adverse events, quality of life, physical function or pain in long-term follow-up. Trapeziectomy is the golden standard for surgical treatment of trapeziometacarpal arthritis (35).

Regarding long-term follow-up, trapeziometacarpal prosthesis does not give better results than trapeziectomy in the treatment of trapeziometacarpal joint osteoarthritis (21). LRTI and prosthesis are two commonly used procedures. De Smet et al (13) found no difference between both techniques for pain, satisfaction and function at long-term follow-up. Trapeziometacarpal prostheses are known to have more long-term complications inherent to prosthesis, including aseptic loosening, subluxation and dislocation and periprosthetic fracture. Infection is a rare complication in hand surgery (6). Failure rate up to 42% is described (21).

The question remains whether prostheses do have an advantage in short-term in comparison with LRTI, known that prosthesis do have greater complication rates, and the same outcome for pain, satisfaction and functionality on long-term follow-up. One study proved an earlier recovery of function with a prosthesis in comparison with trapeziectomy (32). This study found no difference in complication rate was found between the two groups. Jager et al (24) compared the prosthesis with a trapeziectomy plus synthetic implant. This study showed an earlier recovery of function with prosthesis, faster pain relief, better strength and a greater satisfaction in the prosthesis group six months after surgery. The studies of Davis et al (10,11) and Belcher, and Nichol et al (5) could not find any difference in outcome at short term between trapeziectomy alone, with

tendon interposition or with tendon interposition and ligament reconstruction.

This review showed a faster pain relief in the prosthesis group. After three months, the maximum pain reduction in the prosthesis group was achieved. In the LRTI group, there was still some relief in pain after six months. To evaluate the functionality at short-term, more research is needed. Only one case series contained information about the functionality three and six months postoperative after LRTI procedure and three studies contained information about the short-term functionality of prosthesis. There was no consensus about the hand-grip strength three months postoperatively after trapeziectomy with LRTI and prosthesis. Hand-grip strength six months after prosthesis and LRTI were both increased. More data are needed about the short-term key-pinch and tip-pinch strength. The mobility was measured in several studies. Since different scoring scales were used for evaluation, a comparison is difficult to perform. Complications inherent to prosthesis were relative frequent, including dislocation, perioperative trapezium fracture and aseptic loosening. Scar pain was only reported in the LRTI group. CRPS was equally seen in both groups. Tenosynovitis was more frequent by patients with prosthesis and dysesthesia of the radial nerve was more present in the LRTI group.

De Quervain's tenosynovitis was seen when the patients used their hand, mostly after three months. After arthroplasty, there was an increased scaphometacarpal index which caused tension on the tendon which may explain the tenosynovitis (6). Goubau et al (17) suggested that lengthening of the thumb after prosthesis did not cause de Quervain's tenosynovitis. Flexor carpi radialis tenosynovitis occurred later and may be triggered by adhesion of the tendon to residual bone fragments after surgery (28).

The current study contains several weaknesses. It was difficult to compare the results of the studies because of the use of variety of assessment parameters. There were only a few studies presenting detailed information on short-term outcome.

CONCLUSION

We could confirm the faster pain relief in the prosthesis group and overall a faster recovery of strength and mobility. However, there were more short-term complications in the prosthesis group. More evidence is required to evaluate thoroughly the short-term recovery of strength, the mobility, functionality and satisfaction.

REFERENCES

1. **Abbas K, Hashmi P, Raza H.** Short term results of ligament reconstruction and tendon interposition arthroplasty for basal joint arthritis. *J Pak Med Assoc.* 2012 ; 62 : 398-401.
2. **Anakwe RE, Middleton SD.** Osteoarthritis at the base of the thumb. *BMJ.* 2011 ; 343 : d7122-d7122.
3. **Armstrong AL, Hunter JB, Davis TRC.** The prevalence of degenerative arthritis of the base of the thumb in post-menopausal women. *J Hand Surg Am.* 1994 ; 19 : 340-341
4. **August AC, Coupland RM, Sandifer JP.** Short term review of the De La Caffiniere trapeziometacarpal arthroplasty. *J Hand Surg Am.* 1984 ; 9 : 185-188.
5. **Belcher HJCR, Nicholl JE.** A comparison of trapeziectomy with and without ligament reconstruction and tendon interposition. *J Hand Surg Br.* 2000 ; 25 : 350-356.
6. **Bricout M, Rezzouk J.** Complications and failures of the trapeziometacarpal Maia prosthesis : A series of 156 cases. *Hand Surg Rehabil.* 2016 ; 35 : 190-198.
7. **Brutus JP, Kinnen L.** Remplacement prothétique total de la trapézomy tacarpienne au moyen de la prothèse ARPE dans le traitement de la rhizarthrose : Notre expérience à court terme dans une série personnelle de 63 cas consécutifs. *Chir Main.* 2004 ; 23 : 224-228.
8. **Burton RI, Pellegrini VD.** Surgical management of basal joint arthritis of the thumb. Part II. Ligament reconstruction with tendon interposition arthroplasty. *J Hand Surg Am.* 1986 ; 11 : 324-332.
9. **Chakrabarti AJ, Robinson AHN, P. G.** de la caffinière carpometacarpal replacements. *J Hand Surg Br.* 1997 ; 22 : 695-698.
10. **Davis TR, Brady O, Barton NJ, Lunn PG, Burke FD.** Trapeziectomy alone, with tendon interposition or with ligament reconstruction. *J Hand Surg Br.* 1997 ; 22 : 689-694.
11. **Davis TR, Brady O, Dias JJ.** Excision of the trapezium for osteoarthritis of the trapeziometacarpal joint : A study of the benefit of ligament reconstruction or tendon interposition. *J Hand Surg Am.* 2004 ; 29 : 1069-1077.
12. **De Smet L, Sioen W, Spaepen D, Van Ransbeeck H.** Total joint arthroplasty for osteoarthritis of the thumb basal joint. *Acta Orthop Belg.* 2004 ; 70 : 19-24.
13. **De Smet L, Vandenberghe L, Degreef I.** Long-term outcome of trapeziectomy with ligament reconstruction and tendon interposition (LRTI) versus prosthesis arthroplasty for basal joint osteoarthritis of the thumb. *Acta Orthop Belg.* 2013 ; 79 : 146-149.
14. **García-Mas R, Solé Molins X.** Partial trapeziectomy with ligament reconstruction – tendon interposition in thumb carpo-metacarpal osteoarthritis. A study of 112 cases. *Chir Main.* 2009 ; 28 : 230-238.
15. **Gay AM, Cerlier A, Iniesta A, Legré R.** Surgery for trapeziometacarpal osteoarthritis. *Hand Surg Rehabil.* 2016 ; 35 : 238-249.
16. **Goubau JF, Goorens CK, Van Hoonacker P, et al.** Clinical and radiological outcomes of the Ivory arthroplasty for trapeziometacarpal joint osteoarthritis with a minimum of 5 years of follow-up : a prospective single-centre cohort study. *J Hand Surg Eur Vol.* 2013 ; 38 : 866-874.
17. **Goubau JF, Goubau L, Goorens CK, et al.** De Quervain Tenosynovitis Following Trapeziometacarpal Ball-and-Socket Joint Replacement. *J Wrist Surg.* 2015 ; 4 : 35-42.
18. **Hansen TB, Kirkeby L.** No correlation between severity of preoperative degenerative changes in the trapeziometacarpal joint and short-term clinical outcome after total joint arthroplasty. *Hand Surg Rehabil.* 2016 ; 35(1) : 16-20.
19. **Hansen TB, Snerum L.** Elektra trapeziometacarpal prosthesis for treatment of osteoarthritis of the basal joint of the thumb. *Scand J Plast Reconstr Surg Hand Surg.* 2008 ; 42 : 316-319.
20. **Hansen TB, Stilling M.** Equally good fixation of cemented and uncemented cups in total trapeziometacarpal joint prostheses. A randomized clinical RSA study with 2-year follow-up. *Acta Orthop.* 2013 ; 84 : 98-105.
21. **Huang K, Hollevoet N, Giddins G.** Thumb carpometacarpal joint total arthroplasty : a systematic review. *J Hand Surg Eur Vol.* 2015 ; 40 : 338-350.
22. **Hudak PL, Amadio PC, Bombardier C, et al.** Development of an upper extremity outcome measure : The DASH (disabilities of the arm, shoulder, and hand) (corrected). The Upper Extremity collaborative Group (UECG). *Am J Ind Med.* 1996 ; 29 : 602-608.
23. **Jacoulet P.** Résultats de la prothèse trapézométacarpienne ARPE : à propos de 37 implantations. *Chir Main.* 2005 ; 24 : 24-28.
24. **Jager T, Barbary S, Dap F, Dautel G.** Analyse de la douleur postopératoire et des résultats fonctionnels précoces dans le traitement de la rhizarthrose. étude prospective comparative de 74 patientes trapézectomie-interposition vs prothèse MAIA. *Chir Main.* 2013 ; 32 : 55-62.
25. **Langenhan R, Hohendorff B, Probst A.** Trapeziectomy and ligament reconstruction tendon interposition for isolated scaphotrapezotrapezoid osteoarthritis of the wrist. *J Hand Surg Eur Vol.* 2014 ; 39 : 833-837.
26. **Lemoine S, Wavreille G, Alnot JY, Fontaine C, Chantelot C.** Second generation Guepar total arthroplasty of the thumb basal joint : 50 months follow-up in 84 cases. *Orthop Traumatol Surg Res.* 2009 ; 95 : 63-69.

27. **Martin-Ferrero M.** Ten-year long-term results of total joint arthroplasties with ARPE® implant in the treatment of trapeziometacarpal osteoarthritis. *J Hand Surg Eur Vol.* 2014 ; 39 : 826-832.
28. **Megerle K, Grouls S, Germann G, Kloeters O, Hellmich S.** Revision surgery after trapeziometacarpal arthroplasty. *Arch Orthop Trauma Surg.* 2011 ; 131 : 205-210.
29. **Moineau G, Richou J, Gérard R, Le Nen D.** Trapézectomies et ligamentoplasties de suspension au Gore-Tex : résultats préliminaires sur 43 arthroses trapézo-métacarpiennes. *Chir Main.* 2008 ; 27 : 146-153.
30. **Raven EE, Kerkhoffs GM, Rutten S, et al.** Long term results of surgical intervention for osteoarthritis of the trapeziometacarpal joint : Comparison of resection arthroplasty, trapeziectomy with tendon interposition and trapeziometacarpal arthrodesis. *Int Orthop.* 2007 ; 31 : 547-554.
31. **Spaans AJ, Van Minnen LP, Kon M, et al.** Conservative treatment of thumb base osteoarthritis : A systematic review. *J Hand Surg Am.* 2015 ; 40 : 16-21.
32. **Ulrich-Vinther M, Puggaard H, Lange B.** Prospective 1-Year Follow-Up Study Comparing Joint Prosthesis With Tendon Interposition Arthroplasty in Treatment of Trapeziometacarpal Osteoarthritis. *J Hand Surg Am.* 2008 ; 33 : 1369-1377.
33. **Van Cappelle HG, Elzenga P, Van Horn JR.** Long-term results and loosening analysis of de la Caffiniere replacements of the trapeziometacarpal joint. *J Hand Surg Am.* 1999 ; 24 : 476-482.
34. **Vander Eecken S, Vanhove W, Hollevoet N.** Trapeziometacarpal joint replacement with the Arpe prosthesis. *Acta Orthop Belg.* 2012 ; 78 : 724-729.
35. **Vermeulen GM, Slijper H, Feitz R, et al.** Surgical management of primary thumb carpometacarpal osteoarthritis : A systematic review. *J Hand Surg Am.* 2011 ; 36 : 157-69.
36. **Wajon A, Vinycomb T, Carr E, Edmunds I, Ada L.** Surgery for thumb (trapeziometacarpal joint) osteoarthritis. *Cochrane Database Syst Rev.* 2015 ; 4.
37. **Werthel JD, Dubert T.** Use of the entire flexor carpi radialis tendon for basal thumb ligament reconstruction interposition arthroplasty. *Hand Surg Rehabil.* 2016 ; 35 : 107-113.