



Severe heterotopic ossification after a shoulder arthroscopy : a rare clinical presentation

Olivier DHOLLANDER, Andrew MCKEE, Rick HOUBEN

From the Department of Orthopaedic Surgery, AZ Turnhout, Turnhout, Belgium

Heterotopic ossification is a well-known complication after orthopaedic surgical procedures, with a predilection of the hip and elbow. Heterotopic ossification is a rare complication after shoulder arthroscopy and is rarely clinically significant.

We report a case of a 65-year old Caucasian man with a slow and painful recovery after arthroscopic shoulder surgery encompassing rotator cuff repair, biceps tenotomy and acromioplasty, with recurrence of impingement symptoms unresponsive to conservative therapy (physiotherapy and one sub-acromial injection). He developed a severe heterotopic ossification at the acromial insertion of the deltoid and in the coraco-acromial ligament. This was successfully treated by arthroscopic excision of the lesion and postoperative prophylactic therapy with nonsteroidal anti-inflammatory drugs.

Keywords : shoulder ; heterotopic ossification ; arthroscopy ; complication.

INTRODUCTION

Heterotopic Ossification (HO) is an uncommon complication after shoulder arthroscopy and is rarely clinically significant. To our knowledge only Berg et al. reported a series of clinically significant HO cases after shoulder arthroscopy (3).

We report the surgical, clinical, and radiological details of an additional case, as well as the therapeutic

measures that were taken. We highlight the need to identify risk factors and to prescribe more specific medical imaging when a patient complains of persistent impingement symptoms after shoulder arthroscopy.

CASE REPORT

A 65-year-old right-handed patient initially complained of sudden pain with an audible snap in the left shoulder while playing table tennis. Plain imaging and ultrasound confirmed the diagnosis of a rotator cuff tear and an injured proximal biceps tendon of the long head with a Bigliani I acromion.

Based on the traumatic nature of the tear, age and fitness of the patient the senior author, a fellowship trained shoulder surgeon, offered surgery. Informed consent was obtained and the surgery was performed under general anaesthesia and regional

- Olivier Dhollander¹,
- Andrew McKee²,
- Rick Houben¹

¹ Department of Orthopaedic Surgery, AZ Turnhout, Turnhout, Belgium

² Department of Orthopaedic Surgery, North West Anglian NHS Foundation Trust, Peterborough, United Kingdom

Correspondence : Olivier Dhollander, M.D. Department of Orthopaedic Surgery, Academic Hospital Turnhout, Rubensstraat 166, 2300 Turnhout, Belgium. Tel.: +32 14 40 67 85. Fax: +32 14 40 62 91.

E-mail : olivier.dhollander@skynet.be

© 2020, Acta Orthopædica Belgica.

No benefits or funds were received in support of this study. The authors report no conflict of interests.

Acta Orthopædica Belgica, Vol. 86 - 1 - 2020

block. Arthroscopy revealed a full thickness rupture of the supraspinatus and infraspinatus tendons. The long head of the biceps muscle was severely inflamed and delaminated. A biceps tenotomy, subacromial bursectomy and acromioplasty were performed. The rotator cuff was repaired with a double row technique, with a metallic anchor on the medial footprint and placing a lateral peek anchor. Inspection showed a stable, watertight reduction of the cuff, adequate removal of bone and periosteal remnants. A suction-irrigation pump (Arthrex AR-6480 DualWave Arthroscopy Pump), with maximum pressure of 50mmHg, was used during the arthroscopy with removal of all macroscopic debris of the left shoulder.

His recovery during the first 6 weeks was as one would expect after this type of surgery. In the following 6 weeks, the patient developed pain at 90° of elevation. At 12 weeks a postoperative plain radiograph and ultrasound of the left shoulder did not reveal any problems with the rotator cuff repair, however a calcific like deposit was noted superior to the cuff repair. (Figure 1) A subacromial infiltration (SAI) with corticosteroids was given, as a reactive rotator cuff calcification secondary to the repair was suspected.

Two months after the SAI, a new radiograph of the left shoulder showed further ossification. Clinical examination revealed an improvement of the range of motion of the left shoulder with passive and active elevation of 150° and 130°, passive and active abduction of 100° and 90° and external and internal rotation of 50° and 10° respectively. Shoulder strength was returning and further rehabilitation was advised.

At seven months post surgery, pain persisted, as did the impingement symptoms and signs. CT imaging of the left shoulder was performed and revealed an ossification of the coraco-acromial ligament with a large plate-shaped HO formation originating from the anterolateral part of the acromion. (Figure 2) The rotator cuff repair was intact. Given that the ossification was most likely the cause of the symptoms, especially pain during elevation above shoulder level, a revision shoulder arthroscopy was advised to remove the new bone formation.

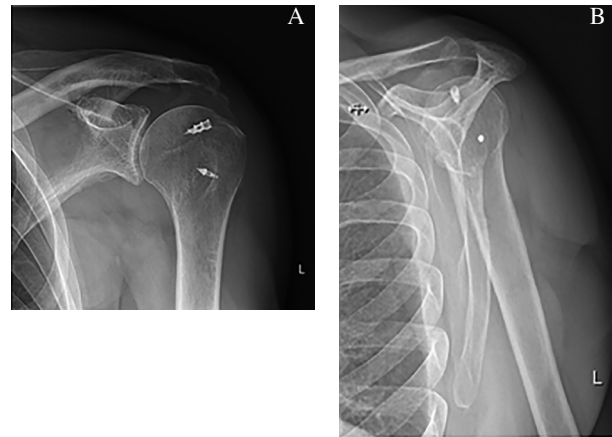


Figure 1. — Postoperative plain radiographs, 3 months after surgery: true AP view/Grashey view (A), and lateral Y view (B), show an important calcification or ossification of the shoulder in the subacromial space.

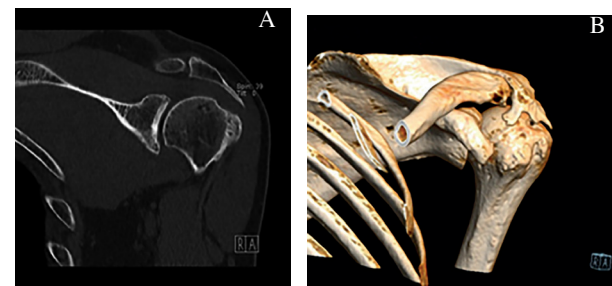


Figure 2. — Postoperative computed tomography scan, 7 months after surgery: coronal plane (A) and 3D reconstruction (B), showed a rare ossification of the coraco-acromial ligament with a plate-shaped osteophyte formation originates from the acromion going antero-lateral, which makes this case special.

At nine months the second shoulder arthroscopy was performed under block and general anaesthesia. The rotator cuff repair had healed, and no other intra-articular pathology was identified. The heterotypic ossification was identified in the subacromial space and removed by shaving. Removal was confirmed using intra operative C-arm, All macroscopic debris was removed via irrigation.

The first two weeks after surgery the patient wore an adduction sling. NSAID (ibuprofen 600mg, 3 times daily) was prescribed for 3 weeks. A physiotherapist supervised postoperative recovery with immediate passive and active mobilization during the first two weeks then strengthening exercises.

He made an uneventful recovery by 2 months, and further x-rays showed no recurrence of the lesion.

DISCUSSION

HO is a term used to describe all abnormal ossifying lesions around a joint. It is a well-recognized complication after orthopaedic surgery of the hip in particular, but knee, elbow, femur, and shoulder involvement has been described. In HO mature bone trabeculae are formed in tissues that normally do not ossify at triple the normal rate and more than twice the number of osteoclasts are present in comparison with normal age-matched bone. This is different from dystrophic calcification where acellular amorphous calcium phosphate is deposited (2,5,7,8).

The pathogenesis of HO is incompletely understood but is thought to be multifactorial, with both local and systemic factors, usually relating to pathology of the central nervous and pulmonary system (2,8). One of the proposed causes is low partial oxygen pressure and tissue hypoxia. This occurrence could explain the inciting mechanism of ectopic bone deposition in patients with chronic pulmonary diseases in long-standing smokers (2). Other predisposing causes have been proposed : prostaglandin E2 activity, hypercalcemia, alterations in sympathetic nerve activity, prolonged immobilization, and imbalances between parathyroid hormone activity and calcitonin (8). Like in this case, HO after acromioplasty may be analogous to the bone often seen at the proximal end of intramedullary rods, so called callus caps. This bone is believed to be the result of spilled osteogenic intramedullary reamings and marrow contents (2). Another theory is that ectopic bone is caused by periosteal remnants of incomplete bone removal (2).

HO of the shoulder appears to be an uncommon complication of shoulder surgery and has been described more commonly after open than after arthroscopic procedures. Constant irrigation with arthroscopic fluid, which dilutes osteoinductive marrow elements from bone after subacromial decompression, minimal soft-tissue trauma, which limits the hematoma formation probably decrease

the risk for ectopic bone formation (8). Boynton et al. described a form of HO with the deltoid muscle as an ossificating bridge between the acromion and the proximal humerus after arthroscopic acromioplasty (4). Aibinder et al. reported a HO in the deltoid muscle after an arthroscopic distal clavicle resection and revision rotator cuff repair (1). But to our knowledge only Berg et al. reported a series of cases with similar radiographic findings and clinical significance of the acromion (3). The clinical importance of an ossifying lesion after shoulder surgery remains unclear because of inconsistent definitions, varying correlations of symptom severity and radiographic findings, and lack of treatment efficacy data (8).

In this case the HO derived from the bone-muscle interface of the deltoid muscle and spreads in close proximity of the muscle towards the subacromial space, similar to HO around the hip, which mostly begins on the trochanter major (10). The postoperative computed tomography (figure 2) shows that the ossifying lesion is in direct communication with the acromion. The presence of the ossifying lesion in the subacromial space causes a slow and painful revalidation with typical impingement symptoms like the painful arc. By removing this lesion we removed the cause of the impingement. Like described earlier, the site of surgery was visualized at the end of the procedure and showed no osteoinductive debris. Reossification and fusion across the acromioclavicular joint after arthroscopic acromioplasty and distal clavicle resection is described before (10). The ossification of the coracoacromial ligament was not removed.

A probable aetiology for this type of HO is that the arthroscopy caused microscopic traumata and inflammation of the deltoid fascia and triggered the growth of the ossifying lesion. In that case it is an acquired traumatic (iatrogenic) form of HO. Another possible cause is an excessive amount of resected bony debris left behind that acts as a form of bone graft (4,10). A standard irrigation and suction system was used washing out all the bone debris, although this could theoretically cause bone seeding into the soft tissues.

We hypothesize that in this case the HO of acromion is most likely due to the arthroscopic

subacromial decompression. This is routinely performed by the senior author. Before 2010, Sanders et al. found no reports of HO after arthroscopic rotator cuff repair (8). Complications of arthroscopic acromioplasty are relatively uncommon and include hematoma, traction neuropathy, infection, acromial fracture, reflex sympathetic dystrophy, and instrument breakage (4).

Forced passive mobilization may be an associated factor in HO development in severely burned non-communication patients in intensive care unit (9). A decision was made to wait nine months after his initial operation to allow the HO to mature. The lesion is thought to recur and possibly progress if resection is performed before maturation.

Prophylactic therapy with NSAID (ibuprofen 600mg, 3 times daily) was prescribed after the revision procedure for 3 weeks postoperative to prevent postoperative HO. Because of the low incidence of HO after shoulder acromioplasty literature suggests that the use of prophylactic measures, NSAIDs or radiotherapy, as primary prevention for the formation of ectopic bone should only be considered in patients at risk : those who have a profile consistent with hypertrophic pulmonary osteoarthropathy and patients with hypertrophic arthritis (2,3). The patient in this case did not have any risk factors further formation of HO.

We highlight the need to consider this as a treatable cause of pain who have poor recovery after shoulder surgery.

REFERENCES

1. **Aibinder WR, Sperling JW.** Heterotopic bone with rotator cuff tear : a case report and review of the literature. *J Shoulder Elbow Surg.* 2015 ; 24 : e190-4.
2. **Berg EE, Ciullo JV.** Heterotopic ossification after acromioplasty and distal clavicle resection. *J Shoulder Elbow Surg.* 1995 ; 4 : 188-93.
3. **Berg EE, Ciullo JV, Oglesby JW.** Failure of arthroscopic decompression by subacromial heterotopic ossification causing recurrent impingement. *Arthroscopy.* 1994 ; 10 : 158-61.
4. **Boynnton MD, Enders TJ.** Severe heterotopic ossification after arthroscopic acromioplasty : a case report. *J Shoulder Elbow Surg.* 1999 ; 8 : 495-7.
5. **Degreef I, Debeer P.** Heterotopic ossification of the supraspinatus tendon after rotator cuff repair : case report. *Clin rheumatol.* 2006 ; 25 : 251-3.
6. **Erggelet C, Eggenperger G, Steinwachs M, Lahm A, Reichelt A.** Postoperative ossifications of the shoulder. Incidence and clinical impact. *Arch Orthop Trauma Surg.* 1999 ; 119 : 168-70.
7. **Pons-Villanueva J, Romero Munoz LM, Amillo Garayoa S.** Ossifying lesion of the rotator interval. *Musculoskelet surg.* 2011 ; 95 : 53-7.
8. **Sanders BS, Wilcox RB, 3rd, Higgins LD.** Heterotopic ossification of the deltoid muscle after arthroscopic rotator cuff repair. *Am J Orthop (Belle Mead, NJ).* 2010 ; 39 : E67-71.
9. **Thefenne L, de Brier G, Leclerc L et al.** Two new risk factors for heterotopic ossification development after severe burns. *PLoS One.* 2017 ; 12 : e0182303
10. **Tytherleigh-Strong G, Gill J, Sforza G, Copeland S, Levy O.** Reossification and fusion across the acromioclavicular joint after arthroscopic acromioplasty and distal clavicle resection. *Arthroscopy.* 2001 ; 17 : E36.