



## Medium term outcomes of the Universal 2 total wrist arthroplasty in patients with degenerative or posttraumatic osteoarthritis of the wrist

Helene GENDERA, Selvie CHANDRASEGARAM-SHANMUGANATHAN, Ralf WALBEEHM, Steven SAMIJO

*From the Department of Orthopaedic Surgery and Traumatology, Heerlen, Zuyderland Medisch Centrum. The Netherlands*

This retrospective study reports medium term outcomes of 14 total wrist arthroplasties in patients with especially, non-rheumatoid, degenerative osteoarthritis and post-traumatic osteoarthritis with a mean follow up of 5 to 10 years. Information of fourteen patients, 6 men and 8 women with a mean age of 61 years, was collected before and after total wrist arthroplasty (Universal 2 prosthesis, Integra) carried out by a single surgeon. Pre-operative mobility was determined by range of motion and compared to post-operative range of motion. Post-operative function was determined using the DASH (The disabilities of the arm, shoulder and hand) score and the PRWE (patient-rated wrist evaluation and grip strength) score. Grip force between the operated and non-operated hand were compared postoperatively. Three patients experienced complications. Range of motion improved post-operatively, although not significantly, due to an increase in palmar flexion. The mean DASH score was 20% and the mean total PRWE was 54%. This study shows that total wrist arthroplasty, using the Universal 2 wrist prosthesis, gives reasonable results (survival rate 84%) by decreasing pain while preserving range of motion in patients with degenerative osteoarthritis of the wrist after 5 years. However the 10-year survival rate decreases steeply to an unsatisfying 35%.

**Keywords :** total wrist arthroplasty ; total wrist prosthesis ; universal total wrist ; wrist arthrodesis ; osteoarthritis of the wrist.

### INTRODUCTION

Different surgical interventions are available when treating arthritis of the wrist (5). These surgical treatments, for example, consist out of total wrist arthrodesis, proximal row carpectomy or four-corner fusion.

Total wrist arthroplasty (TWA) is an upcoming surgical treatment in patients suffering from pain and functional loss of their wrist due to rheumatoid arthritis and (posttraumatic) degenerative arthritis. This procedure can reduce pain while remaining a decent joint function (9). However, until this day, total wrist implants have not reached the success of hip or knee prosthesis (4,8). Poor results have been described due to design-shortcomings, while medium to long term follow up studies are lacking. Moreover, often study populations are mixed regarding the type of wrist prosthesis as well as patient characteristics, i.e. rheumatoid and

- 
- Helene Gendera M.D.
  - Selvie Shandrasegaram-Shanmuganathan, M.D.
  - Ralf Walbeehm M.D.
  - Steven Samijo M.D. PhD

*Department of Orthopaedic Surgery and Traumatology, Heerlen, Zuyderland Medisch Centrum. The Netherlands.*

Correspondence : Steven K Samijo, Department orthopedic surgery, Henri Dunantstraat 1, 6401 cx, Heerlen, The Netherlands.

E-mail : S.Samijo@zuyderland.nl

© 2020, Acta Orthopædica Belgica.

---

non-rheumatoid patients (1,7). Yeoh et al. showed in a systematic review, comparing seven wrist prosthesis : Universal (KMI, San Diego, California, USA), Universal 2 (Integra, Plainsboro, USA), Remotion (Small Bones innovation, Pennsylvania, USA), Biaxial (Dupuy Orthopaedics Inc, Leeds, UK), Motec and Elos (Swemac orthopaedics ABM Linkoping, Sweden) and the Maestro Total Wrist System (Biomet, Warsaw, Indiana USA), that the Universal 2 appeared to have the highest survival rates (100% at 3-5 years), thus in short term studies (11). The aim of our study was to retrospectively evaluate the functional and radiologic results of a unicentric, single surgeon (SS) series of the Universal 2 (Integra, Plainsboro, USA), total wrist prosthesis in patients with solely osteoarthritis (non-rheumatoid) of their wrist, for at least 5 years.

## MATERIAL AND METHODS

Fifty-seven total wrist arthroplasties were performed between 2007 and 2011 by a single surgeon (SS) in Zuyderland medical centre (former Atrium), Heerlen, the Netherlands. Rheumatoid cases and total wrist implants used other than the Universal 2; were excluded from this study. To assess medium term results, total wrist arthroplasties performed after 2011 were also excluded. See figure 1.

Patients were persuaded to participate with this study by means of a call letter or telephone contact.

Eventually 14 patients (6 men and 8 women with a mean age of 61 years) who received a universal 2 total wrist prosthesis implanted for osteoarthritis and posttraumatic osteoarthritis gave their consent in participating in this retrospective study. The data was collected by Drs. Chandrasegaram-Shanmuganathan during a one-time visit at the outpatient clinic in which the range of motion, using a manual goniometer, and the grip strength, using a hand dynamometer, were measured. The functionality and limitations of the operated wrist were evaluated by filling in two questionnaires (DASH- and PRWE-scores) which patients received by mail our filled in at the visit to the clinic. Satisfaction was substantiated on the basis of direct questioning in which patients could indicate whether

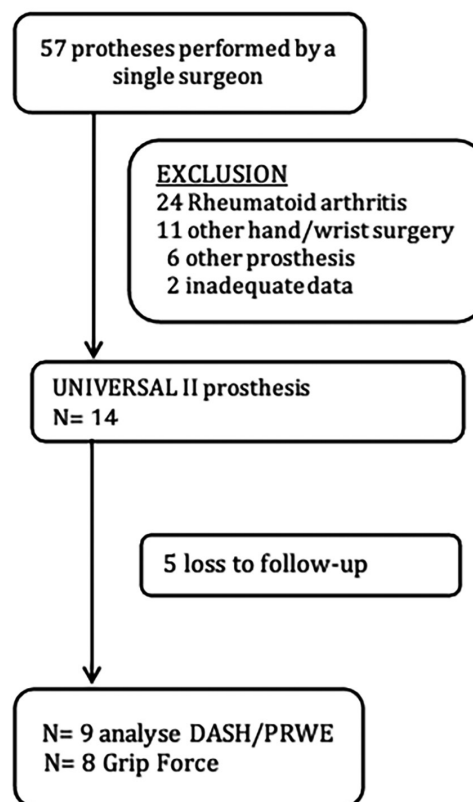


Figure 1. — Flow chart.

they were satisfied about the results and would reconsider the operation having the information they have now. They could answer with : very satisfied, satisfied, neutral, unsatisfied and very unsatisfied. As to whether they would have done the operation again, knowing what they know now, a simple yes, no or don't know question was asked.

Participants in this study were in different moments of their postoperative trajectory during these measurements, with a mean follow-up between 5 and 10 years.

Because the pre-operative grip strength and DASH- and PRWE-scores were not available because of the retrospective design of the study, we examined the function loss after surgery by comparing the grip force between the operated hand and the non-operated hand. Furthermore we used the data collected during standard follow-up six weeks postoperatively, in which dr. Samijo and dr. Walbeehm determined the range of motion ; dorsal extension, volar flexion and radial and ulnar

deviation by visual assessment. These results were retrospectively compared with the pre-operative measurements.

At the time of this study three implanted wrist prosthesis underwent a re-operation. One patient received another total wrist arthroplasty-due to

Table 1. — Patient characteristics

Patient characteristics	ROM pre-operative	ROM post-operative	PRWE (mean/pain/function)	DASH	Grip force Prosthesis/ Contralateral (kg)	Satisfaction
Female 53y	Right F/E: 40/60 R/U: 0/35	F/E: 65/45 R/U: 10/45	97 36 61	54	16/30	Yes
Male 43y	Left F/E: 30/20 R/U: 10/30	F/E: 30/10 R/U: 5/10	-	-	-	-
Female 69y	Left F/E: 20/10 R/U: 20/40	F/E: 20/10 R/U: 20/40	33 13 20	35	18/25	Yes
Female 72y	Right F/E: 20/10 R/U: 20/40	F/E: 30/40 R/U: 10/20	-	-	-	-
Male 56y	Left F/U: 50/-10 R/U: 20/30	F/E: 40/50 R/U: 50/20	7 0 7	26	40/52	Yes
Male 64y	Right F/E: 30/30 R/U: 20/30	F/E: 40/30 R/U: 10/40	0 0 0	26	34/44	Yes
Female 70y	Right F/E: 10/40 R/U: 20/40	F/E: 30/40 R/U: 10/20	-	-	-	-
Female 76y	Left F/E: 30/30 R/U: 20/30	F/E: 30/30 R/U: 0/20	-	-	-	-
Female 63y	Right F/E: 40/50 R/U: 10/40	F/E: 55/40 R/U: 0/20	108 44 64	51	16/24	neutral
Female 62y	Right F/E: 20/30 -	F/E: 25/25 R/U: 10/20	84	74	6/26	Yes
Male 59y	Right F/E: 40/15 -	F/E: 30/50 R/U: 10/20	53 24 29	46	14/34	Yes
Female 55y	Left F/U: 20/50 R/U: 10/40	F/U: 30/30 R/U: 10/20	55 21 34	64	-	-
Male 58y	Right F/E: 30/70 R/U: 10/20	F/E: 50/50 R/U: 10/40	80 25 55	90	10/18	Yes
Male 53y	Right F/E: 30/40 R/U: 10/40	F/E: 60/40 R/U: 20/40	-	-	-	-

F : Female, M : male, ROM : range of motion. F/E : Flexion/Extension, R/U : Radial/ulnar deviation.

loosening of the distal component ; in the other two patients, as they refused a revision, the arthroplasties were converted to total wrist arthrodesis : one patient due to persistent pain and one patient due to loosening of the distal component. Furthermore two patients did not want to participate with our questionnaires after their surgery, for unknown reasons. Their available data is used in this study with the consent of the patients.

Postoperative imaging is carried out six weeks after surgery, annually and sometimes during an additional follow-up when indicated. Since patients were operated between 2007 and 2011 we used the latest available imaging in this study. Radiologic assessments included 2 images : anterior-posterior view and a lateral view, and was performed by an experienced radio-skeletal radiologists. X-rays were evaluated for osteolysis, dislocation and fractures. No comparative imaging was performed of the contralateral wrist.

The analyses were performed with the use of SPSS version 17.0 software (SPSS Inc., Chicago, USA). To compare pre-operative range of motion to post-operative range of motion we used a paired t-test. For all analyses, a p-value was considered to be statistically significant at  $p \leq 0.05$ . Kaplan Meier survival analysis was calculated to predict survival of the prosthesis.

## RESULTS

The collected data from the 14 participating patients can be found in table 1.

The available data, in particular the range of motion, of the 5 patients that were lost to follow up, for the reasons mentioned above, was used in this analysis. One patient only filled in the questionnaire.

Mean pre-operative values were : palmar flexion  $29^\circ$  [10-50°], dorsiflexion  $32^\circ$  [10-70°], radial deviation  $14^\circ$  [0-20°] and ulnar deviation  $35^\circ$  [20-40°].

Mean post-operative values were : palmar flexion  $47^\circ$  [20-130°], dorsiflexion  $35^\circ$  [10-50°], radial deviation  $13^\circ$  [5-0] and ulnar deviation  $27^\circ$  [10-45°].

Mean DASH score was 52 [26-90]. The mean PRWE score was 20 for the assessment of pain and 34 for the assessment of function. Mean total PRWE was 54.

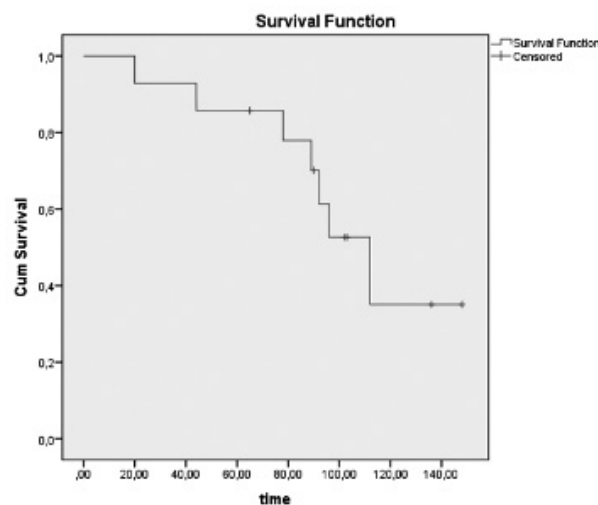


Figure 2. — Kaplan Meier survival.

Mean grip force of the operated hand was 19.4 kg. Mean grip force of the non-operated hand was 31.6 kg. It appears to be a significant difference between the grip force of the operated hand and the non-operated hand ( $p=0.05$ ).

Kaplan Meier survival function analysis of the Universal-2 total wrist arthroplasty showed a 5 years survival was of 84% and a 10-year survival rate of 35%. See Figure 2.

Imaging investigation showed loosening of one or both component in 6 patients. Loosening was described as a radiolucent line around the prosthesis. Only 2 out of 6 had expressed pain in combination with this radiological abnormality.

## DISCUSSION

Total wrist arthroplasty is considered to be a surgical alternative for radiocarpal arthrodesis, as the latter is considered as the golden standard treating wrist arthritis. However, the key indication for wrist arthroplasty, besides pain relief, is to keep or restore wrist motion. Several studies have shown good survival after total wrist implant after short term follow up (5 years or less) while, there are only a few medium and long-term studies (more than 10 years) are missing (3,6,7). Also studies of wrist arthroplasty in, especially, non-rheumatoid wrist arthritis are scarce, as in the past the indications

for implanting a wrist prosthesis were rheumatoid wrists.

Our study focuses on medium term, i.e. between 5 and 10 years, results on the Universal 2 (Integra, USA) total wrist arthroplasty implanted in non-rheumatoid, thus degenerative and post-traumatic wrist arthritis. We report a slight lower survival in terms of revision or conversion to arthrodesis (84%) compared to literature (97-100%) (3,7,10). Longer follow up (10 years) showed a survival of 35%. Loosening was observed in accordance to literature and most osteolysis is seen on the carpal side of the prosthesis. <sup>2</sup>

It must be emphasized that is difficult to compare the results of this study to literature due to inhomogeneity (type of prosthesis or patient) in literature and follow up time (3,7,10). We are aware that five patients did not complete the study due to inability to complete follow up, but despite this, radiographic data and postoperative function could be assessed.

The main limitation of our study is that pre- and post-operative pain and function loss could not be compared since at the beginning of implantation the DASH and PRWE score was not assessed; moreover this is a retrospective study.

To assess a better understanding of function, grip strength was measured, after wrist arthroplasty and comparison was made between the operated and non-operated hand. The significant difference in grip force, in favour of the non-operated hand might be explained by the indication that arthroplasty was performed mainly in the non-dominant hand and thus the hand with the less power originally. A limitation of this measurement is the lack of comparative imaging concerning the contralateral wrist. In the case of a degenerative contralateral wrist, the difference in grip strength could be underestimated

In addition we reviewed patients satisfaction and according to this study 7 patients (50%) would undergo the total wrist arthroplasty surgery again. Therefore we cannot conclude from this study, that patients prefer an arthroplasty above a wrist arthrodesis. It should be noted that five patient were lost to follow up.

Our data showed no significant decrease or increase in range of motion in any direction. A non-significant, increase in palmar flexion was observed which might be explained by the biomechanical properties of the universal 2 prosthesis as it was designed for the carpal component to be seated rather volar, than dorsal, accommodating more flexion. We are aware that the number of patients is too small to draw large-scale conclusions, but total wrist arthroplasty in degenerative and posttraumatic wrist arthritis has the equal results compared to arthroplasty in rheumatoid wrist on medium term. The survival after 5 years of total wrist arthroplasty of the Universal 2 wrist prosthesis for rheumatoid arthritis is 75-91% (1,2). Remarkably, there is a different survival after 10 years of the Universal 2 wrist prosthesis implanted in patients with degenerative or post-traumatic wrist arthritis, i.e. (35% starting from the Kaplan Meier survival) compared to wrist prosthesis implantation in patients with rheumatoid arthritis (64%) (1,2). This difference could be explained by the higher demanding wrist function needed in daily life in the non rheumatoid patients. Larger series and longer follow up are needed to draw large-scale conclusions.

In general, our findings are in agreement with literature saying that total wrist arthroplasty can relieve pain while maintaining range of motion, although grip force is maintained but might be compromised (6,7).

## CONCLUSION

The Universal-2 total wrist prosthesis (Integra) in patients with osteoarthritis and post-traumatic osteoarthritis shows reasonable medium term results (84%) concerning survival but decreases steeply to 35% at 10 years when looking at the Kaplan Meier analysis. Based on these results we do not longer use this universal 2 prosthesis, but longer follow up is needed for definitive conclusions for total wrist arthroplasty in degenerative arthritis and posttraumatic arthritis of the wrist.

## REFERENCES

1. Badge, R., Kailash, K., Dickson et al. Medium-term outcomes of the Universal-2 total wrist arthroplasty in

- patients with rheumatoid arthritis. *Bone Joint J* 2016 ; 98 : 1642-1647.
2. **Harlingen, D., Heesterbeek, P. J., & M, J. d. V.** High rate of complications and radiographic loosening of the biaxial total wrist arthroplasty in rheumatoid arthritis : 32 wrists followed for 6 (5-8) years. *Acta Orthop* 2011 ; 82 : 721-726.
  3. **Herzberg, G.** Prospective study of a new total wrist arthroplasty : short term results. *Chir Main* 2011 ; 30 : 20-25.
  4. **Krukhaug, Y., Lie, S. A., Havelin, L. I. et al.** Results of 189 wrist replacements. A report from the Norwegian Arthroplasty Register. *Acta Orthop* 2011 ; 82 : 405-409.
  5. **Logan, J. S., & Warwick, D.** The treatment of arthritis of the wrist. *Bone Joint J* 2015 ; 97 : 1303-1308.
  6. **McCullough, M. B., Adams, B. D., & Grosland, N. M.** Postoperative analysis of patients who received the Universal 2 total wrist implant system. *J Appl Biomech* 2012 ; 28 : 466-472.
  7. **Morapudi, S. P., Marlow, W. J., Withers et al.** Total wrist arthroplasty using the Universal 2 prosthesis. *J Orthop Surg (Hong Kong)* 2012 ; 20 : 365-368.
  8. **Reigstad, A., Reigstad, O., Grimsgaard, C. et al.** New concept for total wrist replacement. *J Plast Surg Hand Surg* 2011, 45 : 148-156.
  9. **Sagerfors, M., Gupta, A., Brus, O., & Pettersson, K.** Total Wrist Arthroplasty : A Single-Center Study of 219 Cases With 5-Year Follow-up. *J Hand Surg Am* 2015 ; 40 : 2380-2387.
  10. **Ward, C. M., Kuhl, T., & Adams, B. D.** Five to ten-year outcomes of the Universal total wrist arthroplasty in patients with rheumatoid arthritis. *J Bone Joint Surg Am* 2011 ; 93 : 914-919.
  11. **Yeoh, D., & Turret, L.** Total wrist arthroplasty : a systematic review of the evidence from the last 5 years. *J Hand Surg Eur* 2015 ; 40 : 458-468.