



Mesenchymal stem cell therapy for hip osteoarthritis : a systematic review

Alessio BIAZZO, Francesco MASIA, Francesco VERDE

From the Humanitas Gavazzeni, Orthopedic Department, Bergamo, Italy

Hip osteoarthritis affects 8.7% of men and 9.3% of women over the age of 45 in the United States. Treatment of hip osteoarthritis includes physiotherapy, non-steroidal anti-inflammatory drugs and intra-articular injections (corticosteroid, platelet-rich plasma and hyaluronic acid). Total hip replacement is certainly an effective treatment but burdened with a non-negligible complication rate. Stem cell therapy represents a potential alternative for the treatment of patients with osteoarthritis.

The authors performed a systematic review with the aim to analyze all clinical studies investigating the safety and efficacy of intra-articular mesenchymal stem cell injections for hip osteoarthritis. Nine studies satisfied inclusion criteria and were included in the review.

The most important element that emerges from this analysis is that at the moment there is a lot of heterogeneity in the type of mesenchymal stem cells used (adipose versus medullary), in the site of collection and in the number of injections performed. The clinical results are overall satisfactory in the short follow-up (3-30 months, average 13.6 months). All the studies examined showed considerable clinical effectiveness in controlling pain and improving the functionality of patients with hip osteoarthritis in the short follow-up. Three of these studies demonstrated superiority in terms of duration of pain relief respect to standard therapies (injections of platelet-rich plasma and hyaluronic acid). From all this emerges the need to perform randomized controlled trials to evaluate the efficacy of mesenchymal stem cells compared to validated infiltrative treatments with platelet-rich plasma and hyaluronic acid.

Keywords : mesenchymal stem cell ; hip osteoarthritis ; adipose stem cell.

INTRODUCTION

Hip osteoarthritis (OA) affects 8.7% of men and 9.3% of women over the age of 45 in the United States (1). During the aging process the chondrocytes, which contribute to 5% of the articular cartilage volume, progressively reduce their regenerative capacity with a reduction in the production of proteoglycans and type 2 collagen and of articular cartilage (2).

Treatment of hip OA includes physiotherapy, non-steroidal anti-inflammatory drugs (NSAIDs) and intra-articular injections (corticosteroid, hyaluronic acid and platelet-rich plasma). Several studies have shown an excellent effectiveness of infiltrative treatments without being able to prevent the progressive wear of cartilage (3,4).

Total hip replacement (THR) is certainly an effective treatment but burdened with a non-negligible complication rate (dislocation, infection, pulmonary thromboembolism and in some cases death (5-7)). A recent study shows that 7-23% of THR patients may experience chronic pain after surgery

■ Alessio Biazzo,
■ Francesco Masia,
■ Francesco Verde
Humanitas Gavazzeni, Orthopedic Department, Bergamo, Italy.

Correspondence : Alessio Biazzo, via Gavazzeni 21, Bergamo 24125, Italy.

Email : ale.biazzo@yahoo.it

© 2020, Acta Orthopaedica Belgica.

(5). From this non-negligible rate of complications and chronic post-surgery pain the need arises to find alternative treatments to surgery.

Stem cell therapy represents a potential alternative for the treatment of patients with OA, cartilaginous defects and soft tissue injuries (8-11). The mesenchymal stem cells (MSC) are cells of mesodermal origin and represent the precursors of bone, cartilage, muscle and adipose tissue (12). The MSCs can be taken from bone marrow and from fat : in particular in the adipose tissue they represent up to 2% of the cell count in comparison to 0.02% of the bone marrow (13-16).

The infiltrative treatment with MSCs exerts its therapeutic effect through 3 different mechanisms : a natural anti-inflammatory effect, an immediate mechanical lubricating effect and a secondary biological effect thanks to the secretion of angiogenic, antiapoptotic and immunomodulatory factors (paracrine effect) (2). Recent in vitro studies have shown that MSCs can initiate the repair process

by influencing local cells through a paracrine communication mechanism, although the real in vivo therapeutic mechanism has not yet been demonstrated (17).

The objective of this review is to analyze all clinical studies investigating the safety and efficacy of intra-articular MSC therapy for hip OA.

METHODS

There was no registered protocol. The following search terms were used in PUBMED, EMBASE and the Cochrane Library Database on 24th May 2019 : “Stem cell therapy AND hip ; adipose stem cell AND hip ; bone marrow concentrate AND hip ; bone marrow injection AND hip ; stem cell injection AND hip ; stem cell AND hip”. No time limit was given to publication date.

Two reviewers independently carried out the initial search screening the titles and abstracts for relevance. We included all studies based on the

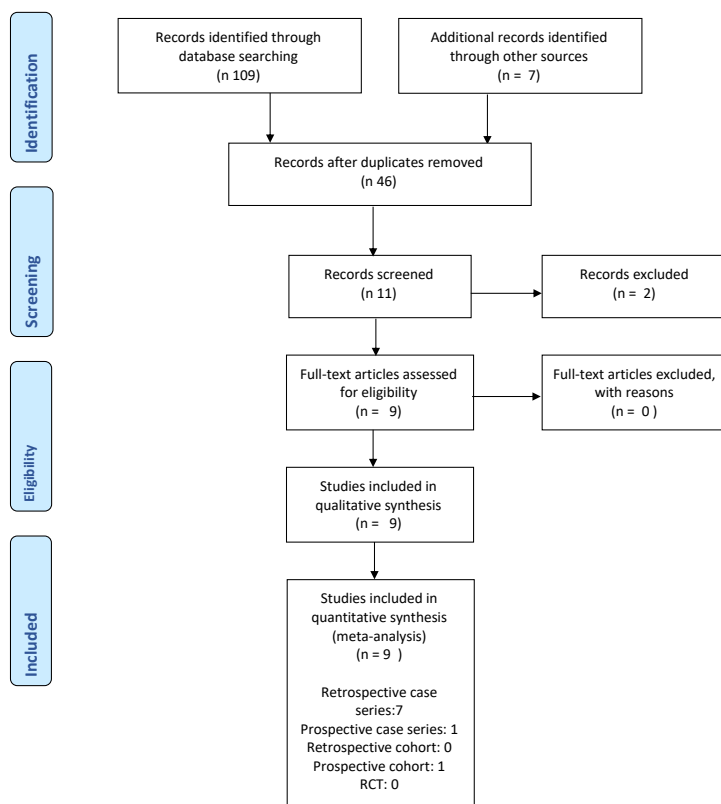


Figure 1. — Flow-chart describing literature evaluation methods.

following criteria : (1) English studies ; (2) patient population diagnosed with hip OA and treated with MSC injections alone or in comparison with hyaluronic acid (HA) or platelet-rich plasma (PRP).

The following data were collected : first author, year of publication, number of patients, stem cell type, follow-up, functional outcomes and adverse events.

RESULTS

The initial search identified 116 records. After examination of titles and abstracts, there were 9 full-text papers that satisfied all inclusion criteria and were included in this systematic review. There were 7 retrospective case-series, 1 prospective case-series and 1 prospective cohort study (Figure 1).

For adipose stem cells (ADSCs), liposuction and injections were performed in the same surgical stage in both studies (2,18), one using mechanical fraction and one using enzymatic digestion.

Both studies used the abdomen as harvesting site for ADSCs. None of the studies reported the average volume of harvested adipose tissue or the cell count. Dall'Oca et al. (2) performed one single injection, while Pak et al. (18) performed the first injection with a mixture of ADSCs, PRP and HA as scaffold, then performed other four additional autologous PRP injections each week over one month period.

For bone marrow cells (BMCs) there was much more heterogeneity in the harvested site, preparation and number of injections. Darrow et al. (1) used the posterior superior iliac spine (PSIS) to harvest the BMCs, which were then centrifugated and injected into the hip joint during the same procedure, followed by other 3 injections approximately 14 days apart. Rodriguez-Fontan et al. (19) used the anterior superior iliac crest (ASIC) as harvesting site ; then the BMCs were centrifugated and injected into the hip joint in the same stage. Hauser et al. (20) used tibial whole bone marrow (WBM) in combination with hyperosmotic dextrose in all cases except one in which they used the tibial and posterior iliac bone marrow. The number of injections were between 2 and 7. Mardones et al. (21) used ex-vivo expanded bone marrow-derived mesenchymal stem cells (BM-MS) harvested from the PSIS of each patients and

treated the affected hip with 3 injections, starting the same day of aspiration and with other 2 injections at 7 and 14 days after treatment. Cell count was approximately of 20×10^6 ex-vivo expanded BM-MS. Centeno et al. (22) in the first study in 2006 used BMC harvested from the PSIS and performed the first injection using BMC added with HA and the second injection one month apart added with PRP. In 2014 the same group performed the largest study using BMC harvested from the PSIS and added with autologous PRP (23). Average cell count was reported to be $527,4 \times 10^6$. Emadedin et al. (24) used expanded ex-vivo BM-MS harvested from the iliac crest and injected 7 days after aspiration.

Studies' characteristics are reported in Table I and II.

In 2006 Centeno et al. (22) reported the first case-report about MSC treatment of hip OA : they presented a 64-year-old male with a 20-year history of unilateral hip pain and diagnosed with hip OA. He was treated with 2 injections of bone marrow nucleated cells one month apart and added with HA and PRP. At 3-month follow-up the Authors reported one level improvement in travel, recreation and standing tolerance and 2 levels improvement in walking distance and sitting tolerance. The 4 week post-procedure Magnetic Resonance Imaging (MRI) demonstrated an improvement of the joint space. In 2013 Pak et al. (18) presented a case-series of 100 joints (knee, hip, ankle, low back) treated with ADSCs + PRP and HA : of them, 22 were hips, of which 15 were affected by avascular osteonecrosis and 7 by OA. At the last follow-up (26 months) the Authors reported a significative improvement of the VAS score (6,55 pre-treatment versus 4,43 post-treatment).

In 2013 Hauser et al. (20) reported the results of 5 OA hips treated with WBM harvested from the iliac crest or tibia. All patients experienced significant gains in the treatment periods of 2-12 months. Centeno et al. (23) in 2014 presented the results of a multicenter study with 216 OA hips treated with BMC injections. At the last follow-up at 6 months they administered VAS and Oxford Hip Score (OHS) and their multivariate analysis showed better results for patients aged < 55 years. Outcomes were good and statistically significant

Table I-II. — Studies' characteristics and general data.

Author	Study design	Patients receiving MSC therapy, No.	Cell source	Mean No. of injected Cells x 10	No. of injections	Adjuvant	Control group
Rodriguez-Fontan (2018)	Prospective cohort study	19 patients (10 knees, 15 hips)	BMC	N/A	2	None	None
Emadedin (2015)	Retrospective case-series	17 patients (6 knees, 6 ankles, 5 hips)	BMC	5 x 10 (5) seven days after culture	1	None	None
Mardones (2017)	Retrospective case-series	10 patients, 10 hips	BMC	20 x 10 (6)	3	None	None
Pak (2013)	Retrospective case-series	91 patients (7 OA hips)	ADSC + PRP	N/A	1 of ADSC and 5 of PRP	PRP	None
Dall'Oca (2019)	Retrospective case-series	6 patients, 6 hips	ADSC	N/A	1	None	None
Centeno (2014)	Retrospective multicenter study	196 (216 hips)	BMC	N/A	1	PRP	None
Centeno (2006)	Case-report	1 hip	BMC	N/A	1	PRP + HA	None
Darrow (2018)	Retrospective case-series	4 hips	BMC	N/A	4	None	None
Hauser (2013)	Retrospective case-series	3 patients (5 hips)	WBM	N/A	2 to 7	PRP	None

Author	Clinical outcomes measure	Outcome scores	Significant difference	Adverse events	Notes
Rodriguez-Fontan (2018)	WOMAC	40,8 baseline vs 20,6 at final FU	p < 0,001	11/19: pain and swelling	Outcomes
Emadedin (2015)	VAS	4,7 baseline vs 1,7 at 12 ms, then increase	p < 0,002 at 12 months, p > 0,05 at final FW	N/A	Outcomes
	WOMAC	45,2 at baseline, 27,9 at 6 ms, 26,3 at 12 ms, 29,1 at final FU	p < 0,05	-	-
	HHS	57 at baseline, 79,8 at 6 ms	p < 0,05	-	-
Mardones (2017)	VAS	4,2 at baseline, 1,1 at final FU	p < 0,0001	N/A	-
	WOMAC	34,5 at baseline, 19,2 at final FU	p = 0,15	-	-
	HHS	61,9 at baseline, 85,7 at final FU	p < 0,003	-	-
	VAIL Hip score	61,2 at baseline, 78,2 at final FU	p < 0,02	-	-
Pak (2013)	VAS	6,55 at baseline, 4,43 at final FU	N/A	Pain-swelling (37%); tendonitis (22%); skin rash (1%)	Outcomes
Dall'Oca (2019)	VAS	4,6 at baseline, 1,5 at final FU	p < 0,0001	1 abdominal haematoma	-
	HHS	67,2 at baseline, 84,6 at final FU	p < 0,0001	-	-
	WOMAC	36,3 at baseline, 19,8 at final FU	p < 0,0001	-	-
Centeno (2014)	OHS	26,6 at baseline, 33 at final FU	p < 0,001	12 AEs (pain-swelling, skin rash)	OHS data w
	VAS	4,5 at baseline, 3,3 at final FU	p < 0,001	-	VAS data w
Centeno (2006)	HHS	50,8 at baseline, not reported at final FU	N/A	None	-
Darrow (2018)	VAS	5,8 at baseline, 1,8 at final FU	N/A	None	-
	LEFS	27,8 at baseline, 35,3 at final FU	N/A	None	-
Hauser (2013)	VAS	6,1 at baseline, 0,07 at final follow-up	N/A	None	-

(p < 0,05) for both OHS and VAS score with 6,4 points of improvement for OHS and 1,2 points improvement for VAS score. Emadedin et al. (24) in 2015 treated 18 patients affected by knee, ankle

or hip OA with BMC injections, of which 5 were hips : they obtained good results with a statistical significance for VAS, Western Ontario and McMaster Universities Arthritis Index (WOMAC)

and Harris Hip Score (HHS) only during the first 12 months ($p < 0,05$). At the last follow-up (30 months) outcomes decreased but remained good. In 3 out of 5 hip patients MRI showed articular cartilage repair 6 months after BMCs injections. Mardones et al. (21) in 2017 treated 10 patients affected by hip OA with expanded ex-vivo autologous BMC injections. At the last follow-up (average 16-40 months) VAS, HHS and VAIL hip scores showed statistical significant improvement ($p < 0,05$) with no complications reported. One out of 10 patients reported an improvement in the radiographic score (Tonnis grade). More recently, in 2018, Rodriguez-Fontan et al. (19) treated with BMC injections 15 hips affected by early OA. At an average follow-up of 13 months 63% of patients were satisfied ; WOMAC score showed significant results ($p < 0,05$) at 6 month follow-up, but at final follow-up there was no improvement. Two patients were converted to THR at 8 months after BMC injections. Darrow et al. (1) in 2018 presented the results of 4 hips affected by OA and treated with 4 BMC injections ; at the last follow-up (3,5 months after the first injection) all patients experienced at least 60% total improvement following treatment and all patients reported that they were able to perform their daily activities.

In 2019 Dall'Oca et al. (2) presented the outcomes of 6 OA hips treated with ADSCs injections. The HHS, VAS and WOMAC score at 6 month follow-up were statistically significant respect to baseline ($p < 0,05$). No patients had post-operative major complications.

Two studies did not mention adverse events (21,24). One reported pain and swelling in 11 out of 19 patients (19). Three studies did not report adverse events (1,20,22). Pak et al. (18) had pain and swelling in 37% and tendonitis in 22% of patients. Dall'Oca et al. (2) reported 1 abdominal hematoma. Centeno et al. (23) had pain and skin rash in 12 out of 196 patients. No cases of tumor were reported.

The most important problem in identifying adverse events in such studies is that in some of these papers there is no selection between knees and hips ; therefore we cannot understand if the AEs reported are related to the knee group or hip group.

DISCUSSION

The most important element that emerges from this analysis is that at the moment there is a lot of heterogeneity in the type of MSCs used (adipose versus medullary), in the site of collection and in the number of injections performed.

The results of the 9 studies described in the present review are difficult to extrapolate to a larger scale for a number of reasons, the most important the lack of control groups and the small number of patients treated.

The clinical results are overall satisfactory in the short follow-up (3-30 months, average 13.6 months).

Despite positive findings, the use of different adjuvants in some studies – including PRP and HA – limits the ability to determine the specific effect of MSCs injections.

The outcomes of some of the 9 studies examined in this review are superior in terms of duration compared to standard treatments with PRP and HA, whose benefit is estimated to be no more than 12 months (25). Several studies in the literature attested to the efficacy of PRP and HA in the treatment of initial-moderate hip OA, but all had a short follow-up, not exceeding 12 months (26-28) ; only Migliore et al. (29) reported benefits at 24 months of injective treatment with HA. In particular, the studies of Mardones (21), Emadedin (24) and Rodriguez-Fontan (19) all had a follow-up of more than 12 months. Emadedin et al. (24) treated 18 patients suffering from OA of the knee, ankle and hip by injection with BMCs, for a total of 5 hips treated. The results evaluated by VAS, WOMAC and HHS were statistically significant up to the 12th month ($p < 0.05$), then they have decreased up to the 30th month remaining good. Mardones et al. (21) treated 10 patients with hip OA with BMC injections ; at the average follow-up of 27.9 months (range 16-40 months) the results, evaluated by VAS, HHS and Vail hip, showed a statistically significant improvement ($p < 0.05$). Rodriguez-Fontan et al. reported the results of 15 hips affected by OA and treated with 2 injections with BMCs ; the results, evaluated with the WOMAC scale, were statistically significant both at 6 months and at the last follow-up, without

significant differences between the 6th and 13th month. These 3 studies showed superiority in terms of duration of treatment compared to standard therapies based on PRP and HA and above all they did not use adjuvants.

The first bias in some of these studies is that different joints like knee, hip and ankle are treated, mixing the results obtained. Only a few studies focus on the arthritic pathology of the hip and are those of Mardones (21), Dall'Oca (2), Centeno (22,23) and Darrow (1).

The second bias is the use of adjuvants such as PRP and HA, which can alter the results. In particular, 4 out of 9 studies used PRP or HA. Centeno et al. in both studies (22,23) used adjuvants ; Pak et al. (18) and Hauser et al. (20) used PRP.

The third bias is represented by the technique used to inject the MSCs. The infiltrative techniques are often different (ultrasound-guided vs fluoroscopy) and this can alter the results, being known that the most accurate and precise method is the ultrasound technique.

The fourth bias is represented by the heterogeneity in the arthritic degree of treated patients. Some studies treated patients who are candidates for hip replacement but who refused surgery ; in these patients the results may be lower than expected and alter the average values of patients with initial-moderate arthritis, who are the real candidates for these treatments.

The fifth bias is given by the small sample of patients treated : except for the study by Centeno et al. (23), with a total of 196 patients and 216 hips treated, all studies have a maximum of 15 hips treated.

CONCLUSION

All the studies examined showed considerable clinical effectiveness in controlling pain and improving the functionality of patients with hip OA in the short follow-up. Three of these studies demonstrated superiority in terms of duration of treatment respect to standard therapies (injections of PRP and HA), demonstrating a benefit that lasted over the 12 months. None of these studies showed any serious adverse events or cancer cases, demonstrating the clinical safety of such treatments.

However, significant biases emerge, such as the use of adjuvants (PRP or HA), the limited number of patients treated, and the heterogeneity of the arthritic degree of treated patients, including patients with indication for THR.

From all this emerges the need to perform studies with standardized tools, in the absence of local adjuvants and above all RCTs to evaluate the efficacy of MSCs compared to validated infiltrative treatments with PRP and HA.

REFERENCES

1. **Darrow M, Shaw B, Darrow B, Wisz S.** Short-Term Outcomes of Treatment of Hip Osteoarthritis With 4 Bone Marrow Concentrate Injections : A Case Series. *Clin. Med. Insights Case Rep.* 2018 Aug 10 ; 11 : 1179547618791574.
2. **Dall'Oca C, Breda S, Elena N, Valentini R, Samaila EM, Magnan B.** Mesenchymal Stem Cells injection in hip osteoarthritis : preliminary results. *Acta Biomed.* 2019 Jan 10 ; 90(1-S) : 75-80.
3. **Micu MC, Bogdan GD, Fodor D.** Steroid injection for hip osteoarthritis : efficacy under ultrasound guidance. *Rheumatology (Oxford).* 2010 Aug ; 49(8) : 1490-4.
4. **Qvistgaard E, Christensen R, Torp-Pedersen S, Bliddal H.** Intra-articular treatment of hip osteoarthritis : a randomized trial of hyaluronic acid, corticosteroid, and isotonic saline. *Osteoarthritis Cartilage.* 2006 Feb ; 14(2) : 163-70.
5. **Beswick AD, Wylde V, Gooberman-Hill R, Blom A, Dieppe P.** What proportion of patients report long-term pain after total hip or knee replacement for osteoarthritis? A systematic review of prospective studies in unselected patients. *BMJ Open.* 2012 Feb 22 ; 2(1) : e000435.
6. **Lewinnek GE, Lewis JL, Tarr R, Compere CL, Zimmerman JR.** Dislocations after total hip-replacement arthroplasties. *J. Bone Joint Surg. Am.* 1978 Mar ; 60(2) : 217-20.
7. **Mahomed NN, Barrett JA, Katz JN et al.** Rates and outcomes of primary and revision total hip replacement in the United States medicare population. *J. Bone Joint Surg. Am.* 2003 Jan ; 85(1) : 27-32.
8. **Kuroda R, Ishida K, Matsumoto T et al.** Treatment of a full-thickness articular cartilage defect in the femoral condyle of an athlete with autologous bone-marrow stromal cells. *Osteoarthritis Cartilage.* 2007 Feb ; 15(2) : 226-31.
9. **Lee KB, Wang VT, Chan YH, Hui JH.** A novel, minimally-invasive technique of cartilage repair in the human knee using arthroscopic microfracture and injections of mesenchymal stem cells and hyaluronic acid--a prospective comparative study on safety and short-term efficacy. *Ann. Acad. Med. Singapore.* 2012 Nov ; 41(11) : 511-7.

10. **Nejadnik H, Hui JH, Feng Choong EP, Tai BC, Lee EH.** Autologous bone marrow-derived mesenchymal stem cells versus autologous chondrocyte implantation : an observational cohort study. *Am. J. Sports Med.* 2010 Jun ; 38(6) : 1110-6.
11. **Thomas RJ, Hourd PC, Williams DJ.** Application of process quality engineering techniques to improve the understanding of the in vitro processing of stem cells for therapeutic use. *J. Biotechnol.* 2008 Sep 10 ; 136(3-4) : 148-55.
12. **Reichenbach S, Blank S, Rutjes AW et al.** Hyaluronic acid for osteoarthritis of the knee : a systematic review and meta-analysis. *Arthritis Rheum.* 2007 Dec 15 ; 57(8) : 1410-8.
13. **Damia E, Chicharro D, Lopez S et al.** Adipose-Derived Mesenchymal Stem Cells : Are They a Good Therapeutic Strategy for Osteoarthritis? *Int. J. Mol. Sci.* 2018 Jun 30 ; 19(7).
14. **Coughlin RP, Oldweiler A, Mickelson DT, Moorman CT 3rd.** Adipose-Derived Stem Cell Transplant Technique for Degenerative Joint Disease. *Arthrosc. Tech.* 2017 Oct 2 ; 6(5) : e1761-e1766.
15. **Cattaneo G, De Caro A, Napoli F, Chiapale D, Trada P, Camera A.** Micro-fragmented adipose tissue injection associated with arthroscopic procedures in patients with symptomatic knee osteoarthritis. *BMC Musculoskelet. Disord.* 2018 May 30 ; 19(1) : 176.
16. **Dall'Oca C, Cengarle M, Costanzo A, Giannini N, Vacchiano A, Magnan B.** Current concepts in treatment of early knee osteoarthritis and osteochondral lesions ; the role of biological augmentations. *Acta Biomed.* 2017 Oct 18 ; 88(4S) : 5-10.
17. **Caplan AI, Dennis JE.** Mesenchymal stem cells as trophic mediators. *J. Cell. Biochem.* 2006 Aug 1 ; 98(5) : 1076-84.
18. **Pak J, Chang JJ, Lee JH, Lee SH.** Safety reporting on implantation of autologous adipose tissue-derived stem cells with platelet-rich plasma into human articular joints. *BMC Musculoskelet. Disord.* 2013 Dec 1 ; 14 : 337.
19. **Rodriguez-Fontan F, Piuzzi NS, Kraeutler MJ, Pascual-Garrido C.** Early Clinical Outcomes of Intra-Articular Injections of Bone Marrow Aspirate Concentrate for the Treatment of Early Osteoarthritis of the Hip and Knee : A Cohort Study. *PM R.* 2018 Dec ; 10(12) : 1353-1359.
20. **Hauser RA, Orlofsky A.** Regenerative injection therapy with whole bone marrow aspirate for degenerative joint disease : a case series. *Clin. Med. Insights Arthritis Musculoskelet. Disord.* 2013 Sep 4 ; 6 : 65-72.
21. **Mardones R, Jofré CM, Tobar L, Minguell JJ.** Mesenchymal stem cell therapy in the treatment of hip osteoarthritis. *J. Hip Preserv. Surg.* 2017 Mar 19 ; 4(2) : 159-163.
22. **Centeno CJ, Kisiday J, Freeman M, Schultz JR.** Partial regeneration of the human hip via autologous bone marrow nucleated cell transfer : A case study. *Pain Physician.* 2006 Jul ; 9(3) : 253-6.
23. **Christopher J Centeno, John A Pitts, Hasan Al-Sayegh, Michael D Freeman.** Efficacy and Safety of Bone Marrow Concentrate for Osteoarthritis of the Hip ; Treatment Registry Results for 196 Patients *J. Stem. Cell Res. Ther.* 2014, 4 : 10
24. **Emadedin M, Ghorbani Liastani M, Fazeli R et al.** Long-Term Follow-up of Intra-articular Injection of Autologous Mesenchymal Stem Cells in Patients with Knee, Ankle, or Hip Osteoarthritis. *Arch. Iran Med.* 2015 Jun ; 18(6) : 336-44.
25. **Ye Y, Zhou X, Mao S, Zhang J, Lin B.** Platelet rich plasma versus hyaluronic acid in patients with hip osteoarthritis : A meta-analysis of randomized controlled trials. *Int. J. Surg.* 2018 May ; 53 : 279-287.
26. **Battaglia M, Guaraldi F, Vannini F et al.** Efficacy of ultrasound-guided intra-articular injections of platelet-rich plasma versus hyaluronic acid for hip osteoarthritis. *Orthopedics.* 2013 Dec ; 36(12) : e1501-8.
27. **Dallari D, Stagni C, Rani N et al.** Ultrasound-Guided Injection of Platelet-Rich Plasma and Hyaluronic Acid, Separately and in Combination, for Hip Osteoarthritis : A Randomized Controlled Study. *Am. J. Sports Med.* 2016 Mar ; 44(3) : 664-71.
28. **Doria C, Mosele GR, Caggiari G, Puddu L, Ciurlia E.** Treatment of Early Hip Osteoarthritis : Ultrasound-Guided Platelet Rich Plasma versus Hyaluronic Acid Injections in a Randomized Clinical Trial. *Joints.* 2017 Aug 11 ; 5(3) : 152-155.
29. **Migliore A, Granata M, Tormenta S et al.** Hip viscosupplementation under ultra-sound guidance reduces NSAID consumption in symptomatic hip osteoarthritis patients in a long follow-up. Data from Italian registry. *Eur. Rev. Med. Pharmacol. Sci.* 2011 Jan ; 15(1) : 25-34.