



Long-term outcome of cementless total hip arthroplasty with threaded Tropic® acetabular cup and Corail® femoral stem

Fernando ALMEIDA, Silvia GÁLLEGO, Francisco ARGÜELLES, Antonio SILVESTRE

From the Department of Orthopedic Surgery, Clinic University Hospital of Valencia, Valencia, Spain

This study investigates the clinical and radiological results of a tapered femoral stem (Corail®) and uncemented threaded acetabular cups (Tropic®) and in addition an analysis of the complications and retrieved implants was conducted. Between January 1990 and September 1998, 301 total hips arthroplasties in 268 patients were implanted. 78 patients (87 hips) had died and 9 patients (12 hips) had been lost to follow-up, leaving at the time of the latest follow-up 180 patients (202 hips). The mean age at surgery was 56,1 (27-75) years. Of the 154 unrevised hips, the median Harris and Merle d'Aubigne and Postel hip scores were 83,3 points and 15,3 points respectively at the latest follow-up. The median follow-up time was 16.9 years (10,4-25). No femoral component was revised for aseptic loosening ; osteolysis was observed in the 9,5% of the implants (13 stems). 48 hips (23%) were revised and 27 cups (56,2%) needed revision surgery because of massive polyethylene wear. Pelvic osteolysis was found out in 80 cups (58,8%). 87 hips (63,9%) showed signs of a progressive wear of the liner, more than 2mm in 48 hips. Kaplan-Meier survivorship analysis at 15 years follow-up was 81.2% with revision for any reason (85.8% for mechanical or radiographic loosening). High rates of polyethylene wear and the high prevalence of pelvic osteolysis are serious matters in these types of implants with high rates of revision at 15 years follow-up so we decided to abandon the concept of a threaded cup design in favor of a press-fit acetabular cup.

Key words : Adult ; arthroplasty ; replacement ; hip ; treatment outcome.

INTRODUCTION

The concept of an extensive HA coating for the fixation of a tapered femoral stem (Corail®) was introduced in the 1990s, which can achieve durable biological fixation and preserve normal periprosthetic bone activity (1)

Cementless cups were introduced to improve the results of cemented hip arthroplasty. Primary acetabular stability is obtained by inserting components by the use of a threaded cup or by press-fit system and the osseointegration is improved by a surface finish with hydroxyapatite. Only a few mid-terms and almost no long-term results of threaded HA coated cups have been reported (2)

The aim of our study was prospectively to determine the long-term (more than a mean of 15 years follow-up) outcome of this group treated with

-
- Fernando Almeida ^{1,2},
 - Silvia Gállego ^{1,2},
 - Francisco Argüelles ^{2,3},
 - Antonio Silvestre ^{1,2}

¹Department of Orthopedic Surgery, Clinic University Hospital of Valencia, Valencia, Spain.

²Department of Surgery, Orthopedic Valencia University School of Medicine, Valencia, Spain.

³Department of Orthopedic Surgery, La Fe University Hospital of Valencia, Valencia, Spain.

Correspondence : Fernando Almeida, Av Maestro Rodrigo 105 21, 46015, Valencia, Spain.

Email : falmeidah@gmail.com

© 2021, Acta Orthopædica Belgica.

a cementless hydroxyapatite femoral component (Corail®) and a calcium HA-coated threaded cup (Tropic®). Therefore, we evaluated the clinical and radiographic outcome of a consecutive multi-surgeon series of 202 patients.

MATERIALS AND METHODS

The study comprised a series of 301 primary total hip arthroplasties implanted between January 1990 and September 1998 using a cementless hydroxyapatite-coated femoral component and threaded cup Corail®-Tropic® (Landos Biomecanique) with high-molecular-weight-polyethylene insert and a ceramic head of 28mm (Biolox®) in 268 patients. During the follow-up period, 78 patients with 87 hips had died and 9 patients with 12 hips were lost, leaving at the time of the latest follow-up 180 patients (202 hips). 22 of the patients had bilateral THAs. There were 113 women and 89 men and the mean age at surgery was 56 (27-75) years. Radiological data were obtained for 136 hips. Clinical data but no radiographics were obtained for 154 hips (Figure 1).

The femoral component was cementless, hydroxyapatite (HA ; 98% calcium hydroxyapatite, 2% tricalcium phosphate) coated applied to the entire stem, wrought of titanium alloy (Corail®, Landos Biomecanique, Switzerland). It had a cervicodiaphyseal angle of 135° and had proximal horizontal ridges and distal vertical grooves to provide stability and promote bone ingrowth. The

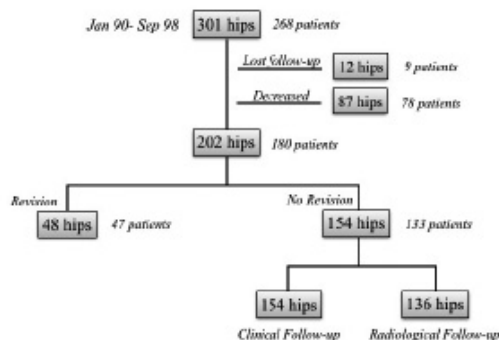


Figure 1. — Distribution of hips with Corail stem and Tropic cups at a mean of 15 years of follow-up.

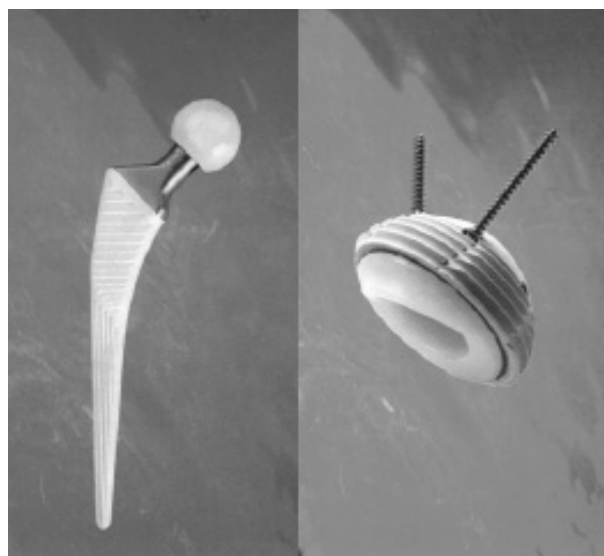


Figure 2. — Hydroxyapatite-coated femoral component Corail® and threaded cup Tropic® (Landos Biomecanique).

proximal part is flared in the sagittal and the coronal plane to provide three-dimensional stabilization in the metaphyseal area. The distal portion has a tapered design, to produce a stiffness gradient and to avoid medullary canal blocking. The shortened taper, the high offset, and varus options were also the features. A 28-mm ceramic head (Biolox® ; Landanger, Chaumont, France) was used in all patients, fixed on a 12/14mm taper.

The titanium-alloy, porous, calcium HA-coated, threaded cup (Tropic®, Landos Biomecanique, Switzerland) had 6 screw holes for maximized stability. Its ultrahigh-molecular-weight polyethylene insert with a 10° liner was securely locked with 4 tabs to enhance hip stability and prevent liner dissociation from the shell (Figure 2).

The indications of surgery in the 180 patients included osteoarthritis of the hip in 106 cases (58,9%), avascular necrosis in 36 (20%) and after fracture of femoral neck in 10 cases (5,6%). The remaining diagnosis are listed in Table I.

10 hips had been operated on previously : 4 for osteosynthesis (for femoral neck fractures), 2 for proximal femoral osteotomies, 2 for minimally invasive drilling procedure (Forage), one for arthrodesis and one soft-tissue surgery.

All operations were performed by three 3 orthopaedic surgeons with a specialist in arthroplasty

Table I. — Initial diagnosis of 202 primary total hip arthroplasties in 180 patients

DIAGNOSIS	N: 180	%
Primary osteoarthritis	106	58,9
Avascular necrosis	36	20
Neck femoral fracture	10	5,6
Developmental dysplasia	8	4,4
Ankylosing spondylitis	7	3,9
Septic arthritis	5	2,7
Arthritis secondary to neck femoral fracture	2	1,1
Juvenile chronic arthritis	2	1,1
Rheumatoid arthritis	2	1,1
Legg Perthes disease	1	0,6
Psoriatic arthritis	1	0,6

using a posterolateral approach. Templates was used preoperatively to determine the cup size, the femoral size and the neck geometry. Intra-operatively, 2 hips sustained fractures of the proximal femur and were stabilized by wires. Another 2 sustained iatrogenic fractures of the calcar but no osteosynthesis was undertaken. One sustained an acetabular fracture for which reason and full-weight bearing was delayed. The mean time to full-weight bearing was 7 (range, 3-27) days. Autogenous bone grafts were used for segmental acetabular defects in 5 hips (2 for developmental dysplasia and 3 for severe osteoarthritis). Antibiotic prophylaxis with intravenous cefazoline was given, and anti-thrombotic prophylaxis entailed subcutaneous low-molecular-weight heparin started on the night after surgery and continued for 6 weeks. The closed suction drain was removed 24 hours after surgery. The process of rehabilitation was adjusted to each patient's clinical course, early and full weight-bearing was encouraged after surgery.

Patients were clinically evaluated by 2 independent observers (FAH/FAL) in an outcome check-up or by a telephone interview and a questionnaire, using the Harris Hip Score and D'Aubigne and Postel score. The presence of thigh pain, weight-bearing and the use of external supports (walker, crutches or canes) were recorded. 154 hips were clinically evaluated, 148 hips were assessed in an outpatient setting, and 6 were evaluated by a questionnaire via a telephone interview.

Anteroposterior (AP) and true lateral radiographs were evaluated by a single independent orthopaedic

surgeon, so as to avoid inter-observer variability. Radiolucency and stress shielding of the stem were classified according to Gruen classification (3). Osteolysis was estimated using Goetz criteria (4) and radiolucent lines at the cup were analyzed according to the zones described by DeLee and Charnley (5). Pelvic osteolysis was defined as a round or oval area of bone loss. The abduction angle and covering of the cup were checked. Migration (vertical or horizontal) was evaluated, according to Massin et al (6). The acetabular component was considered loosened when migration was >3 mm or the abduction angle changed >4°.

Heterotopic ossification was classified according to the criteria of Brooker et al (7). Sclerosis at the tip of the prosthesis, pedestal sign, calcar changes, resorption of the proximal femur, reduction of density in the trochanteric region were recorded, as were the Voss effect (positive if the tip of the great trochanter was higher than the femoral head centre, negative if lower, and neutral if the same) and limb-length discrepancy. Liner wear was considered remarkable if the gaps from the superior margin of the cup to the edge of the femoral head and from the inferior margin to the femoral head were >2 mm (8).

Follow-up duration was defined as the date of operation to the date of last follow-up. The minimum follow-up was 10,4 years (mean 16,9, 10,4-25 years).

The survival curves of the femoral and acetabular components were drawn according to the Kaplan-Meier method, and the survivorship was defined as revision for any reason and for aseptic loosening or excessive polyethylene wear (9).

RESULTS

After a minimum follow-up of 10,4 years, 48 (23%) hips were revised, of which 27 (56,2%) were for the cup. The causes for revision were aseptic loosening (n=5, 2 exchanged the cup, 1 exchanged femoral component and 2 both components), polyethylene wear (n=27), late deep infections (n=5, all of them performed in 2 stages), dislocation (n=3), periprosthetic fractures (n=7, treatment) and one acetabular cup breakage. No fracture of the ceramic head was noted.

At the final follow-up in the 154 unrevised hips, the mean Harris Hip Score was 83 (range, 78-95). Clinical outcome was excellent in 105 hips, good in 42, fair in 6, and poor in one (this patient had a previous osteotomy and sustained an intra-operative proximal femoral fracture). The mean D'Aubigne and Postel score was 15.3 (range, 9-18). Clinical outcome was excellent in 110 hips, good in 29, fair in 13 and poor in 2.

Regarding the 154 unrevised hips (133 patients), 97 had no pain, 33 had slight or occasional pain not affecting daily activities, 2 had mild pain, and one had severe pain. Regarding these 133 patients with unrevised hips, 102 could walk without a limp, 28 had a slight limp, and 3 had a moderate limp and used a cane.

Of the 136 hips available for radiological review, stem alignments of 126 were neutral, 8 were varus, and 2 were valgus. 48 hips had decreased bone density at the great trochanter, whereas 23 hips had changes in the calcar. Only 12 hips had a pedestal sign on the stem. 133 hips showed bone ingrowth on the stem, 3 had a stable fibrous ingrowth, and none was unstable. The Voss effect was positive in 23 hips, negative in 23, and neutral in 90.

Radiolucent lines adjacent to the stem were noted in 14 hips ; 15 had them in zone 5, 12 in zone 1, 11 in zone 7, 10 in zone 3, 9 in zone 6, 4 in zone 2, and 2 in zone 4. Mild and intermediate osteolysis occurred in 17 and 11 hips, respectively (Figure 3A). Cortical hypertrophy was noted in 17 hips, often in zones 6 and 7, less often in zones 5, 2, and 3, and none in zones 1 and 4. Half of these hips with

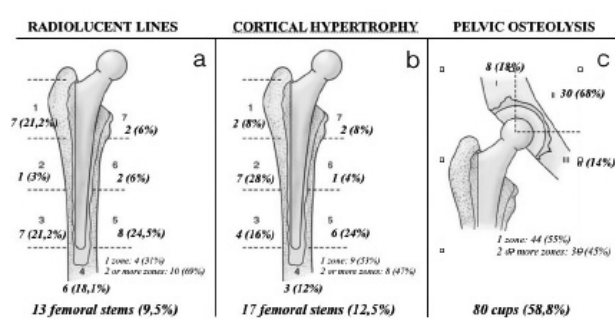


Figure 3. — Radiolucent lines (A) and Cortical hypertrophy (B) in femoral stems with use of zones described by Gruen. Pelvic osteolysis (C) in cups according the zones described by DeLee and Charnley.

hypertrophy involved one zone and half involved >1 zone (Figure 3B).

Grade 4 heterotopic ossification was found in 6 hips, grade 3 in 3, grade 2 in 37 grade 1 in 12, and none in 108. In clinical follow-up, regarding the 136 unrevised hips, no leg length discrepancies were found in 83,8% of patients (n=114). In 22 hips a leg length difference was found, 15 had a mean of 8 (range, 3-12) mm positive dysmetria, and 17 had a mean of 7 (range, 5-14) mm negative dysmetria.

The mean abduction angle of the cup was 52° (range, 32-78°). 103 hips showed proper covering of the cup, and 33 showed poor covering owing to anomalies in the acetabulum. Radiolucent lines were noted in 80 cups ; 10 occurred in zone 1, 17 in zone 2, and 6 in zone 3. Osteolysis involved one zone in 15 hips and 2 zones in 9 ; 3-zone involvement was not encountered (Figure 3C).

Besides the 27 liners exchanged, 87 hips showed signs of polyethylene wear ; 48 were >2 mm (Figure 4).

The Kaplan-Meier survival analysis, with the end-point being revision of any component for any reason, estimated the 15-year survival rate at 81.2% (10 years : 89.6% ; 25 years : 68.4%). Since the reason for both revision components were aseptic loosening or excessive polyethylene wear the survival rate at 15 years of follow-up was 85.8% (10 years : 92.6% ; 25 years : 76,2%). The survival rate of Corail® femoral stem was 96.8% at 15 years of follow-up (10 years : 98.1% ; 25 years : 95.9%) and the survival of the Tropic® threaded cup was

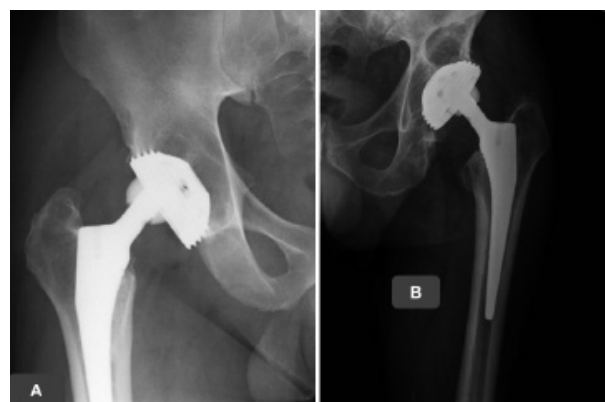


Figure 4. — (A) Eccentricity of the femoral head caused by polyethylene wear and pelvic osteolysis (B) Several pelvic osteolysis.

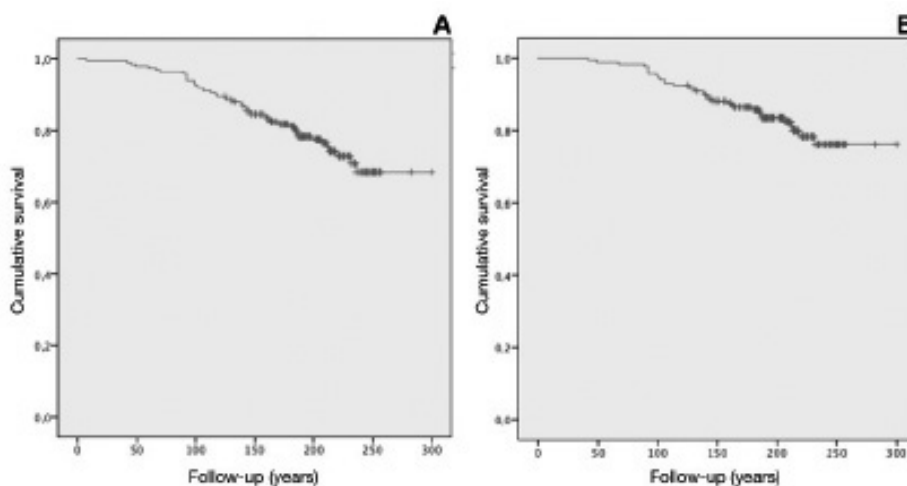


Figure 5. — (A) Survival rate of implants using revision surgery for any reason as the end point. (B) Survival rate of implants for aseptic loosening or excessive polyethylene wear as the end point.

86.3% at 15 years follow-up (10 years : 92.5% ; 25 years : 76.6%) (Figure 5).

DISCUSSION

Few clinical and radiographic studies have been published describing long-term follow-up of an uncemented total hip replacement system. In the late 1970s various designs in threaded uncemented cups were introduced mainly in continental Europe.

The first-generation of threaded acetabular components were manufactured with a polished surface. These designs lead to rigid primary fixation, but long-term secondary fixation is less liable to occur as surface treatment of this first-generation threaded cups was commonly smooth. Capello et al (10) and Simank et al (11) reported a failure of 10-15% at 5 years after surgery for the Mecring and de Bichat III cups, respectively. Clarius et al reported a failure rate of 41% of the acetabular components at 17 years follow-up (12).

Second-generation threaded cup has rough surfaces and have been showed much better results. Zweymüller conically shaped cup had a survival rate at 10 years of 92.6% and 99% at 5 years (13). Fink et al (14) reports a cumulative survival rate of the Former Link V-type acetabular cup of 94,5% after 5 years, 88,1% after 10 years and 70,2% after 15 years concluding that the length of follow-up

and primary cup positioning showed a significant correlation to cup migration. Zhang et al (15) reported an acetabular survival rate of 99.03% with revision as the end point for any reason after a minimum of 12.4 years or 207 consecutive total hips with cementless Zweymüller-Plus system with ceramic-on-polyethylene bearing but with a high number of patients lost of follow-up or died who were not included in the clinical analysis.

Increased wear and polyethylene particles were associated with an increased rate of osteolysis and loosening of the cups. In presence of a relatively high polyethylene wear rate (0.24mm/year), Datir et al (16) describe an excellent survival of threaded HAC coated acetabular sockets at 10 years with radiological evidence of aseptic loosening as an end point with survival rates of 99,15% (CI : 98,3-99,9%) in 144 uncemented total hip arthroplasties in 118 patients. Cruz-Pardos et al (17) reported an analysis of cementless Zweymüller alloclassic system after a minimum follow-up of 25 years. Previously, in 104 hips (18), the cumulative probability of not having loosening of the cup at 12 years was 94.2% 95% CI 91.9% to 96.5%) and in the present study, in 50 hips, the probability of survival of the cup at 20 years was 86.1% (95% CI 75.52% to 96.68%).

New thread design may avoid soft tissue complications and allow bone-preserving intraoperative unscrewing and cup repositioning that should

facilitate the insertion resulting in a more reproducible component position and high contact area between the bone stock and implant. Ellenrieder et al (19) reported, compared to an established press-fit cups in two groups of 42 patients, equivalent clinical outcomes and osseous integration at 5 years of follow-up but more precise implant positioning compared to the press-fit design.

The results of threaded screw cups have in general been disappointing (20-22). The initial stability depends on the bond between the bone and the threads but the secondary fixation with osseous integration is unlikely to occur. Despite their biomechanical advantages, threaded cups continue to raise concern because of their variable clinical results (23,24). In current study, we reported in 202 total hip arthroplasties with threaded cup system a revision rate of 23% and a survival rate for aseptic loosening or excessive polyethylene wear as end point at 15 years of follow-up was 85.8% (10 years : 92.6% ; 25 years : 76,2%).

Therefore, based on the literature and the results of the current study, we decided to abandon the concept of a threaded cup design in favor of a press-fit acetabular cup.

The Corail® stem has been in commercial use since 1986. The stem has been modified twice since it was first introduced. Loboutin et al (25) in 140 Corail TM standard stems implanted has a satisfactory reliability with 98% survival free of revision for aseptic loosening and 95% survival free of stem revision or stem removal at 12 years. These values are slightly different from the ones reported in published studies with the first and second-generation stems where Vidalain et al (26) found a 99% survivorship at 5 years, 98% at 10 years and 96% at 23 years of follow-up in 2956 first-generation stems. Later on, Merini et al (27) found no aseptic loosening after 10 years with the second-generation stem with an overall survival rate of 90.5% due to a high implant fracture rate (laser etching on the neck).

The concept of an extensive HA coating for the fixation of a tapered femoral stem (Corail®) was introduced, in order to achieve durable biological fixation and preserve normal periprosthetic bone activity. To prevent so-called stress shielding

resulting in proximal bone resorption, most cementless stems are coated only proximally. The combination of a tapered titanium stem with an extensive coating may increase fixation with harmonious stress distribution (28,29).

Many studies confirmed the long-term stability of HA-coated prostheses. Herrera et al (28) reported a survival rate at 10 years follow-up of 97.1% in ABG I while a mean of 11.3 years follow-up was 98.30% in ABG II and Sariali et al (29) in 2012, reported that the survivorship of anatomic cementless stem SPS was 100%.

Our data is comparable to the current body of literature with a survival rate, in 202 Corail® HA-coated femoral stems of 96.8% at 15 years of follow-up (10 years : 98.1% ; 25 years : 95.9%). The clinical and radiographic results in this series provided good evidence for long-term efficacy of Corail stem with full extensive HA coating, which prevented most adverse events and offer a satisfactory solution to fixation. However, polyethylene wear maybe a concern, especially in young patients.

The concept of an extensive HA coating for the fixation of a tapered femoral stem (Corail®) and a calcium HA-coated threaded cups (Tropic®) was a system widely used in our department in 1990s.

Few clinical and radiographic studies have been published describing long-term follow-up of these type of implants and in our study, comparable to the current body of the literature, we reported a high rates of aseptic loosening and excessive polyethylene wear with a survival rates of 85.8% at 15 years and 76.2% at 25 years follow-up so we decided to abandon the concept of a threaded cup design in favor of a press-fit acetabular cup.

REFERENCES

1. **Chambers B, St Clair SF, Froimson MI.** Hydroxyapatite-coated tapered cementless femoral components in total hip arthroplasty. *J. Arthroplasty* 2007 ; 22(4 Suppl 1) : 71-74.
2. **D'Antonio JA, Capello WN, Manley MT, et al.** Hydroxyapatite coated implants. Total hip arthroplasty in the young patient and patients with avascular necrosis. *Clin Orthop Relat Res* 1997 ; (344) : 124-138.
3. **Gruen TA, McNeice GM, Amstutz HC.** "Modes of failure" of cemented stem-type femoral components : a radiographic analysis of loosening. *Clin Orthop Relat Res* 1979 ; 141 : 17-27.

4. **Goetz DD, Smith EJ, Harris WH.** The prevalence of femoral osteolysis associated with components inserted with or without cement in total hip replacements. A retrospective matched-pair series. *J Bone Joint Surg Am* 1994 ; 76 : 1121-1129.
5. **DeLee JG, Charnley J.** Radiological demarcation of cemented sockets in total hip replacement. *Clin Orthop Relat Res* 1976 ; 121 : 20-32.
6. **Massin P, Schmidt L, Engh CA.** Evaluation of cementless acetabular component migration. An experimental study. *J Arthroplasty* 1989 ; 4 : 245-251.
7. **Brooker AF, Bowerman JW, Robinson RA, et al.** Ectopic ossification following total hip replacement. Incidence and a method of classification. *J Bone Joint Surg Am* 1973 ; 55 : 1629-1632.
8. **McAuley JP, Moore KD, Culpepper WJ, et al.** Total hip arthroplasty with porous-coated prostheses fixed without cement in patients who are sixty-five years of age or older. *J Bone Joint Surg Am* 1998 ; 80 : 1648-1655.
9. **Kaplan EL, Meier P.** Nonparametric estimation from incomplete observations. *J Am Stat Assoc* 1958 ; 53 : 457-458.
10. **Capello WN, Colyer RA, Kernek CB, et al.** Failure of the Mecron screw-in ring. *J Bone Joint Surg Br* 1993 ; 75(5) : 835-836.
11. **Simank HG, Brocai DR, Reiser D, et al.** Middle-term results of threaded acetabular cups. High failure rates five years after surgery. *J Bone Joint Surg Br* 1997 ; 79(3) : 366-370.
12. **Clarius M, Jung AW, Streit MR, et al.** Long-term results of the threaded Mecron cup in primary total hip arthroplasty: A 15-20-year follow-up study. *Int Orthop* 2010 ; 34(8) : 1093-1098.
13. **Delaunay CP, Kapandji AI.** Survivorship of rough-surfaced threaded acetabular cups. 382 consecutive primary Zweymüller cups followed for 0.2-12 years. *Acta Orthop Scand* 1998 ; 69(4) : 379-383.
14. **Fink B, Protzen M, Hansen-Algenstaedt N, et al.** High migration rate of two types of threaded acetabular cups. *Arch Orthop Trauma Surg* 2004 ; 124(1) : 17-25.
15. **Li H, Zhang S, Wang XM, Lin JH, et al.** Medium-term results of ceramic-on-polyethylene Zweymüller-Plus total hip arthroplasty. *Hong Kong Med J* 2017 ; 23(4) : 333-339.
16. **Datir SP, Angus PD.** Long term survival of an hydroxyapatite-coated threaded cup in the presence of a high polythene wear rate. *Hip Int* 2010 ; 20(3) : 327-334.
17. **Cruz-Pardos A, García-Rey E, García-Cimbrelo E.** Total Hip Arthroplasty with Use of the Cementless Zweymüller Alloclassic System: A Concise Follow-up, at a Minimum of 25 Years, of a Previous Report. *J Bone Joint Surg Am* 2017 ; 99(22) : 1927-1931.
18. **García-Cimbrelo E, Cruz-Pardos A, Madero R, et al.** Total hip arthroplasty with use of the cementless Zweymüller Alloclassic system. A ten to thirteen-year follow-up study. *J Bone Joint Surg Am* 2003 ; 85(2) : 296-303.
19. **Ellenrieder M, Bader R, Bergschmidt P, et al.** Press-fit versus threaded acetabular cups in total hip arthroplasty: Functional and radiological results after five years. *Acta Orthop Belg* 2016 ; 82(1) : 60-67..
20. **Aldinger PR, Thomsen M, Lukoschek M, et al.** Long-term fate of uncemented, threaded acetabular components with smooth surface treatment: minimum 10-year follow-up of two different designs. *Arch Orthop Trauma Surg* 2004 ; 124(7) : 469-475.
21. **Grübl A, Chiari C, Gruber M, et al.** Cementless total hip arthroplasty with a tapered, rectangular titanium stem and a threaded cup: a minimum ten-year follow-up. *J Bone Joint Surg Am* 2002 ; 84(3) : 425-431.
22. **Kubo T, Inoue S, Maeda T, et al.** Cementless Lord total hip arthroplasty: cup loosening common after minimum 10-year follow-up of 103 hips. *Acta Orthop Scand* 2001 ; 72(6) : 585-590.
23. **D'Antonio JA, Capello WN, Ramakrishnan R.** Second-generation annealed highly cross-linked polyethylene exhibits low wear. *Clin Orthop Relat Res* 2012 ; 470(6) : 1696-1704.
24. **Reigstad O, Siewers P, Røkkum M, et al.** Excellent long-term survival of an uncemented press-fit stem and screw cup in young patients: follow-up of 75 hips for 15-18 years. *Acta Orthop* 2008 ; 79(2) : 194-202.
25. **Louboutin L, Viste A, Desmarchelier R, et al.** Long-term survivorship of the Corail™ standard stem. *Orthop Traumatol Surg Res* 2017 ; 103(7) : 987-992.
26. **Vidalain JP.** HA coating. Ten-year experience with the CORAIL system in primary THA. The Arthro Group. *Acta Orthop Belg* 1997 ; 63(Suppl 1) : 93-95.
27. **Merini A, Viste A, Desmarchelier R, et al.** Cementless Corail™ femoral stems with laser neck etching: Long-term survival, rupture rate and risk factors in 295 stems. *Orthop Traumatol Surg Res* 2016 ; 102(1) : 71-76.
28. **Herrera A, Mateo J, Gil-Albarova J, et al.** Cementless hydroxyapatite coated hip prostheses. *Biomed Res Int* 2015 ; 2015 : 386461.
29. **Sariali E, Mouttet A, Mordasini P, et al.** High 10-year survival rate with an anatomic cementless stem (SPS). *Clin Orthop Relat Res* 2012 ; 470(7) : 1941-1919.