

AN UNUSUAL LOCALIZATION AND PRESENTATION OF KAPOSI'S SARCOMA

Y. HALLET, J. VAN OVERSCHELDE

A case of Kaposi sarcoma was diagnosed by skin biopsy in a 71-year-old woman with severe destructive arthropathy of the right shoulder, where all other diagnostic techniques were not conclusive.

Keywords : Kaposi's sarcoma ; arthropathy ; shoulder.
Mots-clés : sarcome de Kaposi ; arthropathie ; épaule.

INTRODUCTION

Kaposi's sarcoma is a rare neoplasm of multifocal origin which presents as red-purple to blue-brown macules, plaques, and nodules of the skin and other organs.

The etiology of Kaposi's sarcoma is unknown although there is some indirect evidence that a virus might be causative.

Kaposi's sarcoma can occur in four major clinical forms : classic Kaposi's sarcoma in elderly Jewish or Mediterranean males ; African Kaposi's sarcoma in the black population in equatorial Africa with most patients less than 20 years of age ; Kaposi's sarcoma secondary to an immunologic deficiency state in patients taking immunosuppressive drugs (e.g. renal transplants); and Kaposi's sarcoma occurring as a complication of acquired immunodeficiency syndrome (AIDS). In each clinical form the lesions are identical histologically. The location of the cutaneous lesions as well as the incidence of systemic involvement, however, vary according to the clinical expression (1).

The purpose of this paper is to present a case of classic Kaposi's sarcoma with an unusual localisation and presentation.

CASE REPORT

In December 1993, a 71-year-old Belgian woman of Caucasian race presented at the orthopaedic clinic because of increasing loss of motion of the right shoulder, swelling and red-bluish colour change of the skin of the trunk and upper limb. There was no report of pain, trauma or other specific disease previously. Physical examination revealed multiple skin lesions extending from the right upper arm to the shoulder, the axilla and the right part of the chest. These skin lesions presented as purple-brown macules with hemorrhagic spotting and a violaceous border. Mobilisation of the shoulder was painless, although a marked limitation of internal and external rotation was present.

Neurological examination showed decreased reflexes in the right arm suggesting a lesion of the brachial plexus, which was confirmed by E.M.G.

X rays of the right shoulder showed severe destruction of the shoulder joint with enlargement of the glenohumeral space and partial destruction of the caput humeri (fig. 1). At this stage the following differential diagnoses were considered : Charcot joint on query trauma, neurotrophic disease, destructive arthritis on infectious or autoimmune basis.

Total body scintigraphy clearly showed a clear and isolated hot spot on the right shoulder (fig. 2).

Further investigations with C.T.-scan, ultrasound and M.R.I. confirmed the major destruction of the shoulder joint, but did not allow to specify the diagnosis (figs. 3 and 4).

Aalsters Stedelijk Ziekenhuis, 9300 Aalst, Belgium.
Correspondence and reprints : J. Van Overschelde.

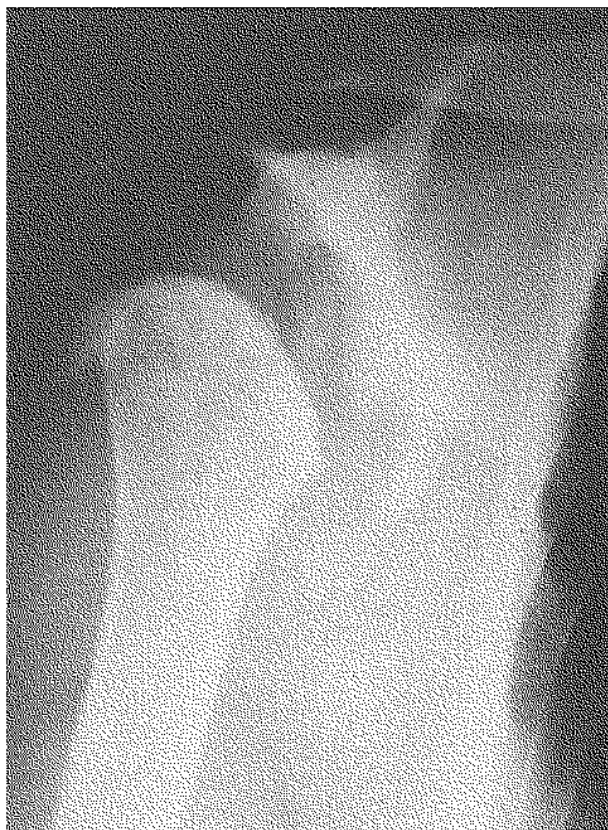

Fig. 1. — Plain x ray of the right shoulder revealing a destructive arthropathy of the glenohumeral joint.

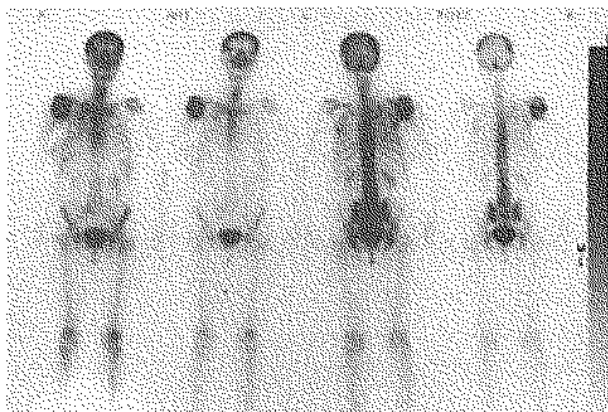


Fig. 2. — Total body scintigraphy demonstrating the isolated involvement of the right shoulder.

All laboratory findings including analysis of the shoulder joint fluid, were normal.

Finally, a skin biopsy was performed and after histological examination the diagnosis of classic Kaposi's sarcoma was established.

The patient was referred to the oncology department for further investigation, staging, therapy and follow-up.

CT scan of thorax and abdomen did not show any evidence of metastases.

Local radiotherapy was given to the right shoulder and hemithorax with a total dose of 48 Gy, followed by chemotherapy (Vinblastine weekly) during one year. There was a good response with regression of skin lesions. The patient remained in good general condition, eventhough CT scan of the right shoulder after two years of treatment showed an increase of the tumoral mass.

DISCUSSION

Classic Kaposi's sarcoma is a rare neoplasm : the incidence of reported cases for the United States is less than 0.1 per 100,000 population and fewer than 0.02 per cent of all malignancies.

The clinical and radiographic presentation of our patient with classic Kaposi's sarcoma is atypical in many ways. Classic Kaposi's sarcoma usually occurs in elderly males of Jewish or Mediteranean ancestry. Men are affected 10 to 15 time more often than women and are usually between 40 to 70 years old (2). The skin lesions commonly affect the lower extremities, and often are associated with classic lymphedema, indicating tumor infiltration of the lymphatics. Systemic involvement is rare : occasionally the gastrointestinal tract is involved and only 10 per cent of patients with classic Kaposi's sarcoma have hepatic lesions. Although bone and joint involvement has been described, these findings are even rarer. Moreover, the radiographic findings seen in our patient, did not correspond to the typical radiographic findings which have been described in classic Kaposi's sarcoma.

Typically, the radiographs in classic Kaposi's sarcoma show alteration of the soft tissues and of the skeleton (1).

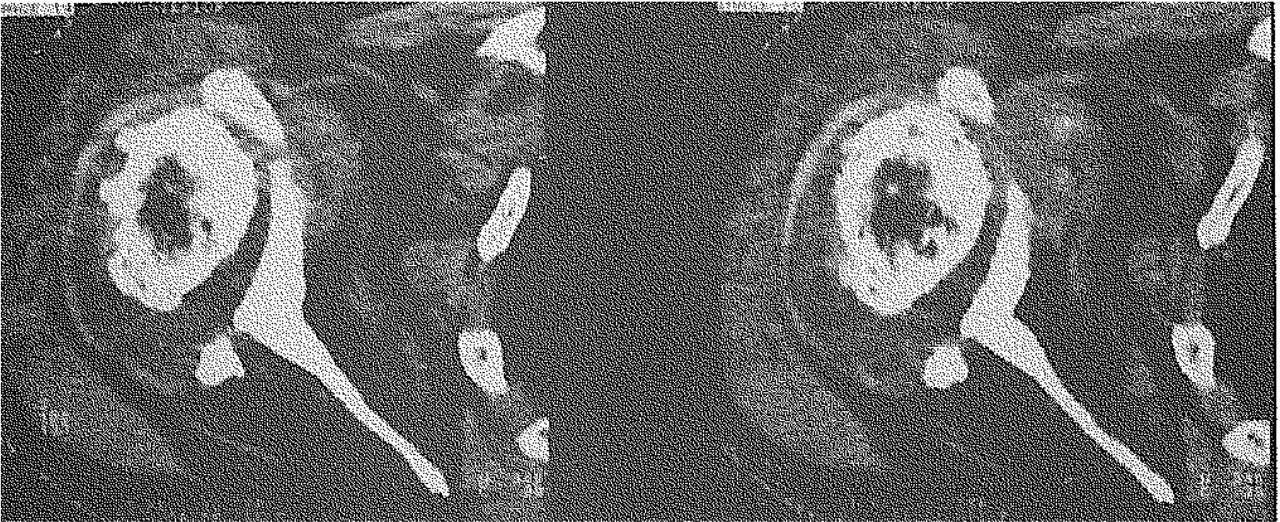


Fig. 3. — CT-scan of the right shoulder confirming the major glenohumeral joint destruction.

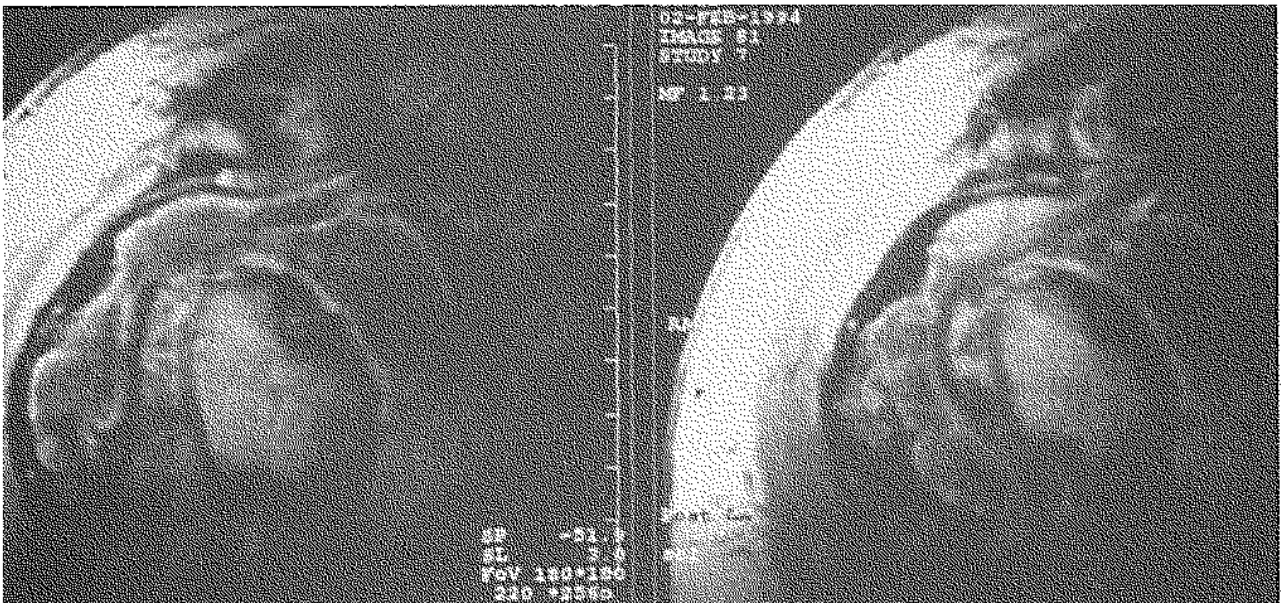


Fig. 4. — M.R.I. of the right shoulder.

At the level of the soft tissue the x rays typically disclose solitary or multiple tumours, which are located subcutaneously or more deeply.

Multiple calcified foci, comparable to those seen in hemangiomas, or even calcifications of arteries may be present.

Skeletal changes may occur anywhere, although the bones most frequently involved are the metatarsals, the phalanges, the tarsal bones, fibula, tibia, radius and ulna.

Skeletal changes include erosions, bone rarefaction and cyst formation. Erosions are the most typical x ray findings of classic Kaposi's sarcoma. These erosions present as small cortical irregularities and look like "bite out" lesions. They may involve the whole cortex and usually a periosteal reaction is seen on both sides of the shaft.

Bone rarefaction is usually generalised. The bone becomes hazy, ghost-like and the trabecular pattern looks rubbed out with expansion of the medullary cavity and thinning of the cortex. Fractures are rare. Cysts can be seen in all long bones, phalanges, ribs and spine. These cysts do not break through the cortex and usually are not associated with any periosteal reaction. Large cysts of up to 48 mm can be found in the distal femur. The differential diagnosis of these x ray findings include leprosy, madura foot, reticulosis, neurofibromatosis and hemangioma.

Biopsy of skin lesions should always be performed as the characteristic histologic features allow to establish the diagnosis of Kaposi's sarcoma (3).

REFERENCES

1. Ackerman L., Murray J. Symposium on Kaposi's Sarcoma, 1963, S. Karger AG, New York.
2. Cerimele D. Kaposi's Sarcoma, 1985, Spectrum Publications, Rome.
3. Gottlieb G., Ackerman A., Kaposi's Sarcoma: A Text and Atlas, 1988, Lea & Febiger, New York.

SAMENVATTING

Y. HALLET, J. VAN OVERSCHELDE. Een ongewone localisatie van een Kaposi's sarcoma.

Bij een 71-jarige, Belgische, blanke vrouw met een destructieve arthropathie van de rechter schouder wordt na een volledige oppuntstelling zonder definitief besluit, de diagnose van Kaposi sarcoma gesteld op histologisch onderzoek van een huidbiopt.

RÉSUMÉ

Y. HALLET, J. VAN OVERSCHELDE. Localisation et présentation rares d'un sarcome de Kaposi.

Chez une femme belge, âgée de 71 ans, de race caucasienne, présentant une arthropathie destructrice de l'épaule droite, le diagnostic de sarcome de Kaposi a été posé par l'examen histologique d'une biopsie de peau après une mise au point complète n'ayant donné aucun diagnostic concluant.