

PITFALLS IN WRIST ARTHROSCOPY

L. DE SMET

Arthroscopy of the wrist is a well-established procedure ; however complications, problems and difficulties are possible.

The complication rate is estimated to be about 2%, of which equipment failure is probably the most frequent. Injury of the overlying tendons, nerves and even the radial artery has also been described.

The anatomy of certain wrists can cause considerable difficulties in obtaining a clear view. The major problem however is the correlation between the clinical and radiographic findings, and the arthroscopic findings.

There are some abnormalities which do not have any significance since most of them can be considered as normal ageing phenomena.

Keywords : arthroscopy ; wrist ; complications.

Mots-clés : arthroscopie ; poignet ; complications.

INTRODUCTION

Arthroscopy has become a well-established procedure in the evaluation of (chronic) wrist pain and in the treatment of a limited number of intra-articular pathologies, i.e. lesions of the triangular fibrocartilaginous complex (TFCC). Its value has been critically evaluated. Numerous authors have reported on the techniques, indications and results (5). With the "popularization" of a technique however, complications have appeared (8).

The particularity of the wrist with respect to arthroscopy is its small size, the complexity of the patient(s) and the proximity of tendons and nerves to the standard portals. Arthroscopy of the wrist is a procedure not highly appreciated by insurance

companies, mostly because the arthroscopy provides the objectivation of a lesion which was not apparent previously. Because the treatment of wrist pathology is not always straightforward, arthroscopy is blamed as the cause of a long-lasting history sometimes ending with (limited) impairment.

Pitfalls can be divided into :

- complications
- difficulties
- problems

Complications

Arthroscopy in general has a low incidence of complications. According to Small *et al.*, (9) based on a very large series, the complication rate was around 0.59%. For the wrist, a 2% complication rate has been cited. Most of these complications are minor without residual morbidity. These numbers are probably an underestimation. Surgeons are usually reluctant to admit their failures and are definitely not enthusiastic for publishing them. On the other side most series are already outdated and further technical possibilities have recently become available. Complicated procedures are of course associated with a higher complication rate.

For the wrist complications can be divided into four categories (3, 10) :

Department of Orthopedic Surgery, University Hospital Pellenberg, Belgium.

Correspondence and reprints : L. De Smet, Department of Orthopedic Surgery, U.Z. Pellenberg, Weligerveld 1, B-3212 Pellenberg, Belgium.

1. related to arm positioning and traction,
2. related to portal creation and instrument introduction,
3. procedure specific,
4. general arthroscopic complications.

Traction and positioning

Finger straps can harm the skin, especially in older, rheumatoid arthritic and/or cortisone-treated patients. Metallic straps can produce more damage than the nylon ones. One can avoid this by applying traction to more than the minimal 2 fingers. Traction can also harm the collateral ligaments of the metacarpophalangeal joints and the intercarpal ligaments. Most authors recommend a traction force less than 5 kg, and as short as possible. Of course careful positioning of the elbow is indicated to avoid compression of the ulnar nerve in the cubital tunnel. The use of a tourniquet as a routine procedure can also give some problems, but these are no different than in other upper limb surgery.

Portals and instrument introduction

Different from most other joints amenable to arthroscopy, the wrist is circumferentially covered by tendons, vessels and nerves. A detailed knowledge of the anatomy is required.

The close proximity of these structures to the standard portals is frightening. Anatomical studies have clearly demonstrated this (1, 2). Variations of so-called normal anatomy can even be more disturbing. The dorsal branch of the ulnar nerve is particularly at risk when the 6 ulnar (6U) portal is used for irrigation or placement of sutures in the TFCC. The posterior interosseous nerve is purely sensory, and branches are found in the dorsal capsule. Del Pinal *et al.* reported in 1999 a complete avulsion of the nerve during arthroscopy (4) as the cause of persisting wrist pain.

Fortems *et al.* reported 2 late ruptures of the extensor pollicis longus tendon after arthroscopy. They compared the mechanism to the one seen in late rupture of this tendon in undisplaced Colles' fractures (6).

With the 1-2 portal, the radial artery is at risk. The surgeon should be very careful before using

this portal, which has limited indications anyway. The radial artery can also be damaged when volar wrist ganglia are resected arthroscopically.

Introduction of the trocar into the joint can cause damage to the cartilage, the scapholunate ligament and the TFCC.

Precise location of the portals is required. Only the skin should be incised. Further development of the portal is done with a hemostat. Blunt trocars should be used. Where resistance is encountered, the surgeon should not forcefully introduce the trocar, but rather reconsider the portal placement and start over again.

Procedure related

Extravasation of irrigation fluid into the soft tissues is a potential danger for producing a compartment syndrome. Particularly at risk are arthroscopically assisted treatments for intra-articular fractures of the distal radius. An infusion pump is another dangerous instrument, and we recommend a gravity-fed inflow. Sutures in a TFCC repair can harm the dorsal branch of the ulnar nerve (fig. 1).

General arthroscopy complications

Infection is not a frequent problem. The rate has been estimated at 0.07% for all joints. In our experience the combination of closure of the portals and instillation of cortisone is a high-risk situation, and

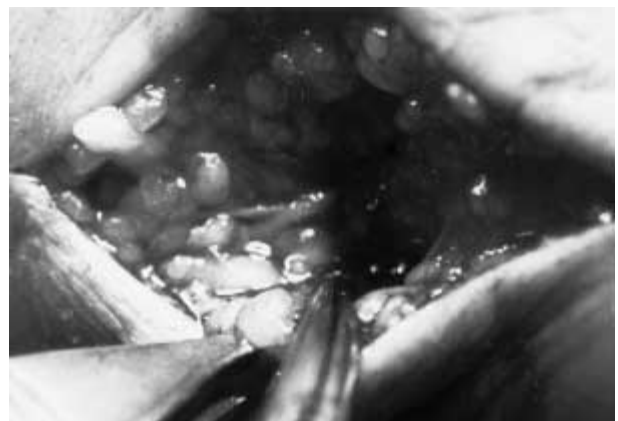


Fig. 1. — Ligation of the dorsal branch of the ulnar nerve by a TFCC suture.



Fig. 2. — Sometimes a scope comes back that way

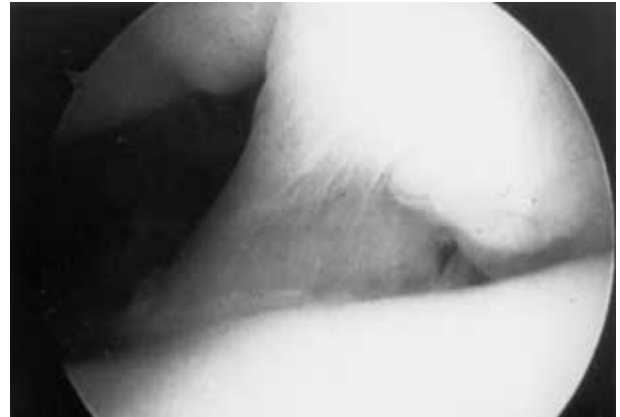

Fig. 3. — Bi-compartmentalization of the wrist

since we had 2 infections after such a procedure, we do not recommend this technique.

Equipment failure is probably the most frequent complication at 0.1%. Most instruments are fragile, and a back-up system is mandatory (fig. 2).

Although rare in arthroscopy, postsurgical reflex sympathetic dystrophy can cause significant harm.

Difficulties

Arthroscopy of the wrist is not always easy and some situations are challenging. Small wrists (“petite” wrists) can be particularly difficult to scope.

Anatomical variations, congenital or acquired deformities can pose particular difficulties for a clear view. We have been confronted several times with an intra-articular prominent ridge, sometimes even like a membrane, dividing the radiocarpal joint into 2 compartments (bicompartiment wrist joint) (fig. 3). It can take considerable time to realize that this anatomical variation blocks the view. It is obvious that synovitis, arthrofibrosis and intra-articular fractures interfere with the arthroscopists. The repetition of an arthroscopy or an arthroscopy after a surgical procedure is often not possible.

Problems

Contrary to other joints the natural history of ageing processes and some intra-articular altera-

tions are not common knowledge. The value of arthroscopic findings is not clearly defined.

What if you do not see what you wanted to see? Mostly this is because of a faulty technique. An additional portal, a smaller scope, or some synovial shaving can solve the problem.

One also has to question whether additional effort is worthwhile for further management of the wrist problem and if more scoping trials do not cause more harm than benefit for the patient.

Sometimes nothing particular has been seen. Despite the fact that the patient seemed reliable, not all wrist pain can be explained by an anatomical alteration, and arthroscopy reveals only “intra-articular” anatomy. Extra-articular pathology or biomechanical disturbances are much more difficult to evaluate. The finding of a ligament tear, a perforation of the TFCC or cartilaginous damage must be correlated with age and profession. We could demonstrate that in an aged population the TFCC was torn in 50% of wrists, a ligament tear was present in 30% and cartilaginous degeneration in 60% (6). The complaints of the patient, the physical examination, the medical imaging and the arthroscopic findings must all correlate to be meaningful.

A central perforation of the TFCC in a 55-year-old patient with radial wrist pain, normal and pain-free prosupination and normal grip force probably has nothing to do with the patient’s complaints. This is also why insurance companies are reluctant

to endorse wrist arthroscopy. When an abnormality is discovered, the patient feels that he has to be compensated for the "harm" even when the findings are not related to the claimed accident or even are anatomical variants or simply ageing alterations (6).

In Belgium some financial problems for the surgeon are also present. The normal fee for a diagnostic procedure is too low, and wrist surgeons are tempted to add a (pseudo)therapeutic act. Despite being unethical, this attitude also disturbs the medical file of the patients.

It should be clear before scheduling a wrist arthroscopy that the surgeon not only has to be confident with the patient's complaints, the physical examination and the medical imaging, but must have a clear strategy for the future. The arthroscopy should be beneficial, which means that the findings during this endoscopic examination can change further treatment options. If not, diagnostic arthroscopy is useless.

If an arthroscopic treatment is the option, the surgeon should be prepared to perform the procedure or when confronted with unexpected findings to omit the procedure and perform an alternative treatment.

CONCLUSION

Arthroscopy of the wrist is a powerful tool in the exploration of this complex joint. As with all other procedures, advantages have to be weighed against possible complications (8). The wrist must be evaluated to see if particular difficulties can be expected. Proper indications, knowledge of limitations and organized follow-up are required. A proper technique, with care for the portals and intra-articular movements, dynamic tests and probing can avoid overhasty conclusions. The aim is to perform a full exploration with a check-list, drawings and photographs.

Arthroscopy is a technique and must be correlated with the other examinations of the wrist, but it is still a technique, not a religion. Specific indications are summarized in table I. The surgeon must have insight, knowledge and philosophy in managing wrist problems.

Table I. — Indications for wrist arthroscopy

<p>Diagnosis and staging</p> <ul style="list-style-type: none"> ● Chronic (ulnar) wrist pain (> 6 months) with normal imaging. ● Locking of the wrist. ● Chronic (> 3 months) scapholunate dissociation in order to evaluate cartilage damage and the possibility to perform a direct suture. ● Kienböck's disease (staging of the cartilaginous status). ● Persisting pain after distal radius fracture. ● Discordance between clinical findings and imaging. ● Monosynovitis (> 6 months) without diagnosis.
<p>Therapy</p> <ul style="list-style-type: none"> ● TFCC suture. ● TFCC debridement ± ulnar head wafer resection. ● Reduction of intra-articular fracture of the radius. ● Synovial biopsy. ● Resection of ganglia. ● Visual control of K-wire placement. ● Loose body removal. ● Radial styloidectomy. ● Scaphoid fixation with cannulated screw.

REFERENCES

1. Abrams R., Petersen M., Botte M. Arthroscopic portals of the wrist : An anatomical study. *J. Hand Surg.*, 1994, 19-A, 940-944.
2. Buterbauch G. Radiocarpal arthroscopy portals and normal anatomy. *Hand Clin.*, 1994, 10, 567-576.
3. Culp R. Complications of wrist arthroscopy. *Hand Clin.*, 1999, 15, 529-535.
4. Del Pinal F., Herrero F., Cruz-Camara A., San Jose J. Complete avulsion of the distal posterior interosseous nerve during wrist arthroscopy : A possible cause of persistent pain after arthroscopy. *J. Hand Surg.*, 1999, 24-A, 240-242.
5. De Smet L., Dauwe D., Fortems Y., De Ferme J. The value of wrist arthroscopy. *J. Hand Surg.*, 1996, 21, 210-212.
6. Fortems Y., De Smet L., Fabry G. Cartilaginous and ligamentous degeneration of the wrist : Anatomic study. *Ann. Chir. Main*, 1994, 13, 383-385.
7. Fortems Y., Mawhinney I., Lawrence T., Trial I. A., Stanley J. K. Late rupture of extensor pollicis longus after wrist arthroscopy. *Arthroscopy*, 1995, 11, 322-323.
8. Ritt M. Arthroscopy : A giant leap forward in wrist surgery. *J. Hand Surg.*, 2001, 26-B, 238-240.
9. Small N. Complications in arthroscopy : The knee and other joints. *Arthroscopy*, 1986, 2, 253-258.
10. Warhold L., Ruth R. Complications of wrist arthroscopy and how to prevent them. *Hand Clin.*, 1995, 11, 81-89.

SAMENVATTING

L. DE SMET. Complicaties van polsarthroscopie.

Arthroscopie van de pols is een wel omschreven procedure, doch complicaties, problemen en moeilijkheden bestaan. Men schat de complicatie ratio op 2% waarvan materiaal-falen waarschijnlijk de meest frequente is. Ook letsels aan de pezen, zenuwen en zelfs de arteria radialis zijn mogelijk.

De anatomie van bepaalde polsen kan voor ernstige moeilijkheden zorgen.

Het grootste probleem echter is de correlatie tussen kliniek en beeldvorming met de arthroscopische bevindingen. Sommige anomalieën zijn zonder belang daar zij als een normaal verouderingsproces kunnen worden beschouwd.

RÉSUMÉ

L. DE SMET. Complications de l'arthroscopie du poignet.

L'arthroscopie du poignet est une technique bien établie, qui expose cependant à un risque de complication et qui peut poser des problèmes et présenter des difficultés. Le taux de complication est de l'ordre de 2% ; parmi les complications, les plus fréquentes sont en rapport avec une défaillance du matériel utilisé. On a également décrit des lésions des tendons sus-jacents, des nerfs et même de l'artère radiale.

Il peut s'avérer difficile dans certains cas d'avoir une vision correcte de l'articulation.

Le problème majeur reste celui de la corrélation entre les constatations cliniques et radiologiques et les constatations arthroscopiques. Certaines anomalies observées sont dépourvues de signification, et peuvent être considérées comme des stigmates du vieillissement.