

# EARLY SURGICAL CORRECTION OF RESIDUAL HIP DYSPLASIA : THE SAN DIEGO CHILDREN'S HOSPITAL APPROACH

D. R. WENGER<sup>1</sup>, S. L. FRICK<sup>2</sup>

Studies of the etiology of premature osteoarthritis of the hip show that the most common cause is residual childhood hip dysplasia. Hip dysplasia is often asymptomatic in childhood, making detection difficult and creating complex treatment decisions (major surgery in the asymptomatic child). Symptoms do not develop typically until the teenage or early adult years, and surgical correction at this age is often incomplete and complicated. In contrast, if the dysplasia is recognized early, surgical correction can be performed using simpler osteotomies with more predictable results. Our experience with children, adolescents and adults with residual hip dysplasia has led us to adopt a philosophy of early surgical correction which seeks to normalize hip joint morphology by age 5 or 6 years. The reasoning, methods and early results of this approach are reviewed in this paper.

**Keywords :** hip ; dysplasia ; surgical treatment ; child.  
**Mots-clés :** hanche ; dysplasie ; traitement chirurgical ; enfant.

---

## INTRODUCTION

Residual hip dysplasia in childhood is a very common cause of the premature onset of osteoarthritis of the hip. Cooperman, Harris and others have clarified that most adults with premature hip osteoarthritis have had prior childhood hip disease (5, 11). Although this may be due to Perthes disease or slipped capital femoral epiphysis, the

most common cause appears to be residual hip dysplasia (1).

A surgeon who treats hip disease in childhood and adolescence is faced with two major problems. The first is to detect hip dysplasia early so that it can be treated. Widespread screening programs and careful examinations by pediatricians and family practitioners have decreased the incidence of late onset hip dislocation and dysplasia. Even early recognition and treatment does not assure normal hip development, as Tucci *et al.*, have noted a high incidence of persistent acetabular dysplasia (17%) in adolescents treated in infancy with a Pavlik harness for DDH (30). Frequently children have few or no findings in infancy, particularly if the hip is only dysplastic (not dislocated), and the diagnosis of hip dysplasia is not made until the teenage years when the child begins to have symptoms.

The second major task of a surgeon treating hip disease is to decide what degree of residual dysplasia requires surgical intervention. Despite

---

<sup>1</sup> Department of Orthopedics, Children's Hospital San Diego, University of California — San Diego, San Diego, California, USA.

<sup>2</sup> Dept. of Orthopedic Surgery, Carolinas Medical Center, Charlotte, N.C., USA.

Correspondence and reprints : D. R. Wenger, Dept of Orthopedic Surgery, Children's Hospital — San Diego, 3030 Children's Way, Suite 410, San Diego, California, USA 92123.

the availability (3) of newer technologies (CT scans, 3-D CT scans), it is still not entirely clear which hips with residual dysplasia will benefit from surgical correction. In general it is felt that children under age three years with known residual dysplasia should be treated with observation or perhaps an abduction brace. The indications we use for surgical correction include a persistent subluxation of the hip at any age, or persistent dysplasia of the hip after four to five years of age. Subluxation is defined as being a consistent break in Shenton's line on the AP view of the pelvis in a child after one and a half to two years of age. Such hips have a persistently poor prognosis and cannot be expected to improve spontaneously (31-33). Hips with persistent dysplasia only (no subluxation — Shenton's line intact) have some potential for natural improvement of the acetabular index at least up until age five years (16, 34). If they are not corrected by that time, it is generally agreed that a corrective acetabuloplasty should be performed.

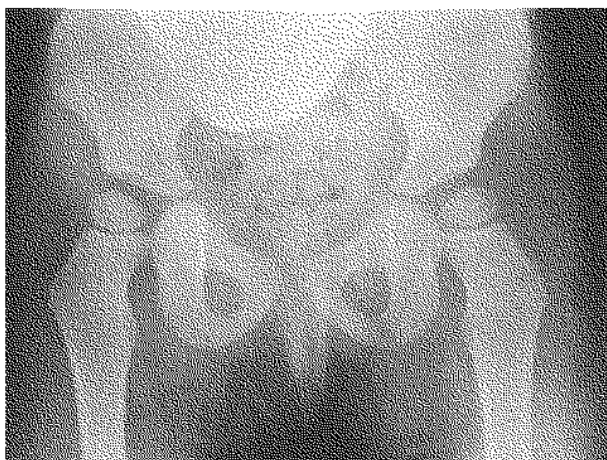
Thus residual childhood hip dysplasia remains a difficult orthopedic problem and decisions regarding how and when to intervene surgically remain somewhat complex. The purpose of this paper is to present the San Diego Children's Hospital approach to diagnosis and surgical intervention in residual hip dysplasia in children under age eighteen years. A special focus will be given to our attempt to normalize the femoral head/acetabular relationship by age five to six years.

### **PHILOSOPHY OF EARLY INTERVENTION**

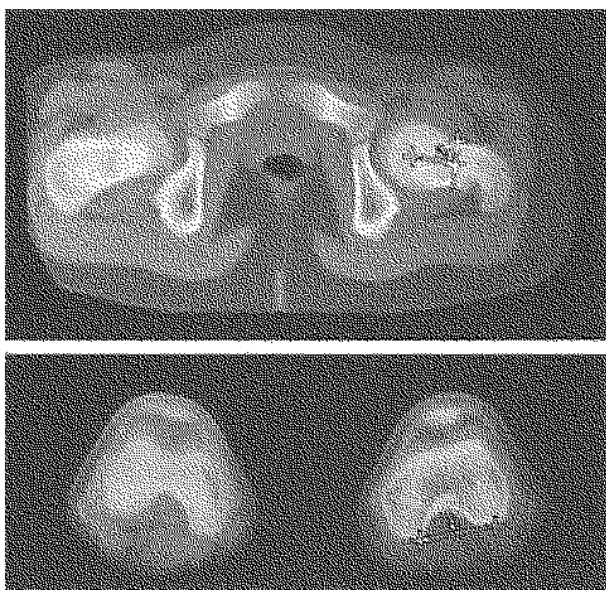
After many years of experience in treating hip dysplasia, it has become clear in our center that the methods used to surgically correct acetabular dysplasia in teenagers are fraught with complications. A proximal femoral varus osteotomy performed in a teenager does not have the opportunity to re-grow and correct excess varus and thus the patient may end up with a permanent limp.

Similarly the major rotational acetabuloplasties that are required in the teenage years (triple innominate osteotomy, double innominate osteotomy, others) are major surgical interventions that have a high risk for pseudarthrosis and/or excessive external rotation. Thus in a sense surgery in the teenage years to correct hip dysplasia can be considered salvage surgery and realistic analysis of results would suggest that only 60 to 70% have excellent results. By contrast we have found that children treated under age five to six years have a near certain excellent outcome. If a femoral osteotomy is required, the child may limp for a short period but almost always recovers from the temporary abductor weakness by one to two years following surgery. Similarly, acetabuloplasties used in these younger children (Salter, Pemberton, Dega) are predictable and heal rapidly without a risk for pseudarthrosis. Several of them are stable without internal pin fixation (Pemberton, Dega) and thus require no later procedures for metal removal. Basic science studies have shown that the key factor in normal hip development is the presence of a spherical femoral head that is well seated and centered in the acetabulum (20) and acetabuloplasties in young children with hip dysplasia can achieve this goal and allow normalization of hip development.

We have thus moved toward the philosophy that residual hip dysplasia should be corrected by age five to six years. Perhaps our most difficult remaining decision is to determine when we should intervene and what degree of hip dysplasia requires treatment (9). To make these decisions we perform careful analysis of plain films, two dimensional computed tomography (2D CT) studies, and three dimensional computed tomography (3D CT) films (14). On the plain film anteroposterior (AP) pelvis radiograph we analyze for subluxation (fig. 1), the acetabular index, and the center edge angle. We also carefully analyze the shape and contour of the sourcil. The 2D CT studies are used to analyze the degree of femoral anteversion (19), which can be readily studied since transverse images at the hip, knee and ankle are taken to allow full assessment of rotation (fig. 2).



**Fig. 1.** — This AP pelvis radiograph in a 4-year-old female shows acetabular dysplasia and associated hip subluxation as indicated by a break in Shenton's line.



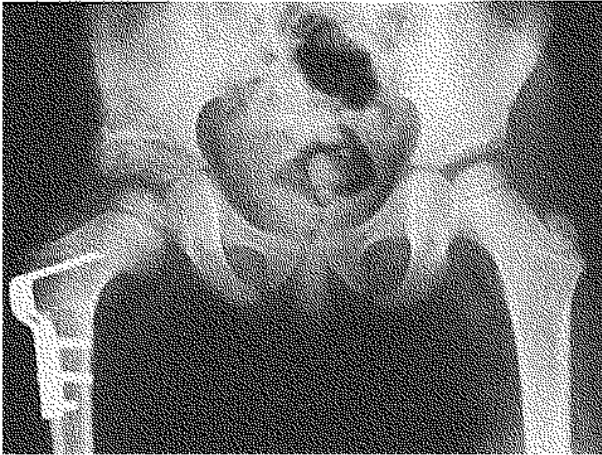
**Fig. 2.** — The rotational profile is evaluated with 2D CT cuts taken through the proximal femur and femoral neck as well as the distal femur to measure femoral anteversion.

The 3D CT studies are a series of carefully performed studies with clear views of the femoral head and acetabulum from all angles (fig. 3 A,B). We currently use the GE Medical Systems (Milwaukee, WI, USA) HiSpeed CT/i computed tomography system. For 3D exams the scans are

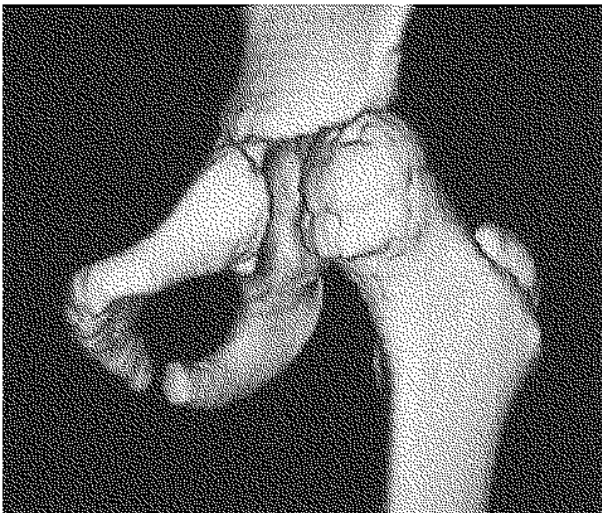
done with 3 mm helical scans at a 1:1 pitch and are retrospectively reconstructed to 1 mm slices by the scanner for 3D reconstructions. The scans are rapidly performed with this scanner and methodology, with a typical 3D pelvis exam requiring only one minute of scan time. The data from the CT scanner is then processed into high resolution three dimensional images using sophisticated 3-D CT hardware and software (VIP Version 2.2 software, Cemax-Icon, Inc., Fremont, CA, USA). To apply this technology, one needs the skills of a committed computerized tomography technician who has the time and energy to produce quality images. Our images include full pelvis views from all angles (turned or tilted 15 degrees sequentially for each image) as well as focused views of the individual hip with the femoral head present and with the femoral head subtracted. We also produce views of the femoral head as well as inferior views of the acetabulum. Because we are interested in building both a clinical and research database, both the normal and abnormal hip are studied in all cases (total 114 images per case). Once the data has been gathered by the scanner, 30 minutes to 2 hours are required by the 3D CT workstation and software to produce the multiple images required for a comprehensive analysis of the hip.

The most valuable 3D CT view is the straight lateral view of the acetabulum with the femoral head subtracted (14). We also use the inferior view of the acetabulum with the femoral head subtracted to perform a topographic map of the acetabular roof. Lateralization of the center of rotation is a likely predictor for premature arthritis. Unfortunately this view is not as valuable in children under age six to eight years because a significant portion of the lateral segment of the acetabulum is still cartilaginous and hence not visible on the CT.

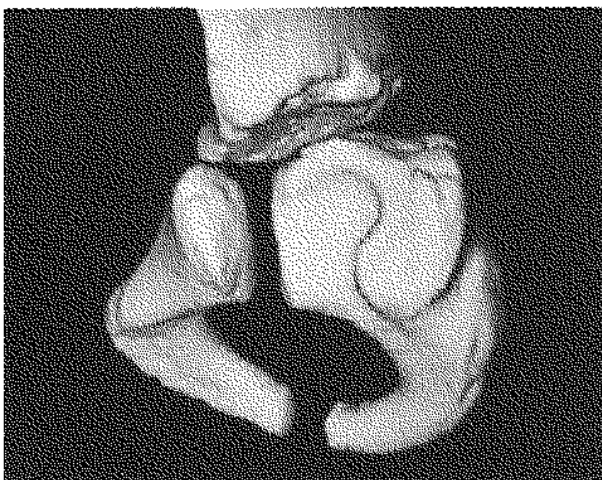
All of the above material is used in deciding whether to intervene in a child. Absolute indications for intervention are a significant break in Shenton's line on the standing AP pelvis view and a significant residual abnormal center edge angle (less than 20°) and a significant abnormal acetabular index (greater than 25° after age three



a



b



c

years). A strong indicator for treatment in analysis of the 3D CT films includes our ability to visualize the inner surface of the acetabulum from the straight lateral view with the femoral head subtracted, signifying marked deficiency of the lateral acetabulum. In addition, a continuing upward slope on the acetabulum noted on the lateral 3D CT view (type 2 dysplasia) is an indicator for intervention. Also 3D CT acetabular roof views from inferior that show marked lateralization of the center of rotation are an indication for surgical correction.

With severe abnormalities, the decision can be easy. With borderline abnormalities, the indication for surgical intervention remains difficult. These difficulties in decision making are the basis for our considering this a philosophy of hip management. Simply stated, hip function appears to follow form and a child must have normal hip morphology to expect lifelong excellent function (1, 2, 11, 25, 26). If one waits until the teenage years and until a child has symptoms to intervene, one must perform complex, more difficult procedures that are prone to complications. If one is willing to force a decision by age five to six years, the chance for a near perfect surgical result is greatly increased. The risk or cost of this philosophy is that one occasionally may operate on a child whose hip perhaps would have normalized over time. We believe this risk is justified if one has developed safe and predictable surgical techniques that have an extremely low complication rate.

---

**Fig. 3a-c.**

**3a.** — AP pelvis radiograph in a 3-year 8-month old child suggesting residual left hip dysplasia (the right hip was previously treated for a complete dislocation).

**3b.** — Anterior 3D CT view of the same left hip.

**3c.** — The lateral 3D CT view with the femoral head subtracted allows visualization of the inner surface and roof of the acetabulum, indicating lateral acetabular deficiency.

## **CURRENT TREATMENT METHODS — SAN DIEGO CHILDREN'S HOSPITAL**

### **Children age three to ten years**

Surgery may be performed in a child as young as three years if the degree of residual dysplasia is severe or the child has subluxation (a break in Shenton's line on the AP pelvis radiograph). If the dysplasia is mild, the child may be monitored until age six to eight years to be certain that a corrective surgical procedure is required.

Once serial radiographic studies demonstrate failure of the dysplasia to correct in children less than 8 — 10 years, we perform the Pemberton acetabuloplasty osteotomy. This is an incomplete curvilinear cut of the ilium above the acetabulum that hinges on the posterior wing of the triradiate cartilage (6, 18). This procedure changes the size and shape of the acetabulum and is generally thought to decrease the volume of the acetabulum. Some experts have suggested that the volume itself is not actually reduced, and that a shape changing acetabuloplasty is the best term for the procedure. This osteotomy works best in children under age eight years. As the triradiate cartilage thins, it is more difficult to get a complete rotation. If there is only a modest break in Shenton's line, the procedure is performed alone without concomitant femoral osteotomy. A bone graft taken from the iliac crest just above the osteotomy is shaped in a slightly curved fashion as well and securely stabilizes the acetabuloplasty with internal fixation almost never required. Our goal in performing the procedure is to center the femoral head into a more normally shaped acetabulum to allow normalization of acetabular growth. Thus, great care must be taken in performing the osteotomy to prevent injury to the acetabular growth centers, especially in the very young patient. We have previously documented injury to and subsequent abnormal growth of lateral acetabular growth centers following Albee type acetabuloplasties which were performed very near the acetabulum (35). Postoperatively the child is kept in a hip spica for six weeks to assure incorporation of the

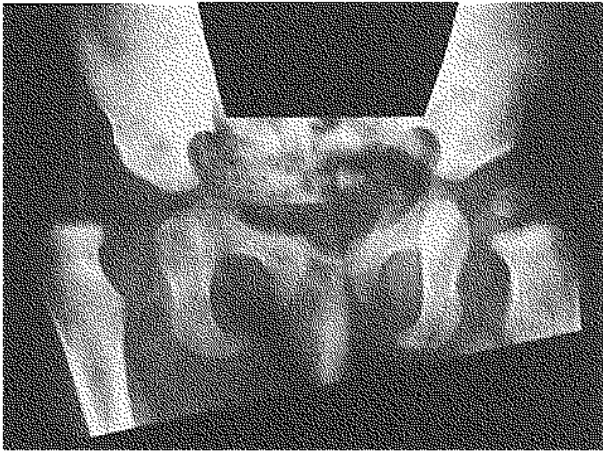
bone graft and is allowed partial weight bearing for an additional four weeks to minimize any chance for complications.

### **Need for femoral osteotomy — age three to ten year age group**

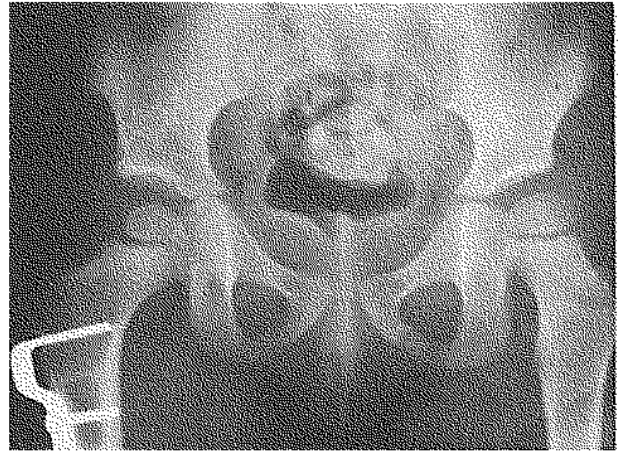
If the child has significant coxa valga and anteversion and/or a marked break in Shenton's line, we also add a proximal femoral varus derotation osteotomy, fixed with an AO infant blade plate. The neck shaft angle is almost never taken below 120° to minimize the chance of a prolonged limp. Care is taken in introducing the blade plate to minimize any damage to the greater trochanteric apophysis. Currently one-third to one-half of children treated in the three to ten year age group also have a concomitant femoral osteotomy to assure complete correction of the dysplasia and to predictably restore Shenton's line. Our philosophy is to always do the acetabular procedure as the primary procedure and to add the femoral osteotomy (same anesthetic) if needed. Our philosophy of slight risk for over-treatment at a young age will cause us to add the femoral osteotomy in a borderline case rather than waiting for a few years to see if it needs to be done later. This approach may risk over-treatment in a few cases but we believe that with a condition as serious as hip dysplasia, this approach is merited. The surgical technique must be faultless if one is to take this approach. If an AO blade plate is used, we advise removal in one year to avoid bony overgrowth and any adverse sequelae that might affect a total hip replacement surgery later in life.

### **Femoral osteotomy alone for hip dysplasia — under age three to ten years**

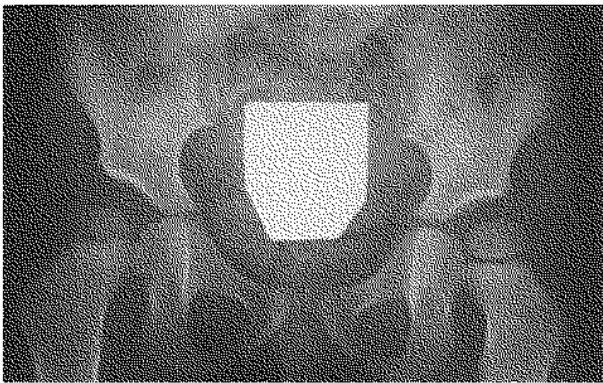
Several reports have suggested the adequacy of femoral osteotomies alone for the treatment of hip dysplasia (10, 13, 22). We have used and studied this approach in a group of younger children and have not found it to be predictably and certainly effective in correcting residual dysplasia. In ad-



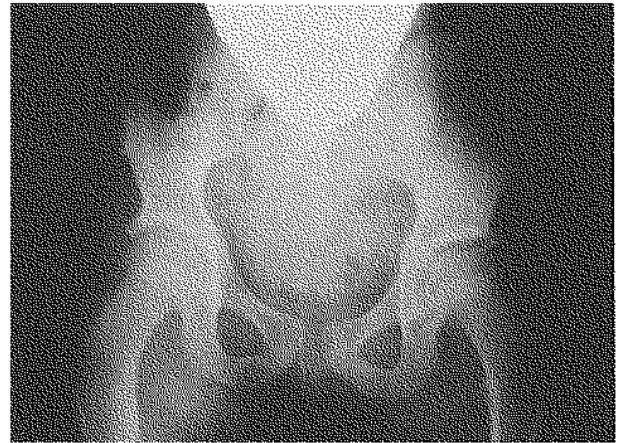
a



c



b



d

**Fig. 4a-d.**

**4a.** — Initial AP pelvis radiograph in a 8-month old with a complete right hip dislocation, treated by open reduction and capsulorrhaphy at age 9 months.

**4b.** — Follow-up radiograph at age 2-years 3-months reveals persistent acetabular dysplasia and subluxation.

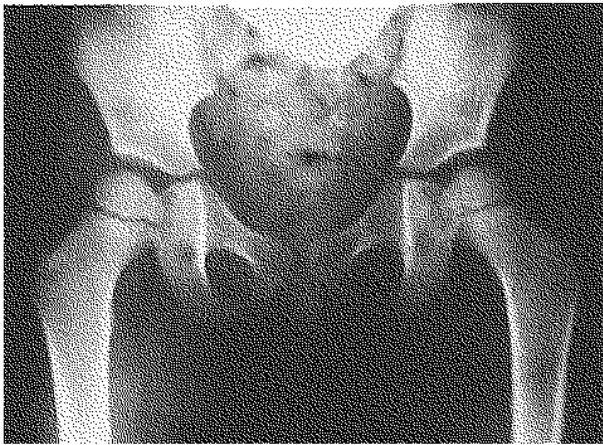
**4c.** — Pelvis radiograph taken one year after the patient underwent Pemberton acetabuloplasty and proximal femoral varus derotational osteotomy.

**4d.** — Film taken 10 years postoperatively demonstrating that the hip morphology has been normalized.

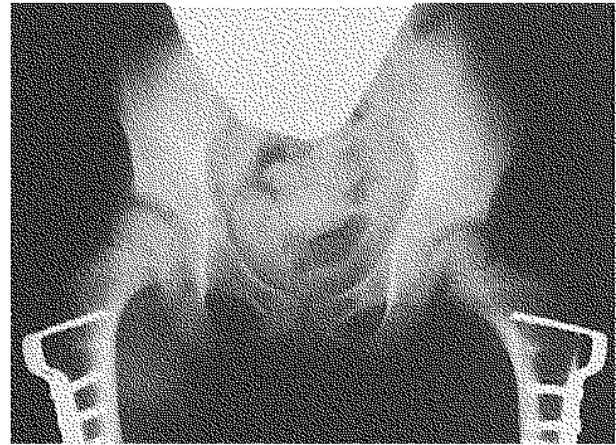
dition, when one does a femoral osteotomy, the issue of metal removal must always be subsequently faced. We find that the Pemberton osteotomy (or other acetabular osteotomy) is the preferred approach to borderline residual hip dysplasia cases since it more predictably reproduces normal anatomy and hip mechanics. Also the Pemberton or Dega osteotomy can be performed without internal fixation thus no subsequent metal removal is required.

#### **Treatment of acetabular dysplasia over age eight to ten years**

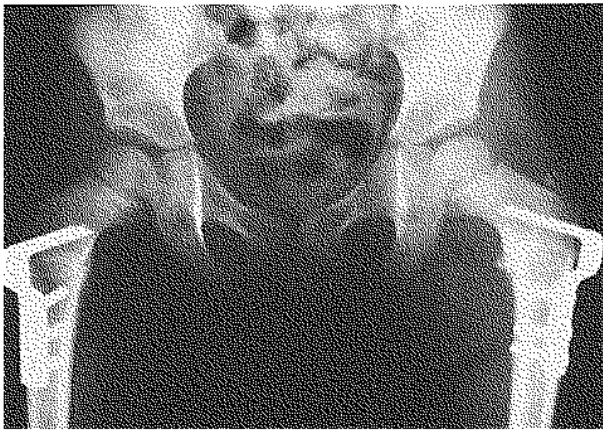By our current thinking, an almost completely normal hip cannot predictably be achieved if corrective surgery is delayed until this age. It would be our preference to treat the dysplasia at a younger age. Although the Pemberton procedure can be performed up to age ten years, we have found that after age eight years acetabular rotation



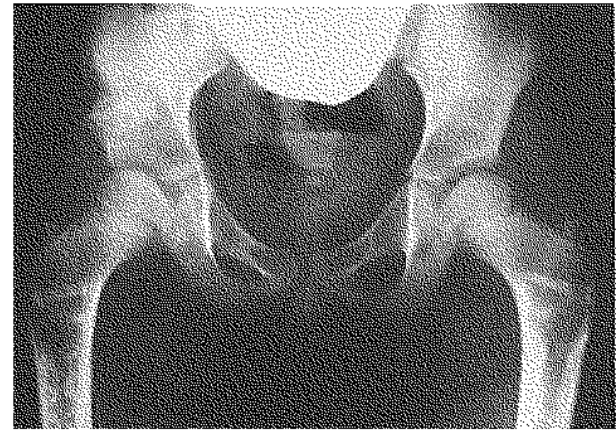
a



c



b



d

**Fig. 5a-d.**

**5a.** — Preoperative AP pelvis radiograph of a 4-year-old female showing subtle bilateral hip dysplasia.

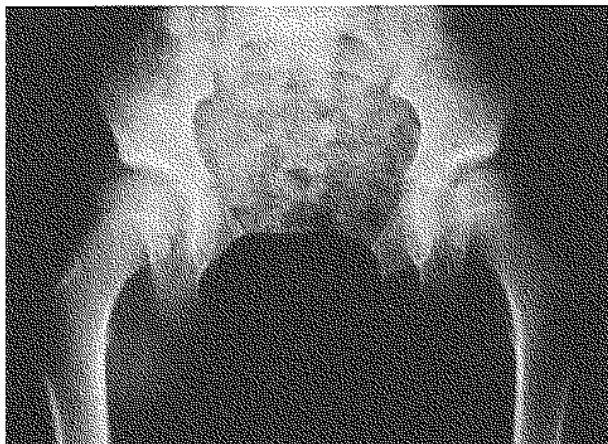
**5b.** — Radiograph 2 months following bilateral proximal femoral osteotomies.

**5c.** — One year follow-up radiograph shows failure of the right acetabulum to improve after varus derotational osteotomy alone.

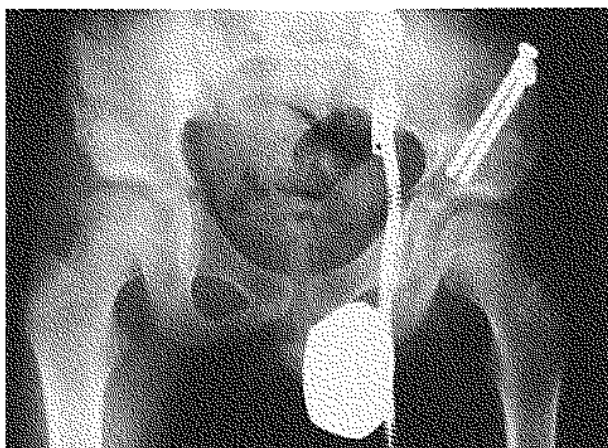
**5d.** — Radiograph taken after Pemberton acetabuloplasty demonstrating normalization of hip radiographic parameters.

is more difficult and that one should consider a method that allows more free acetabular rotation. Thus for children age eight to fourteen years we recommend a triple innominate osteotomy (TIO) (fig. 6). Care must be taken to perform the osteotomy correctly. There are many methods and many approaches to making the cuts both above and below the acetabulum (4, 23, 27). Perhaps the ideal approach to the TIO is the method of Tönnis (27, 28) which allows the inferior cut to be made very near the acetabulum and above the

insertion of the sacrospinous ligament. Unfortunately this approach requires a separate posterolateral incision to safely perform the cut and to avoid nerve injury. Because of this complexity, we use a slightly different approach, making the iliac cut above the acetabulum through an approach identical to that of Salter (21). The superior pubic ramus cut can be made through the same anterolateral incision in a small child or through a separate small-incision just below the inguinal ligament and just lateral to the symphysis pubis



a



b

**Fig. 6a-b.**

**6a.** — Preoperative AP pelvis radiograph of a 10-year-old male shows bilateral hip dysplasia. 3 dimensional CT imaging revealed more severe dysplasia on the left side.

**6b.** — Postoperative AP pelvis radiograph following Pemberton acetabuloplasty on the right hip and triple innominate osteotomy on the left hip. Better coverage was obtained with triple innominate osteotomy despite the more severe dysplasia on that side, as the triradiate cartilage is stiffer at this age and limits rotation following a Pemberton procedure.

in an older child. We perform the ischial cut through a small longitudinal incision over the tip of the ischial tuberosity with temporary detachment of the adductor magnus and a small segment of the origin of the hamstrings. The ischium can then be identified and should be cut very proxi-

mally, just below the acetabulum. This allows relatively free rotation of the acetabulum, however, the ischial cut in this approach is made distal to the ischial spine and thus the rotation is not quite as free as with the method of Tönnis.

A second approach, which we often use, is to make both the superior pubic ramus and the ischium cuts through a single transverse medial groin incision. We do not re-prep and re-drape to make the ischial cut as originally described by Steele (23, 24) and believe that the procedure can be performed with safety and sterility using a single surgical preparation.

Many errors can be made in performing the triple innominate osteotomy. Perhaps the most severe is to excessively externally rotate the acetabular fragment which predisposes to nonunion in either the pubic ramus or ischial sites and also may cause undesired retroversion (7). We now use a temporary Schanz screw in the acetabular segment (as described by Ganz for the periacetabular osteotomy) to serve as a guide to direct the acetabulum anteriorly and avoid external rotation. We do not use the figure-of-four maneuver (abduction and external rotation of a single hip) since it encourages undesired acetabular external rotation.

Our studies and others have clarified that many if not most children with residual hip dysplasia have normal or modestly increased acetabular anteversion (12) and that one should not attempt to radically externally rotate the acetabulum in making a correction (15). Another method to avoid excessive external rotation includes a temporary K-wire marker in the superior ilium as well as the acetabular segment while positioning the fragment for placement of the triangular bone graft (as described by Tönnis) (27). Once the acetabular fragment has been properly rotated forward with the graft positioned, it is temporarily fixed with K-wires and image studies are used to confirm a level source and ideal positioning of the segment. We then use fully threaded AO screws to fix the osteotomy (fig. 6). The child is kept in a hip spica for six weeks and non-weight bearing for twelve weeks.



### Treatment of acetabular dysplasia over age fourteen years — triradiate cartilage closed

Again in this age group of patients the results are less predictable than if the dysplasia had been surgically corrected as a young child. Any center that carefully analyzes their results will find a significant percentage of patients with residual limp, heterotopic bone formation, pseudarthrosis, external rotation of the fragment and other problems related to the complexity of surgery in teenage and young adult patients. Because of the lack of symptoms in younger patients, however, many will not present for treatment until their teenage years and will need to be treated at this older age.

The classic approach for correcting dysplasia in this patient is the triple innominate osteotomy as we do in children age eight to fourteen years. Often an associated proximal femoral osteotomy is required to normalize the femoral head acetabular relationship.

A second and quite attractive option is the Bernese periacetabular osteotomy (Ganz) which can be performed once the triradiate cartilage is closed (8, 17, 29). This procedure is considered as more difficult to perform than TIO and requires extensive training, first in the anatomy laboratory and then by observing the procedure performed by a skilled surgeon. The procedure has several advantages in that the posterior column behind the acetabulum is not cut completely (as it is in the TIO or Salter procedure), and accordingly the osteotomy is much more stable. Also neither the sacrospinous nor sacrotuberous ligaments are left attached to the acetabular fragment, allowing freer rotation and perhaps less chance for undesired external rotation. After screw fixation, the patient can be mobilized without cast immobilization. This is a great advantage to the teenage patient. There is an increased risk for blood loss and/or nerve injury with this procedure and thus it should not be approached lightly. Our advice is that one first learn the Salter procedure, then graduate to the triple innominate, and then finally consider the Ganz procedure.

### Summary — San Diego Children's Hospital approach

Our treatment protocol aims to normalize the radiographic anatomy in a child with hip dysplasia by age six years. Despite use of both plain films and 3-D CT studies, we still sometimes find it difficult to make a decision as to when to intervene in a borderline case. In children without a break in Shenton's line, the Pemberton acetabuloplasty appears to be ideal in a child under age eight years. If there is a marked break in Shenton's line or marked coxa valga and/or femoral anteversion, we also add a femoral osteotomy. Using this approach, our early review reveals that approximately 95% of patients can have normal hip morphology by age five to six years with a very low surgical complication rate. We believe that this approach gives the best prognosis for long term adult hip function in a child with residual hip dysplasia.

### REFERENCES

1. Aronson J. Osteoarthritis in the young adult hip: Etiology and treatment. In: Anderson L. D., ed. Instructional Course Lectures XXV, Pages 119-128. CV Mosby, St. Louis, MO, 1986.
2. Brand R. A. Hip osteotomies: A biomechanical consideration. *J. Am. Acad. Orthop. Surg.*, 1997, 5, 282-291.
3. Browning W. H., Rosenkrantz H., Tarquino T. Computed tomography in congenital hip dislocation. *J. Bone Joint Surg.*, 1982, 64-A, 27-31.
4. Carlouz H., Khouri N., Hulin P. Ostéotomie pelvienne triple juxtacotyloïdienne. *Rev. Chir. Orthop.*, 1982, 68, 497-501.
5. Cooperman D. R., Wallensten R., Stulberg S. D. Acetabular dysplasia in the adult. *Clin. Orthop.*, 1983, 175, 79-85.
6. Faciszewski T., Kiefer G. N., Coleman S. S. Pemberton osteotomy for residual acetabular dysplasia in children who have congenital dislocation of the hip. *J. Bone Joint Surg.*, 1993, 75-A, 643-649.
7. Frick S. L., Wenger D. R., Kim S.-S., White G. 1998. Technique for triple innominate osteotomy based on 3D CT scan analysis of complications. Pediatric Orthopaedic Society of North America, 1998 Annual Meeting, Cleveland, OH.

8. Ganz R., Klaue K., Vinh T. S., Mast J. W. A new periacetabular osteotomy for treatment of hip dysplasias : Technique and preliminary results. *Clin. Orthop.*, 1988, 232, 26-36.
9. Gugenheim J. J., Gerson L. P., Tullos H. S. Pathologic morphology of the acetabulum in paralytic and congenital hip instability. *J. Ped. Orthop.*, 1982, 2, 397-400.
10. Hadley N. A., Brown T. D., Weinstein S. L. The effects of contact pressure elevations and aseptic necrosis on the long term outcome of congenital hip dislocation. *J. Orthop. Res.*, 1990, 8, 504-513.
11. Harris W. H. Etiology of osteoarthritis of the hip. *Clin. Orthop.*, 1986, 213, 20-33.
12. Jacquemier M., Jouve J. L., Bollini G., Panuel M., Migliani R. Acetabular anteversion in children. *J. Ped. Orthop.*, 1992, 12, 373-375.
13. Kasser J. R., Bowen J. R., MacEwen G. D. Varus derotation osteotomy in the treatment of persistent dysplasia in congenital dislocation of the hip. *J. Bone Joint Surg.*, 1985, 67-A, 195-202.
14. Kim H. T., Wenger D. R. The morphology of residual acetabular deficiency in childhood hip dysplasia : Three dimensional computed tomographic analysis. *J. Ped. Orthop.*, 1997, 17, 637-647.
15. Kim S. S., Frick S. L., Wenger D. R. Acetabular anteversion : A computed tomography study. submitted to *J. Ped. Orthop.*, 1998.
16. Lindstrom J. R., Ponseti I. V., Wenger D. R. Acetabular development after reduction in congenital dislocation of the hip. *J. Bone Joint Surg.*, 1979, 61-A, 112-118.
17. Millis M. B., Murphy S. B., Poss R. Osteotomies about the hip for the treatment and prevention of osteoarthritis. In : Pritchard D. J., ed. *Instructional Course Lectures*, Pages 209-226. American Academy of Orthopaedic Surgeons, Rosemont, IL, 1996.
18. Pemberton P. A. Pericapsular osteotomy of the ilium for treatment of congenital subluxation and dislocation of the hip. *J. Bone Joint Surg.*, 1965, 47-A, 65-86.
19. Peterson H. A., Klassen R. A., McLeod R. A., Hoffman A. D. The use of computerised tomography in dislocation of the hip and femoral neck anteversion in children. *J. Bone Joint Surg.*, 1981, 63-B, 198-208.
20. Ponseti I. V. Growth and development of the acetabulum in the normal child. *J. Bone Joint Surg.*, 1978, 60-A, 575-585.
21. Salter R. Innominate osteotomy in the treatment of congenital hip dislocation and subluxation of the hip. *J. Bone Joint Surg.*, 1961, 43-B, 518-539.
22. Schoenecker P. L., Anderson D. J., Capelli M. The acetabular response to proximal varus rotational osteotomy : Results after failure of post-reduction abduction splinting in patients who had congenital dislocation of the hip. *J. Bone Joint Surg.*, 1995, 77-A, 990-997.
23. Steele H. H. Triple innominate osteotomy of the innominate bone. *J. Bone Joint Surg.*, 1973, 55, 343-350.
24. Steele H. H. Triple osteotomy of the innominate bone. *Clin. Orthop.*, 1977, 122, 116-127.
25. Stulberg S. D., Cooperman D. R., Wallensten R. The natural history of Legg-Clave-Perthes disease. *J. Bone Joint Surg.*, 1981, 63-A, 1095-1108.
26. Stulberg S. D., Cordell L. D., Harris W. H. Unrecognized childhood hip disease : A major cause of idiopathic osteoarthritis of the hip. *The Hip : Proceedings of the Third Open Scientific Meeting of The Hip Society*, Pages 212-220. CV Mosby, St. Louis, MO, 1975.
27. Tönnis D. Pelvic operations for dysplasia of the hip in D. Tönnis, ed. *Congenital dysplasia and dislocation of the hip*. Pages 356-385. Springer-Verlag, Heidelberg, 1987.
28. Tönnis D., Arning A., Bloch M., Heinecke A., Kalchschmidt K. Triple pelvic osteotomy. *J. Ped. Orthop. Part*, 1994, B3, 54-67.
29. Trousdale R. T., Ekkernkamp A., Ganz R., Wallrichs S. L. Periacetabular and intertrochanteric osteotomy for the treatment of osteoarthritis in dysplastic hips. *J. Bone Joint Surg.*, 1995, 77, 73-85.
30. Tucci J. J., Kumar S. J., Guille J. T., Robbo E. R. Late acetabular dysplasia following early successful Pavlik harness treatment of congenital dislocation of the hip. *J. Ped. Orthop.*, 1991, 11, 502-505.
31. Wedge J. H., Wasylenko M. J. The natural history of congenital disease of the hip. *J. Bone Joint Surg.*, 1979, 61-B, 334-338.
32. Weinstein S. L. Natural history of congenital hip dislocation (CDH) and hip dysplasia. *Clin. Orthop.*, 1987, 225, 62-76.
33. Weinstein S. L. Natural history and treatment of childhood hip disorders. *Clin. Orthop.*, 1997, 344, 227-242.
34. Weintraub S., Green I., Terdiman R., Weissman S. L. Growth and development of congenitally dislocated hips reduced in early infancy. *J. Bone Joint Surg.*, 1979, 61-A, 125-30.
35. Wenger D. R., Lee C.-S., Kolman B. Derotational femoral shortening for developmental dislocation of the hip : Special indications and results in the child younger than 2 years. *J. Ped. Orthop.*, 1995, 15, 768-779.

#### SAMENVATTING

*D. R. WENGER, S. L. FRICK. Vroegtijdige chirurgische correctie van dysplasie.*

Studies over de etiologie van premature osteo-artrose van de heup, tonen dat het meestal het gevolg is van residuele heupdysplasie. Deze is vaak asymptomatisch tijdens de kinderjaren, de ontdekking ervan is dus vrij

moeizaam en vereist toch complexe behandelingen (in een asymptomatisch kind). De symptomen zien we pas optreden in de vroege volwassene of op tienerleeftijd. De chirurgische behandeling op dat moment is vaak onvolledig en gecompliceerd. Daartegenover staat dat wanneer de dysplasie vroegtijdig wordt erkend de chirurgische correctie met simpelere osteotomies tot meer voorspelbare resultaten kan leiden. Onze ervaring met kinderen, adolescenten en volwassenen, met residuele heupdysplasie, heeft geleid tot het aannemen van een filosofie waarbij de chirurgische correctie vroegtijdig wordt uitgevoerd om tot een normale heupmorfologie te komen op de leeftijd van 5 à 6 jaar.

In dit artikel worden de methode en de vroegtijdige resultaten geëvalueerd.

### RÉSUMÉ

*D. R. WENGER, S. L. FRICK. Correction chirurgicale précoce de la dysplasie résiduelle du cotyle : conception du San Diego Children's Hospital.*

Lorsqu'on recherche l'étiologie de la coxarthrose précoce, on s'aperçoit que la cause la plus habituelle

est une dysplasie résiduelle de la hanche remontant à l'enfance. La dysplasie de la hanche est souvent asymptomatique dans l'enfance, ce qui rend son diagnostic difficile, tout comme le choix thérapeutique (chirurgie majeure chez un enfant asymptomatique). En général, les symptômes n'apparaissent qu'à l'adolescence ou chez l'adulte jeune, et une correction chirurgicale à cet âge est souvent incomplète et compliquée. Au contraire, si la dysplasie est reconnue très tôt, elle peut être corrigée chirurgicalement par des ostéotomies plus simples dont les résultats seront plus prévisibles. Notre expérience du traitement de la dysplasie résiduelle de la hanche chez l'enfant, l'adolescent et l'adulte, nous a conduits à adopter une philosophie correspondant à une correction chirurgicale précoce qui cherche à normaliser la morphologie de la hanche à l'âge de 5 ou 6 ans. Le raisonnement, les méthodes et les premiers résultats de cette politique sont passés en revue dans cet article.