

# LONG-TERM RESULTS AFTER MITCHELL OSTEOTOMY IN CHILDREN AND ADOLESCENTS WITH HALLUX VALGUS

A. KARBOWSKI, M. SCHWITALLE, A. ECKARDT, J. HEINE

The current study elucidates the quality of long-term results after hallux valgus correction by Mitchell osteotomy in children and adolescents.

Eight female and 1 male hallux valgus patient with a total of 16 bunion deformities underwent a Mitchell procedure in the period 1970 to 1985, and were reinvestigated in December 1994 (at an average of 16 years later). Their ages at operation ranged from 9 to 20 years (average 16 years). Patients' data were subdivided into subjective and objective criteria. Subjective parameters such as pain, shoe fitting, mobility and cosmesis were assessed by interview. Objective data were obtained from reports, radiographs and physical examination. Owing to the lack of established and recommended scores, we developed our own evaluation pattern.

Overall outcome was judged as good in 69%, satisfying in 12% and dissatisfying in 19% by both patients and surgeon.

In our experience, Mitchell osteotomy is an appropriate method for young hallux valgus patients, especially in forefeet with rigid malformation or moderately severe hallux valgus and metatarsus primus varus. Extensive metatarsal shortening should be excluded preoperatively in order to avoid postoperative metatarsalgia.

**Keywords :** hallux valgus ; metatarsus primus varus ; Mitchell osteotomy ; children ; adolescents.

**Mots-clés :** hallux valgus ; metatarsus primus varus ; ostéotomie de Mitchell ; enfant ; adolescent.

---

## INTRODUCTION

The so-called Mitchell osteotomy is derived from a lateral displacement of the metatarsal neck osteotomy introduced by Hawkins (5) in 1945. He developed it from procedures described by Hoh-

mann (6) in 1923 and Peabody (10) in 1931. Based on a detailed follow-up study, Mitchell *et al.* optimized Hawkins' hallux valgus correction in 1958 (9). Their osteotomy-bunionectomy was a conceptually sound procedure. Its crucial points are a lateral displacement osteotomy of the first metatarsal neck, to correct the metatarsus primus varus, and a medial capsulorrhaphy and reefing of the adductor hallucis, respectively, to eliminate the hallux valgus component.

Although the technique itself was promising, in the following period a high incidence of complications, including lateral metatarsalgia, avascular necrosis, and persistence or recurrence of hallux valgus led to preference for other procedures for hallux valgus surgery (8, 14).

The current study analyzes long-term results after Mitchell osteotomy in young patients with regard to its special advantages, disadvantages, surgical challenges and limits of indications. This might facilitate the decision whether the Mitchell osteotomy is advisable and help to avoid postoperative complications.

## MATERIAL AND METHODS

### Patients

From 1970 to 1985, 8 females and 1 male patient underwent a total of 16 Mitchell osteotomies in the

---

Orthopedic Department of the University Clinic Hospital, Mainz, Germany.

Correspondence and reprints : A. Karbowski, Orthopädische Universitätsklinik Mainz, Langenbeckstr. 1, D-551 01 Mainz, Germany.

Orthopedic Department of the University Hospital, Mainz. Their ages at operation ranged from 9 to 20 years (average 16 years). All of them presented for a follow-up assessment in December 1994 after an average observation period of 16 years (range 10 to 25 years).

### Evaluation criteria

The reinvestigation included both subjective and objective criteria. Subjective parameters were assessed by interview. Patients were asked explicitly about pain (duration, development, dynamics, localization and extent) and problems with shoe-fitting, mobility and cosmetics.

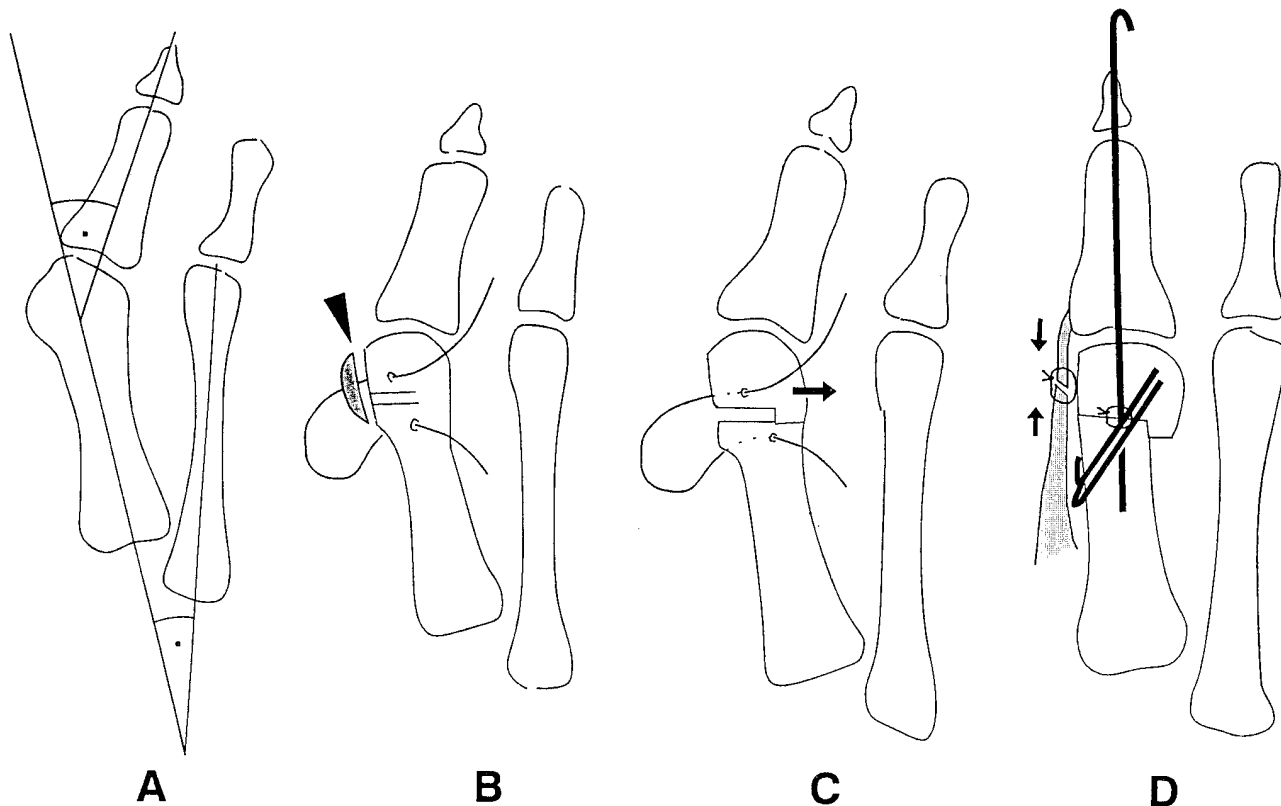
Objective criteria also consisted of morphological and functional parameters. They were obtained by radiograph, physical examination and reports, respectively. Morphology was measured by standing (weight-bearing) a.p. and lateral radiographs. Hallux valgus angle (HV-angle, physiologically  $< 16^\circ$ ) and intermetatarsal angle I-II (IM-angle, physiologically  $< 9^\circ$ ) were

deemed most appropriate for characterization of hallux valgus and metatarsus primus varus. Moreover, pre- and postoperative metatarsal shortening as well as osteoarthritic changes in the metatarsophalangeal joint completed radiological findings (8, 11, 12).

Physical examination included active and passive range of motion of the metatarsophalangeal joint as well as force of the great toe and its capacity to roll over the first ray (medial side of the foot) when walking.

### Surgical technique

Mitchell's original technique (9) was altered by fixing both fragments with Kirschner wires (Fig. 1). Additional stabilization of the first ray was achieved by temporary, percutaneous Kirschner wires (removal 2 weeks postoperatively) and cast dressings until satisfactory callus had formed. In this way, we hoped to improve the durability of correction and to decrease the frequency of malunion, dislocation or recurrence.



**Fig. 1.** — Mitchell procedure.

a. Bunion deformity (HV-, IM-angle).

b. Excision of the medial eminence, placement of drill holes, preliminary osteotomy cuts, application of sutures.

c. Completion of the second osteotomy cut ; lateral displacement of osteotomy site with slight plantar flexion.

d. Stabilization : permanent Kirschner wires for both fragments, temporary Kirschner wire for the first ray, medial capsulorrhaphy.

Table I. — Overall outcome

Criteria	good	satisfying	dissatisfying
Pain relieved	++	+	-
Mobility unlimited	++	+	-
Cosmesis improved	++	+	-
Hallux valgus $\sphericalangle$	$< 20^\circ$	20-25°	$> 25^\circ$
Intermetatarsal $\sphericalangle$	$< 11^\circ$	11-15°	$> 15^\circ$
Range of motion Limitation, MP-I-joint	-	$\approx \frac{1}{4}$	$> \frac{1}{2}$
Osteoarthritis MP-I-joint	-	beginning*	manifest*

\* Osteoarthritic changes : narrowing of the joint space, periarticular spurs, subchondral cysts, articular sclerosis.

## RESULTS

The evaluation of patients' histories showed metatarsalgia combined with painful metatarsophalangeal joints in 19% (3 feet), so that they complained mainly about painful limitation of mobility and problems with wearing shoes.

Correspondingly, radiographs and physical examination of the patients revealed HV-angles  $> 25^\circ$ , IM-angles  $> 15^\circ$  manifest osteoarthritis with painful limitation of active and passive great toe motion by 50% or even more. These cases were considered to be dissatisfying (Table I).

Two patients (12%) had no complaints, but showed mild recurrence. Their HV-angle ranged from  $20^\circ$  to  $25^\circ$  and IM-angle from  $11^\circ$  to  $15^\circ$ , respectively. Osteoarthritic changes were just beginning and limitation of mobility was about 25% (Table I). Nevertheless, surgical intervention seemed to be justified by the comparison with preoperative findings.

The remaining 69% (11 feet) suffered neither from pain nor from functional disability. Their HV- and IM-angles were  $< 20^\circ$  and  $< 11^\circ$ , respectively. Osteoarthritic changes could not be detected. These patients achieved good overall results according to their opinions and that of the surgeon.

## DISCUSSION

Concerning the present study, two main aspects should be emphasized. One is the importance of Mitchell osteotomy among the large number of more than 130 hallux valgus correction techniques. Apart from this, it is questionable, if or rather at what time surgical treatment is indicated in young hallux valgus patients (1, 8).

The current study attains a special significance by the comparatively long follow-up (average 16 years) and low average-age group of the study population (16 years). Most hallux valgus patients are adults, but in contrast to adult-onset hallux valgus, surgical treatment is less frequently indicated. For young patients with mild to moderately severe hallux valgus deformity, it is advisable to play a waiting game with regular follow-up examinations, shoe modifications and orthotics. Worsening pain and progression of the deformity justify surgical intervention, above all if the patient has a positive family history. However, the selection of procedures is limited in this age-group, as so-called "physiological techniques" preserving the integrity of the metatarsophalangeal joint are preferable. Mitchell osteotomy is unconditionally recommended in young patients, as there is no growth plate at the distal end of the first metatarsal, which is the operation site (7, 9, 12).

Reports by Canale *et al.*, Hawkins *et al.*, Luba *et al.* and Mann (4, 5, 7, 8), as well as our own results confirm this consideration, although the aforementioned authors derive their experience from shorter observation periods and older patients.

On the other hand, Ball *et al.* (2) noted a recurrence rate of 61% and a high incidence of metatarsalgia and plantar dislocation of the distal fragment (22 to 44%). Blum *et al.* (3) also reported a high incidence of complications including avascular necrosis or incomplete correction and persistence of hallux valgus, which led to a loss of interest in the Mitchell procedure. As Mitchell once developed his technique based on successful and promising follow-up studies, one may wonder whether dissatisfying results might result at least partly from improper technique or case selection. Shapiro and Heller (13) described typical steps of the operation deserving special attention. A critical analysis of their study population showed that most of the unsuccessful results could have been avoided and were directly traceable to errors in

technique or indication. We can confirm this observation, as the following case report shows :

A 17-year-old patient with severe hallux valgus deformity (HV-angle  $41^\circ$ , IM-angle  $18^\circ$ ) (13) and progression of pain, shoe problems and recurrent bunion inflammation underwent hallux valgus surgery (Fig. 2). Although preoperative metatarsal shortening was remarkable and additional shortening should have been avoided, Mitchell osteotomy was performed. The reexamination 16 years later revealed recurrence of hallux valgus (HV-angle  $39^\circ$ , IM-angle  $12^\circ$ ) and an excessive metatarsal shortening with metatarsalgia, painfully limited motion in the metatarsophalangeal joint, mild pseudoexostosis, beginning hammer toe in the second and third ray, plantar callosity and bursitis. The patient's complaints were the same as preoperatively, so that his disappointment was rather understandable.

In another case, the patient's history began similarly (Fig. 3). The first symptoms occurred in

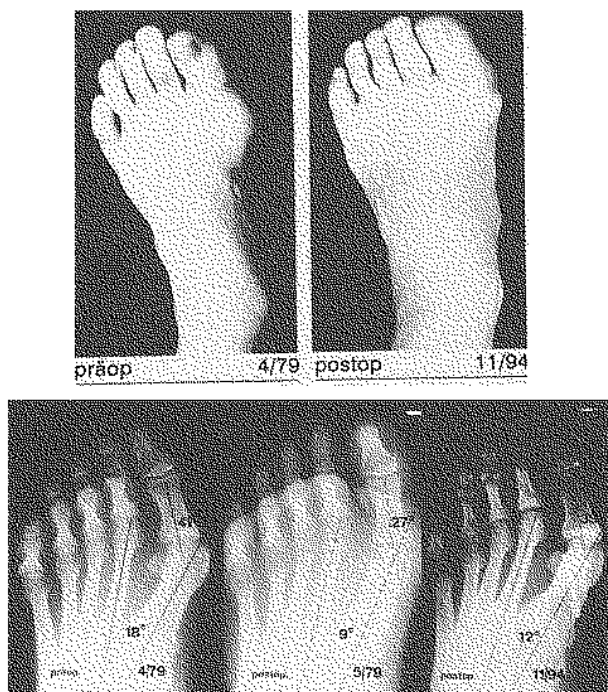


Fig. 2. — Dissatisfying result after Mitchell osteotomy : pre- and postoperative clinical appearance and radiographs.

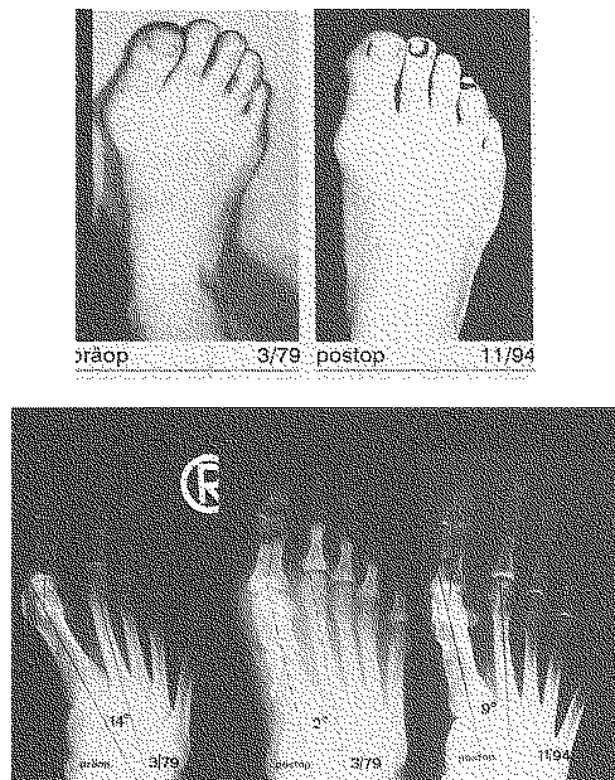


Fig. 3. — Good result after Mitchell osteotomy : pre- and postoperative clinical appearance and radiographs.

the twelfth year of life. Over the following 6 years, the bunion deformity worsened markedly and led to worsening pain, shoe problems and inflammatory bunion. With these complaints, the young woman, by then 18 years old, presented to our clinic. Radiographs showed moderately severe hallux valgus (HV-angle 33°, IM-angle 14°). Metatarsal shortening was negligible, so that postoperative metatarsalgia was rather unlikely. Sixteen years after Mitchell osteotomy, she returned for reexamination. She had no pain or shoe problems and no limitation of the big toe mobility, and she was completely satisfied with the outcome. HV- and IM-angle were 19° and 9°, respectively. The first metatarsal was moderately shortened and the metatarsophalangeal joint did not show any osteoarthritic changes.

Results of physical examination were also inconspicuous and contributed to a good overall outcome.

### CONCLUSIONS

Reevaluation of young hallux valgus patients an average of 16 years after Mitchell osteotomy confirmed that the possibility of simultaneous correction of hallux valgus and metatarsus primus varus is one of its main advantages. Thus, special etiologic aspects of this age-group are considered.

An unavoidable disadvantage of Mitchell osteotomy is the inherent metatarsal shortening which is often associated with metatarsalgia. Therefore, a preoperative metatarsal shortening of more than 4 mm on the radiograph is considered to be a contraindication.

In our experience, the Mitchell procedure is indicated for young patients with moderately severe hallux valgus (HV-angle < 40°) and metatarsus primus varus (IM-angle < 20°).

### REFERENCES

1. Akin O. F. The hallux valgus. In : P. Jahss. Disorders of the foot, Vol. I, Saunders, Philadelphia, 1982, pp. 539-547.
2. Ball J., Sullivan J. A. Treatment of the juvenile bunion by Mitchell osteotomy. *Orthopedics*, 1985, 8, 1249-1251.

3. Blum J. L. The modified Mitchell osteotomy- bunioneectomy : indications and technical considerations. *Foot Ankle*, 1994, 15, 103-106.
4. Canale P. B., Aronsson D. D., Lamont R. L., Manoli A. The Mitchell procedure for the treatment of adolescent hallux valgus. *J. Bone Joint Surg.*, 1993, 75-A, 1610-1618.
5. Hawkins F. B. Correction of hallux valgus by metatarsal osteotomy. *J. Bone Joint Surg.*, 1945, 37-A, 387-394.
6. Hohmann G. Über Hallux valgus und Spreizfuß, ihre Entstehung und physiologische Behandlung. *Acta Orthop. Chir.*, 1923, 21, 525-533.
7. Luba R., Rosman M. Bunions in children : Treatment with a modified Mitchell osteotomy. *J. Pediatr. Orthop.*, 1984, 4, 44-47.
8. Mann R. A. Distaler Weichteileingriff und proximale Metatarsalosteotomie. In : C. J. Wirth, R. Ferdini, N. Wuelker, Vorfußdeformitäten. Springer, Heidelberg, 1993, pp. 289-299.
9. Mitchell C. Osteotomy-bunioneectomy for hallux valgus. *J. Bone Joint Surg.*, 1958, 40-A, 41-60.
10. Peabody C. W. The surgical care of hallux valgus. *J. Bone Joint Surg.*, 1931, 13-A, 273-281.
11. Scott G., Wilson D. W., Bentley G. Roentgenographic assessment in hallux valgus. *Clin. Orthop.*, 1991, 167, 143-147.
12. Scranton P. E. Adolescent bunions diagnosis and management. *Pediatr. Ann.*, 1982, 11, 518-520.
13. Shapiro F., Heller L. The Mitchell distal metatarsal osteotomy in the treatment of hallux valgus. *Clin. Orthop.*, 1975, 107, 225-231.
14. Viladot A. Metatarsalgia due to biomechanical alterations of the forefoot. *Orthop. Clin. N. Am.*, 1973, 4, 165-169.

### SAMENVATTING

A. KARBOWSKI, M. SCHWITALLE, A. ECKARDT, J. HEINE. *Lange-termijnresultaten na Mitchell-osteotomie bij kinderen en volwassenen met hallux valgus.*

Het huidige onderzoek beoogt de kwaliteit aan te tonen van de lange-termijnresultaten na correctie van hallux valgus bij kinderen en volwassenen door Mitchell-osteotomie.

In de periode 1970 tot 1985 onderging een groep van 8 vrouwelijke en 1 mannelijke hallux valgus patiënten met in totaal 16 eeltknobbel vergroeiingen de Mitchell-behandeling. Zij werden in 1994 (gemiddeld 16 jaar na de behandeling) opnieuw onderzocht. De leeftijd tijdens de behandeling was tussen 9 en 20 jaar (gemiddeld 16 jaar). Patiëntengegevens werden onderverdeeld in subjectieve en objectieve criteria. Subjectieve parame-

ters, zoals pijn, al of niet passende schoenen, mobiliteit en aspect, werden door ondervraging vastgesteld. Objectieve gegevens waren afkomstig uit rapporten, röntgenfoto's en uit klinisch onderzoek. Bij gebrek aan bestaande scores werd een zelfontwikkeld evaluatiepatroon gebruikt. De algemene uitkomst is dat volgens patiënten en chirurgen 69% van de behandelingen een goed resultaat had, 12% een bevredigend resultaat, en 19% een onbevredigend resultaat.

Op grond van onze ervaring is de Mitchell-osteotomie een passende methode voor jonge hallux valgus patiënten, vooral bij voorvoel met verstijfde misvorming of bij gematigd ernstige hallux valgus en metatarsus primus varus. Van uitgebreide middenvoetsverkorting dient voor de operatie te worden afgezien om post-operatieve metatarsalgie te voorkomen.

### RÉSUMÉ

*A. KARBOWSKI, M. SCHWITALLE, A. ECKARDT, J. HEINE. Résultats à long terme de l'ostéotomie de Mitchell pour hallux valgus chez l'enfant et l'adolescent.*

Cette étude a pour objectif d'évaluer les résultats à long terme de la correction d'un hallux valgus par ostéotomie de Mitchell chez l'enfant et l'adolescent.

Huit filles et 1 garçon présentant au total 16 déformations de type hallux valgus ont été opérés selon la technique de Mitchell entre 1970 et 1985 et ont été réévalués en décembre 1994 (en moyenne 16 ans plus tard). Au moment de l'opération, ils étaient âgés de 9 à 20 ans (moyenne 16 ans). Les données subjectives comme la douleur, la difficulté de chaussage, la marche et l'esthétique, ont été relevées par interrogatoire tandis que les données objectives ont été obtenues par l'examen clinique et radiologique. En l'absence d'un score d'évaluation établi et reconnu, nous avons appliqué un score personnel.

Les patients, et aussi le chirurgien ont jugé les résultats globaux comme étant bons dans 69% des cas, satisfaisants dans 12% et insuffisants dans 19% des cas.

Dans notre expérience, l'ostéotomie de Mitchell est une technique appropriée pour les jeunes patients souffrant de hallux valgus, particulièrement dans les avant-pieds rigides ou dans des cas modérés de hallux valgus et de metatarsus primus varus. Avant l'opération, il faut exclure une brièveté importante du premier métatarsien afin d'éviter une métatarsalgie post-opératoire.