

CASE REPORT

ACUTE PARAPLEGIA DUE TO THORACIC EXTRAMEDULLARY HEMATOPOIESIS IN CHRONIC MYELOPROLIFERATIVE DISORDER – AN UNUSUAL PRESENTATION

Y. H. CHANG¹, C. C. NIU², L. H. CHEN², W. J. CHEN²

Spinal cord compression due to extramedullary hematopoiesis is a well-known complication in a number of hematological diseases. Most of the patients present with progressive paraparesis due to the slow expansion of the extramedullary hematopoietic tissue.

The authors report a case of chronic myeloproliferative disorder with spinal extramedullary hematopoiesis presenting with acute paraplegia. Chronic myeloproliferative disorder is an uncommon cause of spinal cord compression, especially when associated with acute paraplegia. The authors discuss the pathomechanism of this unusual presentation.

Keywords : acute paraplegia ; extramedullary hematopoiesis ; chronic myeloproliferative disorder.

Mots-clés : paraplégie aigue ; hématopoïèse extramédullaire ; myélopathie chronique.

INTRODUCTION

Spinal cord compression due to extramedullary hematopoiesis is a well-known complication in a number of hematological diseases, including thalassemia, myelofibrosis, and polycythemia rubra vera (12). Most patients present with progressive paraparesis due to the slow expansion of the extramedullary hematopoietic tissue (3, 6, 13). We report a case of extramedullary hematopoiesis presenting with acute paraplegia caused by bleeding from spinal extramedullary hematopoietic tissue. To the best of our knowledge, this is the first case of acute paraplegia caused by spinal extramedullary hematopoiesis in the literature.

A 70-year-old woman suffered from sudden-onset paraplegia due to spinal extramedullary hematopoiesis at the T11 and T12 levels. Chronic myeloproliferative disorder was diagnosed incidentally during this episode. An emergency decompressive laminectomy was done at the lesion level. Chronic myeloproliferative disorder is an uncommon cause of spinal cord compression, especially when presenting with acute paraplegia. We discuss the pathomechanism of this unusual presentation.

CASE REPORT

This 70-year-old woman was quite well and was still able to walk unaided until the morning of her admission, when she awoke unable to move or feel her legs, or retain urine.

She was initially sent to a local hospital, and then transferred to our emergency room. By that time, more than 12 hours had elapsed from the onset of symptoms, and physical examination showed complete bilateral paralysis of the lower legs and complete sensory loss below the T11 level.

¹ Department of Orthopedic Surgery, St. Paul's Hospital, Taoyuan, Taiwan.

² Department of Orthopedic Surgery, Chang Gung Memorial Hospital, Taipei, Taiwan.

Correspondence and reprints : C. C. Niu , Department of Orthopedic Surgery, Chang Gung Memorial Hospital, 5 Fu-Shin Street, Kweishan Hsiang, Taoyuan, Taiwan.

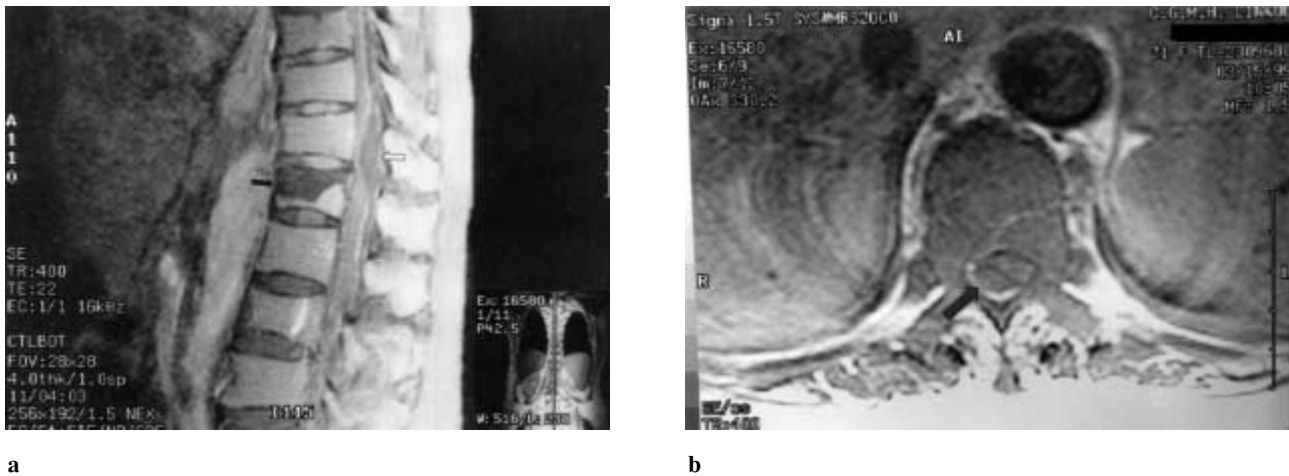


Fig. 1. — MRI of thoracolumbar spine

a) The vertebral body lesion appears as a single T1 hypointensity (solid arrow). The epidural mass appears as a single T1 image with heterogenous signal intensity (open arrow) ; b) An epidural mass lesion with ring enhancement is shown compressing the dural sac to the right and posteriorly at the T11 level (arrow).

Proprioception of bilateral lower extremities was absent. The anal sphincter was flaccid. The neurologic lesion was complete (Frankel class A). An enlarged spleen was palpated 3 cm below the left costal margin.

There was no obvious associated back pain, fever, or chills. The muscle strength in the upper extremities was normal. The patient suffered from non-insulin dependent diabetes mellitus (NIDDM) and primary hypertension, for which she had been treated regularly for 20 years. There was no other history of major systemic disease. The laboratory investigation showed a hemoglobin concentration of 14.9 g/l, total white cell count of 46,400/dl, and platelet count of 1,273,000/dl. The differential white cell count was 73% neutrophils, 2% bands, 16% monocytes, 2% eosinophils and 1% atypical lymphocytes. The ESR and CRP did not show significant elevation. Prothrombin time and partial thrombin time were also within the normal range. Pancytosis with atypical lymphocytes was noted after the laboratory examination. Roentgenogram of the thoracic spine demonstrated a T11, T12 osteolytic lesion. MRI of the thoracolumbar spine revealed an abnormal signal in the T11 and T12 vertebral bodies and the epidural space. These vertebral body lesions showed hypointensity on T1-weighted images, and mild hyperintensity on T2-

weighted images (fig. 1-a). In addition, at T11, an epidural mass lesion compressed the dural sac to the right and posteriorly (fig. 1-b). Abnormal rim enhancement of the epidural lesion after gadolinium enhancement was noted. The MRI findings suggested the presence of an epidural abscess or hematoma.

Owing to the neurologic deficit, emergency decompression laminectomy was performed at 36 hours after the onset of the symptoms. During this operation, an indurate brown bloody mass was discovered in the right posterior epidural space with obvious cord compression extending from T11 to the T12 level. Histological examination of this material showed hematopoietic tissue with necrosis and hematoma (fig. 2). In the T11 and T12 vertebral bodies, there were other extramedullary hematopoietic centers.

Because the peripheral blood smear was abnormal, the hematologist arranged for a bone marrow biopsy after the operation. Bone marrow biopsy from the iliac crest revealed the presence of a chronic myeloproliferative disorder, most likely chronic myelocytic leukemia (CML). Radiotherapy was not performed because of patient refusal. Two months later, the patient died from pulmonary infection and an acute asthma attack. The muscle power of the lower limbs was never recovered.

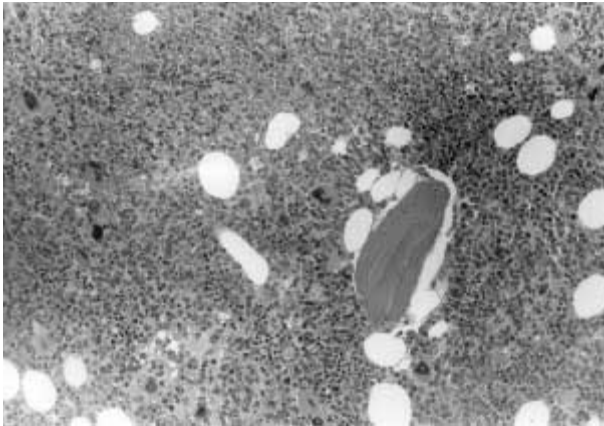


Fig. 2. — Histological examination of the epidural mass showed hematopoietic tissue, compatible with chronic myeloproliferative disorder. This mass shows adipose tissue hypercellularity and greatly increased numbers of granulocytes.

DISCUSSION

The most common sites of extramedullary hematopoiesis are the liver and spleen. Other sites such as kidneys, adrenal glands, pericardium, mediastinum and sclera can also be involved (3, 8). Extramedullary hematopoiesis in the thoracic spine is rather uncommon and most cases have been described as a complication of thalassemia (5).

Spinal cord compression secondary to extramedullary hematopoiesis is rare, especially in patients with a chronic myeloproliferative disorder. Of the reported cases, all have presented with progressive paraparesis due to the slow expansion of extramedullary hematopoietic tissue (3, 13, 6).

There are four chronic myeloproliferative disorders: polycythemia vera (PV), primary thrombocythemia (PT), primary myelofibrosis with myeloid metaplasia (PM), and chronic myelocytic leukemia (CML). CML is the most common of these disorders (4).

The most common clinical manifestations of chronic myeloproliferative disorders are hemorrhage from the gastrointestinal or genitourinary tract and thrombosis of blood vessels, e.a. in the leg, central nervous system or spleen (14). "Spinal stroke" has previously been reported in a case of PV (12). Grunberg *et al.* described an acute

myelopathy that developed in a 53-year-old woman with PV in whom spinal venous thrombosis was demonstrated at autopsy (12). This is the first and only case presented in the literature in which acute paraparesis accompanied a chronic myeloproliferative disorder.

Thomas in 1977 suggested that central nervous system blood flow may be reduced by one-third in polycythemic patients (15). The incidence of venous thrombosis also increases in patients with polycythemia (10). Besides, functional abnormalities of blood platelets are quite common in myeloproliferative disorders (14). Abnormal von Willebrand factor is the reason for abnormal hemostasis in patients with a myeloproliferative disorder (14). The slow blood flow, abnormal coagulation factor and platelet function all contributed to the venous thrombosis. Venous thrombosis of extramedullary hematopoietic tissue may have been the reason for the acute episode in our patient.

In this patient, the extramedullary hematopoietic mass located in the epidural space and the hematoma were the main contributors to the spinal cord compression (fig. 1). The hematopoietic tissue may migrate into the spinal epidural space after vertebral erosion and fracture (1). Spinal stroke accompanied by venous thrombosis, followed by local hemorrhage into the epidural space, may have been the cause of the patient's acute paraplegia.

Decompression laminectomy and radiotherapy have been used to treat extramedullary hematopoiesis associated with chronic myeloproliferative disorder (15). The extramedullary hematopoietic tissue is radiosensitive. In 1979, Stahl *et al.* had reviewed 12 cases with progressive myelopathy due to extramedullary hematopoiesis (13). Ten of the 12 patients were treated with decompression laminectomy, radiation therapy or both. Most of these patients had good to excellent responses: 7 out of 10 recovered substantially or completely neurological functionality. This result was inspiring.

In this case, the poor neurological recovery may have been due to the severe neurologic compression by the hematopoietic mass and hematoma at the beginning (Frankel class A). Besides, a 36 hours delay before the decompression was

another contributing factor. The initial complete neurologic damage and delay in decompression predicted the small chance for recovery (1, 8).

CONCLUSION

Chronic myeloproliferative disorder is an uncommon cause of spinal cord compression, especially when associated with acute paralysis. The bleeding tendency of chronic myeloproliferative disorder and high incidence of venous thrombosis in polycythemia patients may explain this acute presentation. Chronic myeloproliferative disorders should be included in the differential diagnosis of patients with pancytosis and acute spinal neurologic deficit.

REFERENCES

1. Botel U., Glaser E., Niedeggen A. The surgical treatment of acute spinal paralyzed patients. *Spinal Cord*, 1997, 35, 420-428.
2. Coskun E., Keskin A., Suzer T., Sermez Y., Kildaci T., Tahta K. Spinal cord compression secondary to extramedullary hematopoiesis in thalassemia intermedia. *Eur. Spine J.*, 1998, 7, 501-504.
3. De Klippel N., Dehou M. F., Bourgain C., Schots R., De Kayser J., Ebinger G. Progressive paraparesis due to thoracic extramedullary hematopoiesis in myelofibrosis. Case report. *J. Neurosurg.*, 1993, 79, 125-127.
4. Harrison A. S. F. *Principle of Internal Medicine* – 14th ed. McGraw Hill, Inc. New York, 1998, P.679.
5. Ibrahim A. W., Ibrahim E. M., Mitry N. W., Abdul-Satir A., Kuppa A. Spinal cord compression due to intrathoracic extramedullary hematopoiesis in homozygous thalassemia. *J. Neurol. Neurosurg. Psychiatry.*, 1983, 46, 780-782.
6. Jacobs P., Dubovsky D., Commerford P., Price S., Handler L. Agnogenic myeloid metaplasia and spinal cord compression. *S. Afr. Med. J.*, 1979, 55, 256-259.
7. Leupin L., Beck E. A., Furlan M., Bucher U. Hemostasis disorders with reduced activity of the Von Willebrand factor in myeloproliferative syndromes. *Schweiz. Med. Wochenschr.*, 1983, 113, 713-716.
8. Lawton M. T., Porter R. W., Heiserman J. E., Jacobowitz R., Sonntag V. K., Dickman C. A. Surgical management of spinal epidural hematoma : relationship between surgical timing and neurological outcome. *J. Neurosurg.*, 1995, 83, 1-7.
9. Papavasiliou C., Scandilos P. Effect of radiotherapy on symptoms due to heterotopic marrow in β -thalassemia. *Lancet*, 1987, 1, 13-14.
10. Pearson T. C., Wetherley-Mein G. Vascular occlusive episodes and venous hematocrit in primary proliferative polycythemia. *Lancet*, 1978, 2, 1219-1222.
11. Price F., Bell H. Spinal cord compression due to extramedullary hematopoiesis. Successful treatment in a patient with long-standing myelofibrosis. *JAMA*, 1985, 253, 2876-2877.
12. Rice G. P., Assis L. J., Barr R. M., Eber G. C. Extramedullary hematopoiesis and spinal cord compression complicating polycythemia rubra vera. *Ann. Neurol.*, 1980, 7, 81-84.
13. Stahl S. M., Ellinger G., Baringer J. R. Progressive myelopathy due to extramedullary hematopoiesis : Case report and review of the literature. *Ann. Neurol.*, 1979, 5, 485-489.
14. Schater A. I. Bleeding and thrombosis in the myeloproliferative disorders. *Blood*, 1984, 64, 1-12.
15. Thomas D. J., du Boulay G. M., Marshall J., Pearson T. C., *et al.* Cerebral blood flow in polycythemia. *Lancet*, 1977, 2, 161-163.

SAMENVATTING

Y. H. CHANG, C. C. NIU, L. H. CHEN, W. J. CHEN. Acute paraplegie door een haard van extra-medullaire haematopoïese bij een chronisch myeloproliferatief proces van de dorsale wervelzuil : beschrijving van een ongewoon geval.

Chronische myeloproliferatieve processen kunnen leiden naar mergcompressie. Meestal gaat het om een progressieve paraparese door extramedullaire compressie door extramedullaire haematopoïese. De schrijvers beschrijven een zeldzaam geval van acute paraplegie en bespreken de ontstaanswijze van deze ongewone acute verwikkeling.

RÉSUMÉ

Y. H. CHANG, C. C. NIU, L. H. CHEN, W. J. CHEN. Paraplégie aigue secondaire à un foyer d'hématopoïèse extra-médullaire au niveau du rachis dorsal dans une infection myéoproliférative chronique : description d'un cas de présentation inhabituelle.

La compression de la moëlle épinière par un foyer d'hématopoïèse extramedullaire est une complication bien connue qui se rencontre dans de nombreuses affections hématologiques. La plupart des patients présentent une paraparésie progressive due à la lente expansion du tissu

hématopoïétique extramédullaire. Les auteurs rapportent un cas d'affection myéloproliférative chronique avec hématopoïèse extramédullaire au niveau du rachis, qui a présenté une paraplégie aigue. Les affections myéloprolifératives chroniques représentent une cause

rare de compression de la moëlle épinière, en particulier sous forme de paraplégie aigue. Les auteurs analysent le mécanisme pathogénique de ce cas de présentation inhabituelle.