

## CASE REPORT

# PENETRATION INJURY OF THE HINDFOOT FOLLOWING INTRAMEDULLARY NAIL FIXATION OF A TIBIAL FRACTURE

A. A. FARAJ, V. G. JOHNSON

Technical errors during intramedullary nail insertion are not uncommon. We report a case of tibial guide wire penetration into the distal tibial articular surface, the talus and the calcaneus during insertion of the nail with the ankle dorsiflexed. This has not been reported in the past. Computerized tomogram was a useful tool in the diagnosis. This complication was associated with long-standing ankle pain, which however eventually settled.

We advise frequent use of biplanar C-arm image during the insertion of the guide wire, the reamer and tibial nail into the medullary canal of the tibia or other long bones. None of these instruments should be forced through. Once the knobbed guide wire is exchanged to a straight guide wire, the wire should not be forced through or reamed over, and the nail should be introduced over the guide wire with caution.

Early intraoperative identification and recording of this iatrogenic accident is necessary in order to explain the situation to the patient and modify treatment accordingly.

**Keywords** : tibial fracture ; nailing ; penetration ; talus.

**Mots-clés** : fracture du tibia ; enclouage ; pénétration ; astragale.

---

## INTRODUCTION

The preferred fixation of long bone fractures in the lower limb is with an intramedullary locking nail (3, 6). The reported intraoperative complications of nailing have included an eccentric entry portal, problems with reaming, bending of the nail, iatrogenic comminution of the fracture, distraction

of the fragments, extrusion of the nail into the soft tissues, injury of the neurovascular bundle, and penetration of the joint by the nail (3, 5).

We report a case in which penetrating talar body injury occurred during the insertion of the tibial nail.

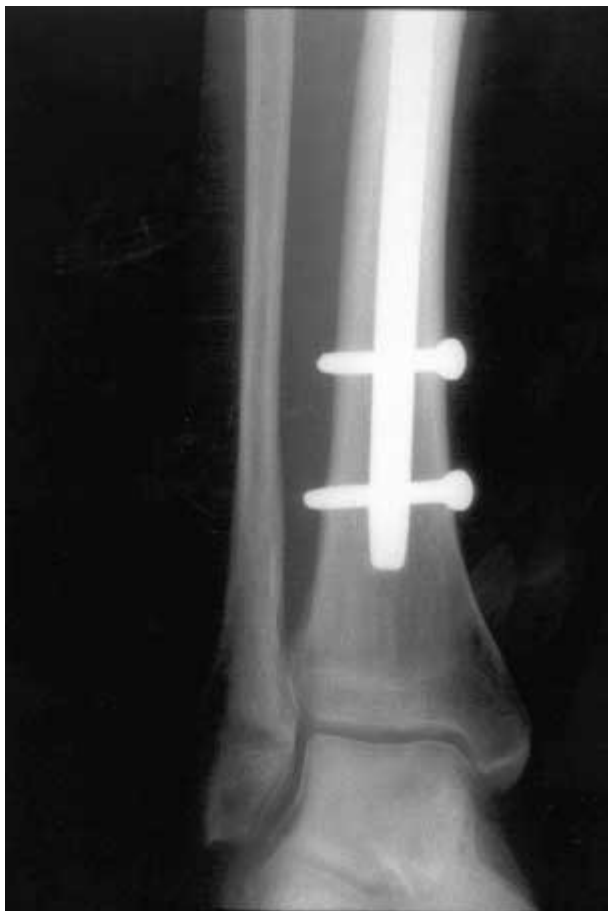## CASE REPORT

A 32-year-old passenger was involved in a road traffic accident and sustained a right Gustilo grade IIIB open tibial fracture and a grade IIIA ipsilateral open femoral fracture. These were treated with emergency wound debridement and washout followed by intramedullary nail fixation of both femur and tibia. There was no associated ipsilateral hind foot fracture seen on plain radiographs of the ankle. The femur was nailed in an antegrade fashion ; the femur was fixed prior to the tibia. Reamed Russell Taylor femoral and tibial nails were used. There was no record of technical difficulties recorded during the operation. Both reaming and insertion of the tibial nail were performed over a 4-mm guide wire. The initial guide wire was knobbed ; this was exchanged to a straight wire after reaming. During the insertion of the guide wire and the nail, the assistant was holding the ankle in extreme dorsi-

---

From the Orthopaedic Department, Hull Royal Infirmary, Analby Road, Hull, United Kingdom.

Correspondence and reprints : A. A. Faraj, 28 Colston Close, Crow Tree Lane, Bradford BD8 0BN. E-mail : adnanfaraj@hotmail.com



*Fig. 1.* — Plain radiograph of the ankle showing the distal locking bolts of the tibial nail and adjacent disuse osteoporosis.

flexion to counteract the force going through the leg during the insertion of the guide wire and during hammering of the guided nail down. A tibial nail with a diameter of 10 mm, was inserted. The wounds and both fractures healed subsequently without further intervention. Both tibial and femoral fractures healed in a six months period. The patient's main residual problem was an intermittent and sharp anterior left ankle pain which became worse during weight bearing.

On examination, the ankle was swollen but not red. On palpation, the ankle joint was however tender. The range of ankle movement was 20° of dorsiflexion and 30° of plantar flexion. The subtalar movement was restricted as well with eversion and inversion of 10°. Plain radiograph of the ankle

(fig. 1) showed no obvious fracture, but disuse osteoporosis. At this stage a computerized tomogram of the hind foot was carried out to identify the cause of pain. This showed a circumscribed translucent area with surrounding sclerosis, with a diameter of about 5-mm in the talar dome. On sagittal images a talar and a calcaneal fracture was seen extending from the articular surface of the talar body down to the subtalar joint and through the calcaneus (fig. 2). There was a similar lesion at the articular surface of the tibia. The radiologist considered these findings genuine and not artefacts.

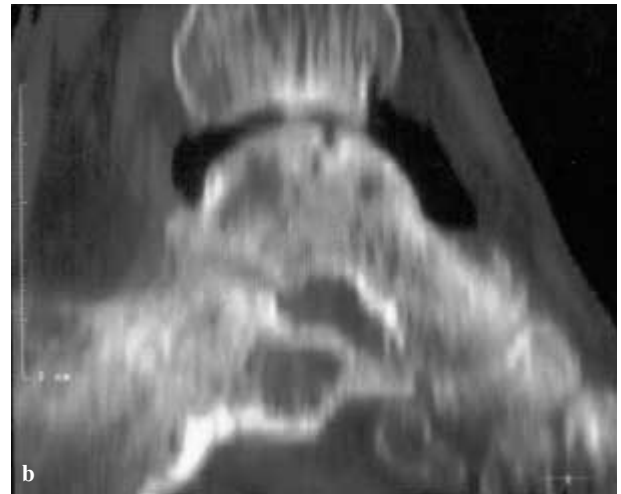
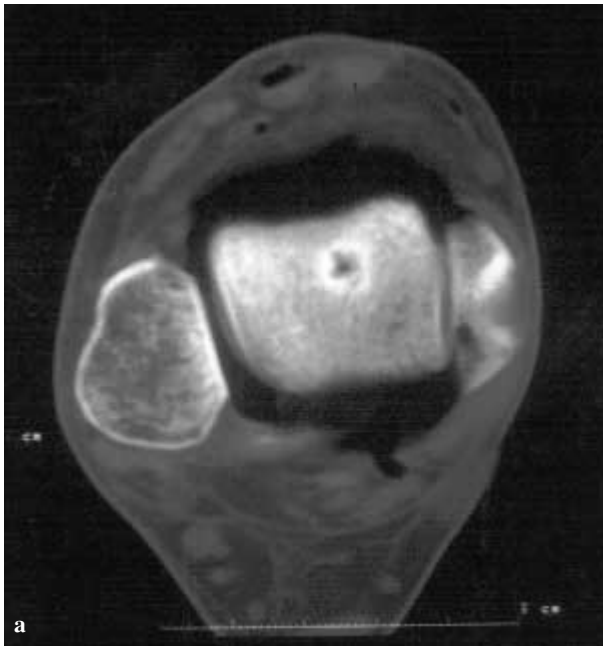
The plane of the tibial plafond, the talar and the calcaneal fractures align when the ankle is put in extreme dorsiflexion. This was the position of the ankle when the wire and the nail were inserted. A plausible explanation for this is that the tibial nail guide wire was forced through the articular surface of the tibia into the talus and the calcaneus by mistake during the procedure.

The patient's ankle pain gradually improved over a period of 18 months, however the ankle remained stiff with 25° dorsiflexion and 30° plantarflexion. The range of movement of the subtalar joint was 10° eversion and 15° inversion.

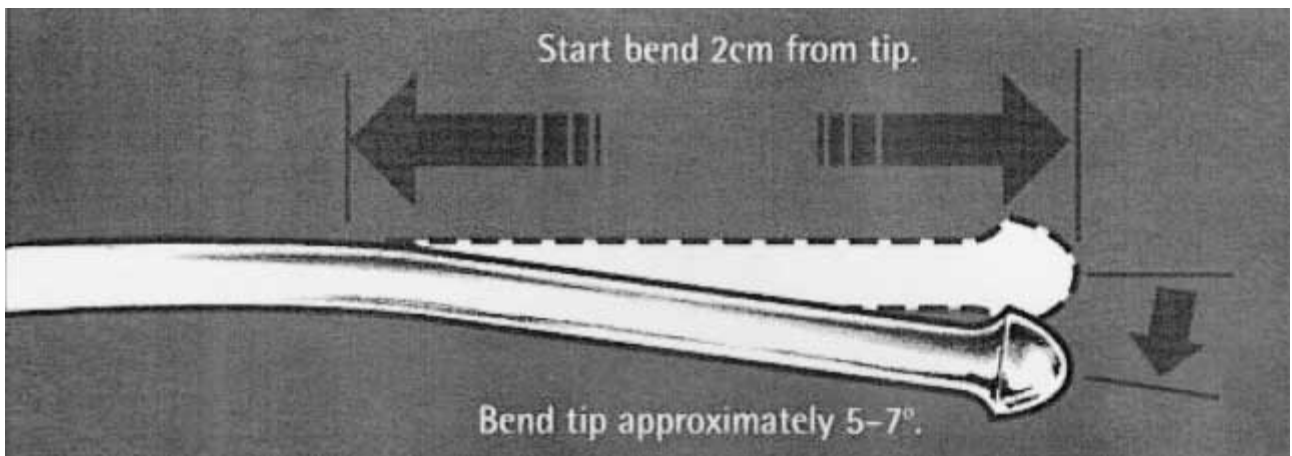
## DISCUSSION

Femoral nail penetration of the knee joint is reported in the literature (6). To our knowledge, we are the first to report a complication of tibial nailing in which a guide wire has penetrated the ankle joint, the talus and the calcaneus.

Although unclear from the notes, this unfortunate complication has probably occurred while reaming on a knobbed guide wire. The knob of the guide wire is almost the same diameter as the hole of the talus seen on CT scan (5 mm). Although this is possible with straight guide wires, it is unlikely to occur with bent knobbed guide wires. The bent tip proximal to the knob prevents penetration into the ankle joint. It is a good practice not to ream on guide wires with no knobs, and no bend at the end (fig. 3). The likely explanation of the current iatrogenic injury is that during reaming and/or during the insertion of the nail a straight guide wire has been used. This is more likely when the wire gets



**Fig. 2.** — Arthrogram of the ankle joint a year after injury showing the talar body and the calcaneus fractures (sagittal and coronal images). Notice that the ankle is in plantarflexion, imagine position of the ankle during surgery (the fractures line up with extreme dorsiflexion of ankle).



**Fig. 3.** — Showing the straight and bent knobbed guide wires

jammed in the nail and is forced through the ankle joint during hammering of the nail down. The surgeon obviously did not notice this, as it is not a routine practice to use the xray screen during nail insertion. This could have been avoided if the surgeon had checked that the passage of the guide wire was smooth through the nail prior to the insertion of the nail.

The current reported complication caused ankle and subtalar stiffness. In an effort to minimize the

risk of inadvertent penetration of the tibial nail guide wires into the ankle joint, we emphasise the need for meticulous attention to details during intramedullary nailing. The free passage of the guide wires through the reamers and nails has to be tested before reaming or insertion of a tibial nail. A reamer with a blocked lumen has to be identified and exchanged to a patent one. Force during reaming or insertion of tibial nail needs to be avoided. There has to be a low threshold for using C-arm

biplane fluoroscopy when passing a guide wire or a reamer into the distal tibia. This point has been emphasized in previous reports (1-6).

Technical complications during tibial nailing need to be well documented in the file in order to plan future management of the patient.

## REFERENCES

1. Dencker H. Errors in technique and complications specific to intramedullary nailing. *Acta Orthop. Scand.*, 1964, 35, 164-169.
2. Dickson J. W. False aneurysm after intramedullary nailing of the femur. *J. Bone Joint Surg.*, 1968, 50-B, 144-145.
3. Gustilo R. B., Anderson J. T. Prevention of infection in the treatment of one thousand and twenty-five open fractures of long bones. Retrospective and prospective analyses. *J. Bone Joint Surg.*, 1976, 58-A, 453-458.
4. Johnson D. L., Wiss D. A. Intra-articular penetration of the knee joint by a fragment of cortical bone during intramedullary nailing of the femur. A report of two cases. *J. Bone Joint Surg.*, 1996, 78-A, 1092-1095.
5. Palmer I. Review of the complications and technical problems of intramedullary nailing. *J. Bone Joint Surg.*, 1950, 32-B, 721-729.
6. Watson-Jones R. Medullary nailing of fractures after fifty years. With a review of the difficulties and complications of the operation. *J. Bone Joint Surg.*, 1950, 32-B, 694-698.

## SAMENVATTING

A. A. FARAJ, V. G. JOHNSON. *Jatrogene letsels van de achtervoet door penetratie van geleidingspin bij intramedullaire tibianageling.*

Technische tegenslagen zijn bij intramedullaire nageling niet zeldzaam.

De schrijvers verhalen een geval waarbij de geleidingspin door het tibio-talair gewricht, de talus, het talo-calcaneair gewricht tot in het hielbeen was doorgedrongen tijdens het inkloppen van de nagel, met de enkel in acute dorsiflexie. Een dergelijk probleem werd nog niet gerapporteerd. Aanslepende enkelpijn en verstijving waren de klinische verschijnselen. De aangebrachte letsels wer-

den in het licht gesteld met computer tomografie. Onze raad is frekwente scopiecontroles tijdens de insertie van de geleidingspin, het uitboren van het kanaal en het inbrengen van de nagel in een tibia of een ander schaftbeen. Doordrukken met kracht moet worden vermeden, bij elk van deze stappen van de ingreep. Zeker moet vermeden worden kracht te gebruiken en verder uit te boren op de rechte pin. Voorzichtigheid is geboden bij het inslaan van de nagel over de rechte pin. Peroperatief moet zekerheid worden verkregen over een eventuele jatrogene penetratie van de enkel en de voet, zodat patient kan worden op de hoogte gebracht en de verdere behandeling kan worden aangepast.

## RÉSUMÉ

A. A. FARAJ, V. G. JOHNSON. *Lésion par pénétration de l'arrière-pied au cours de l'enclouage d'une fracture du tibia : présentation d'un cas.*

Les erreurs techniques ne sont pas rares au cours d'un enclouage médullaire. Les auteurs rapportent un cas où le guide d'enclouage a traversé la surface articulaire du tibia distal et a pénétré dans l'astragale et le calcaneum au cours de l'introduction du clou sur la cheville en dorsi-flexion. Cette complication n'avait pas été rapportée jusqu'à ce jour. Le diagnostic a été posé grâce au CT scan. Cette complication s'est traduite par une douleur persistance de la cheville, qui a fini par céder.

Les auteurs conseillent un contrôle radioscopique fréquent dans les deux plans au cours de l'insertion du guide, des alésoirs et du clou dans la cavité médullaire du tibia ou d'autres os longs. Aucun de ces instruments ne devrait être introduit en force. Lorsqu'on remplace le guide boutonné par un guide simple, celui-ci ne doit pas être passé en force, il ne doit pas être utilisé pour un alésage, et l'introduction du clou sur le guide doit se faire avec précaution.

Lorsqu'une telle complication se produit, il faut la reconnaître et il faut en tenir compte pour éventuellement modifier le traitement ultérieur et en informer le patient.