

SECONDARY FOREARM DEFORMITY DUE TO INJURY TO THE DISTAL ULNAR PHYSIS

F. COLLADO-TORRES, P. ZAMORA-NAVAS, F. DE LA TORRE-SOLIS

We present a case of deformity of the forearm with painful functional limitation, after a fracture of the distal third of the radius associated with a nonapparent lesion of the distal physis of the ulna, Salter-Harris type V, suffered by a patient 6 years earlier. This fracture caused premature growth arrest in the bone. It was treated with a plane-oblique corrective osteotomy in the radius together with distal radio-ulnar arthrodesis, following the Sauvé-Kapandji technique, with excellent cosmetic and functional results.

Keywords : forearm ; deformity ; premature growth arrest.

Mots-clés : déformation ; avant-bras ; arrêt prématuré de la croissance.

INTRODUCTION

The growth plate in the growing skeleton is especially vulnerable to trauma. Between 6 and 15% of all fractures of the long bones in children affect this region. Among them, those that damage the physis of the distal end of the radius are frequent, while those that damage the ulnar growth cartilage at that level are rare. The most usual ones pertain to the benign types of Salter and Harris (4), and the corrective capacity of the subsequent growth makes residual disabling deformities exceptional. When such a problem appears before growth is completed, it is not always easy to solve, and recurrences after treatment are frequent. For this reason, the recommended procedure is to postpone direct intervention on the deformity until the growth process has finished (1, 3).

CASE REPORT

A 16-year-old girl sought treatment because of deformity and painful functional limitation of her right forearm and wrist which had been developing over many years. She reported that 6 years earlier she had undergone trauma to the wrist as a result of a fall ; a torus (incomplete) fracture at the distal metaphyseal zone of the radius had been diagnosed, and she had been treated by immobilization in a short arm cast for 3 weeks. From then on she perceived progressive deformity and functional loss that prevented her from performing certain activities in her daily life, such as typing.

Clinical examination showed a varus deformity of the right forearm, which was shorter than the contralateral one, and there was a loss of the last 60° of pronation, complete supination and normal flexion-extension of the wrist. The roentgenographic study showed bowing of the radial diaphysis of 149° (170° on the healthy side), ulnar inclination of the radial epiphysis and ulnar displacement of the carpus, with shortening of the ulna and an increased carpal angle (fig. 1). The shortening of the ulna was 1.8 cm., with a radial angle of 43° versus 32° on the left side. The patient had reached full growth, so to eliminate the deformity, to increase the range of motion, to eliminate the pain and to maintain stability and force in her wrist, a plane-oblique osteotomy was performed

Department of Orthopedic Surgery, Hospital General Básico de la Axarquía, Finca El Tomillar s/n, 29700 Vélez-Málaga (Málaga), Spain.

Correspondence and reprints : F. Collado-Torres.

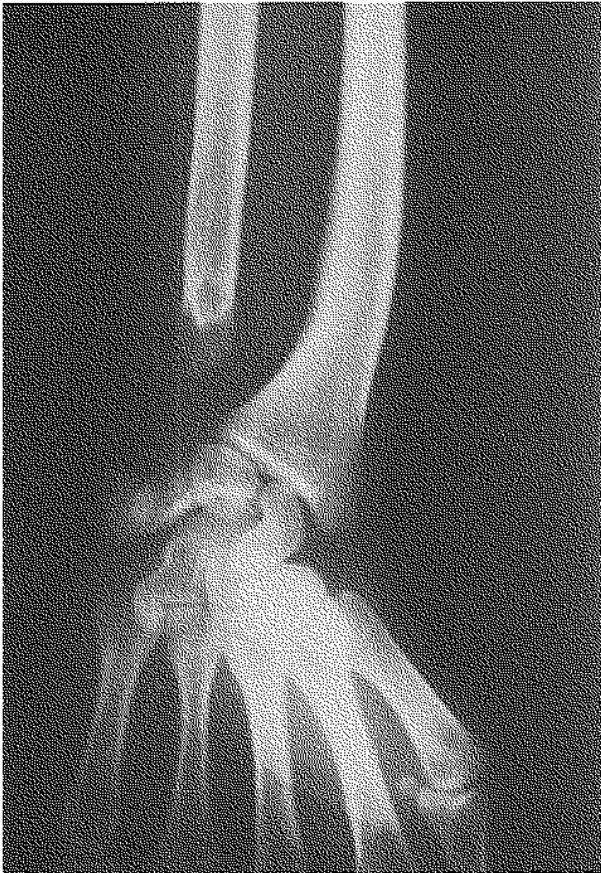

Fig. 1. — Established deformity.

at the site of maximum bowing of the radial diaphysis ; it was internally fixed using an AO-ASIF plate. At the level of the distal radio-ulnar joint, a stabilization procedure was carried out by arthrodesis of the joint, following the Sauvé-Kapandji technique (5). Surgical treatment was followed by immediate pain relief, improvement of the mobility arc, with full pronation and 10° of deficit in supination, as well as the resumption of the patient's regular activities. One year later, xrays showed that fusion of the distal radioulnar joint was not achieved (fig. 2) ; the deformity was however corrected to a large extent and the useful arc was painless and very acceptable to the patient.

DISCUSSION

The distal physis of the radius is the most frequent site of injury to growth cartilage in children,

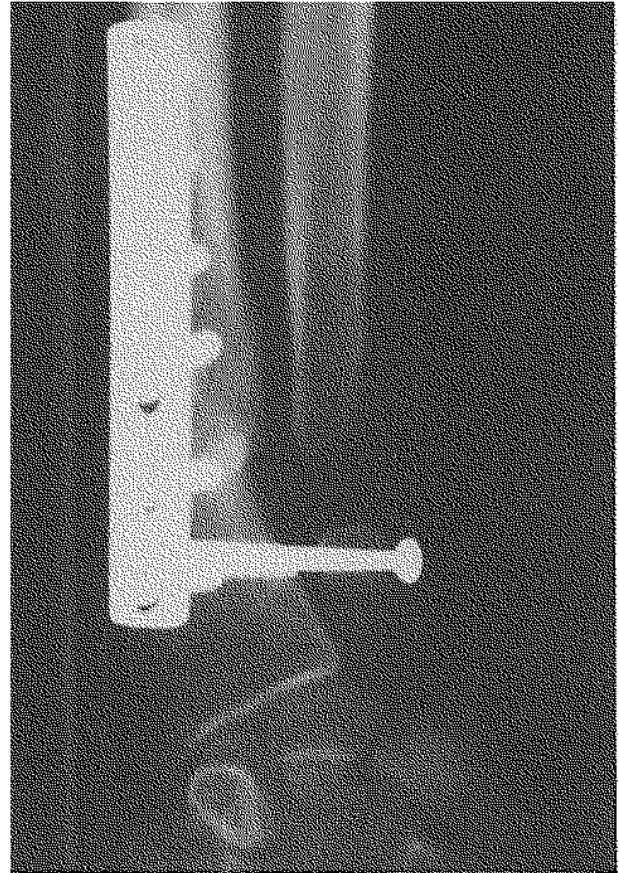


Fig. 2. — One year later. The osteotomy of the radius has healed, but fusion of the radio-ulnar arthrodesis has not been achieved. The radiocarpal index has improved.

but this rarely results in growth arrest at that level. On the other hand, the infrequent lesion of the growth cartilage at this level in the ulna has serious repercussions (1).

The roentgenographic appearance after trauma to the distal forearm physis is not the best indication of the severity of the underlying lesion at that level. In our case, there was an incomplete fracture of the radius indicating that the force that was received by the bone was exhausted before it was broken completely. The mechanism is axial trauma that works through compression. In the distal forearm, forces are transmitted mainly from carpus to radius with minimal ulnar participation. For this reason isolated ulnar fractures without an important injury present in the radius are rare at this level. That is the reason why our case is

so unusual (3). Cases of secondary forearm deformity after epiphysiolysis of the distal radius have been described (1).

The mechanism of the lesion of the radius makes us assume that the lesion in the ulnar physis corresponds to a Salter-Harris type V (4), a lesion with a poor prognosis. Authors who report important series of the distal forearm report even 50% of type I cases for the lesion of the ulna (2). The fracture of the radius did not require any manipulation directed toward reduction; therefore the cause of the damage to the ulnar physis did not result from the treatment. The roentgenographic appearance of the deformity has characteristics basically similar to those already described (2, 3).

The surgical indication for this kind of lesion is justified by the necessity of gaining mobility and/or eliminating pain, as well as for cosmetic reasons (1), although many patients may not present symptoms (2). For its correction we have acted on the deformed osseous segment. In such cases in which growth is already finished, a lateral closing wedge osteotomy in the radius (3) and/or an ulnar lengthening to maintain the distal radio-ulnar function is recommended; if the shortening is significant, a lengthening apparatus must be used. Although the latter procedure may lead to the correction of the deformity, it may also limit the final mobility. Other authors performed multiple osteotomies and, in deformities with a similar aspect, an osteotomy in the radius with progressive correction. We have utilized the plane-oblique osteotomy on the radius. This technique allows the correction of the deformity by placing the forearm in the required function arc without provoking shortening of the osteotomized segment. Besides, by fixing the distal radio-ulnar joint, the ulnar support is restored to the carpus so that recurrence of the deviation is avoided, providing excellent grip strength and keeping the normal morphology of the wrist (5). In the xray study, performed at the end of the first year after surgical correction, we could not verify fusion of the arthrodesis, but the majority of the preoperative alterations were improved, and the patient was very satisfied.

REFERENCES

1. Dicke T. E., Nunley J. A. Distal forearm fractures in children. Complications and surgical indications. *Orthop. Clin. North Am.*, 1993, 24, 333-340.
2. Golz R. J., Grogan D. P., Greene T. L., Belsole R. J., Ogden J. A. Distal ulnar physal injury. *J. Pediatr. Orthop.*, 1991, 11, 318-326.
3. Nelson C. A., Buchanan J. R., Harrison C. S. Distal ulnar growth arrest. *J. Hand Surg.*, 1994, 9-1, 164-171.
4. Salter R. B., Harris W. R. Injuries involving the epiphyseal plate. *J. Bone Joint Surg.*, 1963, 45-A, 587-622.
5. Taleisnik J. The Sauvé-Kapandji procedure. *Clin. Orthop.*, 1992, 275, 110-123.

SAMENVATTING

F. COLLADO-TORRES, P. ZAMORA-NAVAS, F. DE LA TORRE-SOLIS. Secundaire voorarmmisvorming na letsel van de distale ulnaire groeischijf.

De auteurs rapporteren een geval van misvorming van de voorarm met pijnlijke functiebeperking na fractuur van het distale 1/3 van de radius met niet apparent letsel van de distale ulnaire groeischijf type Salter-Harris V, 6 jaar na het trauma. De fractuur veroorzaakte een groeistop in de ulna. Behandeling met een schuine plane osteotomie van de radius met distale radio-ulnaire arthrodesis, volgens Sauvé-Kapandji. Uitztekend esthetisch en functioneel resultaat.

RÉSUMÉ

F. COLLADO-TORRES, P. ZAMORA-NAVAS, F. DE LA TORRE-SOLIS. Déformation secondaire de l'avant-bras suite à une lésion du cartilage de croissance distal du cubitus.

Les auteurs présentent un cas de déformation de l'avant-bras avec limitation fonctionnelle douloureuse après fracture du tiers inférieur du radius associée à une lésion non apparente du cartilage de croissance distal du cubitus, type Salter-Harris V, six ans après le traumatisme initial. Cette fracture provoqua un arrêt de croissance prématuré du cubitus. Traitement par ostéotomie plane oblique du radius associée à une arthrodesis radio-cubitale inférieure, selon la technique de Sauvé-Kapandji; excellent résultat esthétique et fonctionnel.