

INCIDENCE OF INTRAOPERATIVE FEMORAL FRACTURE STRAIGHT-STEMMED VERSUS ANATOMIC CEMENTLESS TOTAL HIP ARTHROPLASTY

A. TONI¹, D. CIARONI¹, A. SUDANESE¹, F. FEMINO², M. D. MARRARO³,
A. L. BUENO LOZANO¹, A. GIUNTI¹

The authors report the incidence of intraoperative femoral fractures (16 cases) occurring during the course of 395 cementless total hip arthroplasties performed at the Rizzoli Orthopaedic Institute between November, 1980 and June, 1991. The straight stem (Lord prosthesis) caused an intraoperative fracture in 18% of the cases, whereas the anatomic stem (An.C.A.) caused a fracture in only 1.5% of the cases. An intraoperative fracture occurred in 13% of patients with osteoporosis and only in 1.4% of those with normal mineralization of the proximal femur. Seven cases required circlage wiring; one was treated with interfragmentary screws (in the diaphysis).

The remaining patients were treated with casting or delayed weight-bearing. Fifteen fractures consolidated within an average of 10 weeks. One case treated with circlage wiring and screws resulted in a nonunion. After 7 months, internal fixation with a plate and screws was performed with consolidation 5 months later. All stems were radiographically stable at an average follow-up of 40 months.

Keywords : femoral fracture ; total hip arthroplasty ; prosthetic design ; cementless fixation ; internal fixation.

Mots-clés : fémur fracture ; arthroplastie totale de hanche ; forme de prothèse ; fixation sans ciment ; ostéosynthèse.

INTRODUCTION

Intraoperative fractures of the femur during insertion of total hip prostheses are caused by mechanical stresses arising during the procedure. They may be favored by general predisposing

factors, local variations in bone quality or a preexisting alteration in the femoral anatomy.

Such fractures generally involve the proximal third of the femur and rarely the middle or distal third. They may be associated with fractures of the greater trochanter, which may also occur as isolated fractures (8, 17).

When using a cementless hip prosthesis it is necessary to achieve optimal primary implant stabilization by means of the insertion pressure against the walls of the femoral canal; this requirement is critical when using a cementless prosthesis and is correlated with a greater risk of intraoperative femoral fractures (1-3, 6, 9-11, 13, 14, 19-22, 24-26, 29).

The scope of this work is to elucidate the incidence of these complications in our experience of cementless total hip arthroplasties; to evaluate the importance of factors relating to the type of prosthesis inserted, surgical technique used and local predisposing conditions; and finally, to analyze the type of treatment best suited to such complications.

MATERIALS AND METHODS

We evaluated all patients who underwent cementless total hip arthroplasties within our division from No-

¹ Rizzoli Orthopaedic Institute, Bologna, Italy.

² Resident, Orthopaedic Surgery, University of Medicine and Dentistry of New Jersey, Newark, New Jersey, U.S.A.

³ Technology of Materials Laboratory, Codivilla-Putti Institute of Research, Bologna, Italy.

Correspondence and reprints : A. Toni.

INCIDENCE OF INTRAOPERATIVE FEMORAL FRACTURE STRAIGHT-STEMMED VERSUS ANATOMIC CEMENTLESS TOTAL HIP ARTHROPLASTY

A. TONI¹, D. CIARONI¹, A. SUDANESE¹, F. FEMINO², M. D. MARRARO³,
A. L. BUENO LOZANO¹, A. GIUNTI¹

The authors report the incidence of intraoperative femoral fractures (16 cases) occurring during the course of 395 cementless total hip arthroplasties performed at the Rizzoli Orthopaedic Institute between November, 1980 and June, 1991. The straight stem (Lord prosthesis) caused an intraoperative fracture in 18% of the cases, whereas the anatomic stem (An.C.A.) caused a fracture in only 1.5% of the cases. An intraoperative fracture occurred in 13% of patients with osteoporosis and only in 1.4% of those with normal mineralization of the proximal femur. Seven cases required circlage wiring; one was treated with interfragmentary screws (in the diaphysis).

The remaining patients were treated with casting or delayed weight-bearing. Fifteen fractures consolidated within an average of 10 weeks. One case treated with circlage wiring and screws resulted in a nonunion. After 7 months, internal fixation with a plate and screws was performed with consolidation 5 months later. All stems were radiographically stable at an average follow-up of 40 months.

Keywords : femoral fracture ; total hip arthroplasty ; prosthetic design ; cementless fixation ; internal fixation.

Mots-clés : fémur fracture ; arthroplastie totale de hanche ; forme de prothèse ; fixation sans ciment ; ostéosynthèse.

INTRODUCTION

Intraoperative fractures of the femur during insertion of total hip prostheses are caused by mechanical stresses arising during the procedure. They may be favored by general predisposing

factors, local variations in bone quality or a preexisting alteration in the femoral anatomy.

Such fractures generally involve the proximal third of the femur and rarely the middle or distal third. They may be associated with fractures of the greater trochanter, which may also occur as isolated fractures (8, 17).

When using a cementless hip prosthesis it is necessary to achieve optimal primary implant stabilization by means of the insertion pressure against the walls of the femoral canal; this requirement is critical when using a cementless prosthesis and is correlated with a greater risk of intraoperative femoral fractures (1-3, 6, 9-11, 13, 14, 19-22, 24-26, 29).

The scope of this work is to elucidate the incidence of these complications in our experience of cementless total hip arthroplasties; to evaluate the importance of factors relating to the type of prosthesis inserted, surgical technique used and local predisposing conditions; and finally, to analyze the type of treatment best suited to such complications.

MATERIALS AND METHODS

We evaluated all patients who underwent cementless total hip arthroplasties within our division from No-

¹ Rizzoli Orthopaedic Institute, Bologna, Italy.

² Resident, Orthopaedic Surgery, University of Medicine and Dentistry of New Jersey, Newark, New Jersey, U.S.A.

³ Technology of Materials Laboratory, Codivilla-Putti Institute of Research, Bologna, Italy.

Correspondence and reprints : A. Toni.

Table I. — Description of cases with intraoperative femoral fractures

Case	Sex/ Age	Indication	Type of prosthesis	Type of fracture	Treatment	Fracture consolid. (months)	Complication	Treatment of complication	Follow-up (months)	Acetabular stability	Stem stability
1	F/51	CHD	AnCa, short	Meta	DWB	2	—		30	O	O
2	F/48	OA	AnCA, std	Meta	C	3	—		6	O	O
3	F/64	PN	AnCA, std	Meta	DWB	3	—		50	FB	O
4	F/59	OA	AnCA, short	Dia	DWB	5	Deep Venous Thrombosis		31	O	O
5	F/46	CHD	AnCa, short	Meta	P (30 days)	2 1/2	—		6	O	O
6	F/54	CHD	LORD	Meta	P (35 days)	1 1/2	—		68	FB	O
7	F/61	AN	LORD	Meta	C + P (40 days)	2	—		12	O	O
8	M/57	OA	LORD	Dia	C + screws	—	No consolidation after 7 months	Internal fixation (plate and screws)	51	O	O
9	F/55	AN	LORD	Meta	P (21 days)	1	—		125	O	O
10	F/56	FNF	LORD	Meta	P (30 days)	1 1/2	—		36	O	O
11	F/51	CHD	LORD	Troch	C + P (40 days)	2	—		64	U	O
12	F/59	OA	LORD	Troch	C + P (40 days)	2 1/2	—		75	O	O
13	F/63	OA	LORD	Troch	C + P (40 days)	1 1/2	—		10	O	O
14	M/61	OA	LORD	Troch	C + P (45 days)	2	—		51	O	O
15	M/61	OA	LORD	Troch	C	5	—		66	O	O
16	F/57	AN	LORD	Troch	P (40 days)	3	—		48	O	O

CHD = Congenital hip dysplasia ; OA = Osteoarthritis ; PN = Posttraumatic necrosis ; AN = Aseptic necrosis ; FNF = Femoral neck fracture ; Meta = Meta-physal ; Dia = Diaphyseal ; Troch = Trochanteric ; DWB = Delayed weight-bearing ; C = Circlage wiring ; P = Plaster cast ; M = Male ; F = Female ; O = Osseous ; FB = Fibrous ; U = Unstable.

Fractures never occurred during the initial maneuvers to dislocate the hip or during the final maneuvers to reduce the prosthesis. The fractures always occurred during rasping of the diaphyseal canal or during insertion of the stem of the prosthesis. In 11 cases the straight-stemmed prosthesis was used (out of 61, giving a fracture rate of 18%) and in 5 cases the anatomic prosthesis (out of 334, giving a fracture rate of 1.5%). Therefore, the incidence of intraoperative fractures was definitely lower when using the prosthesis with an anatomic stem than when using the Lord straight-stemmed prosthesis, which also required the 90° metaphyseal osteotomy. In reference to stem length of the An.C.A. prosthesis, 2% (2/111) occurred with the standard length stem and 1.3% (3/223) with the short stem.

The incidence of fractures as related to the indications for total hip arthroplasty are described in table II. Bone mineralization, evaluated according to the method of Engh and Bobyn, was subdivided into four categories, and it was found that fractures occurred in 10.3% of the cases with severe osteoporosis (≤ 3 points), in 14% of the cases with moderate osteoporosis (4 points), in 2% of the cases with slight osteoporosis (5-6 points) and no fractures in cases without osteoporosis (≥ 7 points) (fig. 1). Regrouping the patients into two groups: ≤ 4 points and ≥ 5 points, we observed an incidence of fractures of 13% for cases with evident osteoporosis compared to only 1.4% for cases without evident osteoporosis.

Table II. — Incidence of fractures in relation to preoperative pathology

Etiology	Number of fractures over total	Incidence of fractures %
Osteoarthritis in C.H.D.	4/58	7%
Primary osteoarthritis	8/245	3.3%
Femoral neck fractures	1/13	7.7%
Aseptic necrosis	2/25	8%
Post-traumatic necrosis	1/11	9%
Ankylosing spondylitis	0/10	—
Rheumatoid arthritis	0/7	—
Post-traumatic arthritis	0/13	—
Other	0/13	—

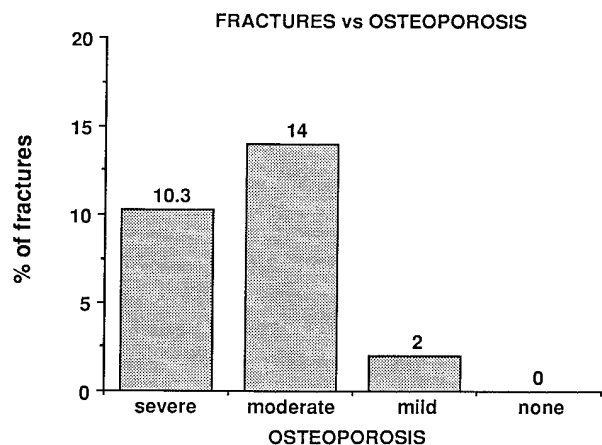


Fig. 1. — Incidence of fractures in relation to the grade of femoral bone mineralization at the time of surgery.

Table III describes in detail the fractures which occurred; two patients sustained a *femoral diaphyseal fracture*. In case # 8 of table I, a comminuted fracture occurred during the implantation of a straight-stemmed prosthesis. We performed an osteosynthesis using interfragmentary screws and circlage wiring. In case # 4 the stability of the implant was verified on the operating table, and the patient was treated with delayed weight-bearing for 60 days (fig. 4).

Eight patients sustained *metaphyseal fractures*. Two cases (# 2, # 7) were treated with circlage wiring and a long-leg spica cast (one anatomic and one straight prosthesis) (fig. 5); four cases with immobilization in a spica cast for an average of 26 days (one anatomic stem: case # 5 and three straight-stemmed prostheses: cases # 6, 9, 10); the remaining two cases (anatomic stem prostheses: cases # 1, 3) were verified on the operating table to have stable implants and were treated with delayed weight-bearing for an average of 50 days (fig. 6).

The 6 cases of *fracture of the greater trochanter* always occurred during implantation of the straight-stemmed Lord prosthesis. Five cases (# 11, 13, 13, 14, 15) were treated with circlage wiring and spica casts; one case (# 16) was treated only with immobilization in plaster for 40 days.

Fifteen of the sixteen cases showed consolidation of the fracture in an average of 10 weeks (minimum 2, maximum 20 weeks); in the case with

Table III. — Type of treatment of fractures

Type of prosthesis	Surgery	Type of fracture		
		diaphyseal	metaphyseal	trochanteric
LORD	Circlage Wiring and/or Screws	1	1*	5*
	Casting	—	3	1
	Delayed Weight-Bearing	—	—	—
	TOTAL	1	4	6
An.C.A.	Circlage Wiring and/or Screws	—	1*	—
	Casting	—	1	—
	Delayed Weight-Bearing	1	2	—
	TOTAL	1	4	—

* casting used.

a diaphyseal comminuted fracture (# 8), treated for the first time with screw fixation, it was necessary to reoperate 7 months later for delayed consolidation and to perform rigid internal fixation with an A.O. plate, resulting in consolidation after another 5 months (fig. 7).

In 8 cases the treatment of the fractures consisted of casting (5 cases) for a mean period of 31 days or of delayed weight-bearing (3 cases). In the remaining 8 cases we proceeded with internal fixation during the initial surgery ; in 7 cases we used circlage wiring and in the final case we used circlage wiring and screws.

The choice of treatment was related to the site of fracture : in the majority of metaphyseal fractures we preferred not to carry out internal fixation (6 cases out of 8), in only 2 cases we proceeded with circlage wiring. In the 6 trochanteric fractures, on the contrary, internal fixation with circlage wiring was the treatment of choice (5 treated operatively versus one treated nonoperatively). The diaphyseal fractures which did not involve the tip of the prosthesis were treated nonoperatively (fig. 4), while the one which involved the tip of the prosthesis, which was extensive and compromised stability, was treated with circlage wiring and screws.

The clinical data are reported in fig. 2a, 2b, and 2c. After an average follow-up of 40 months, pain was absent in 94% of the cases (fig. 2a), walking was optimal or with a slight limp without a cane in 94% of the cases (fig. 2b), while range of motion was felt to be normal or minimally limited in 69% of the cases (fig. 2c). Analysis of the differences in clinical results according to the type of prosthesis used could not be evaluated statistically due to the small sample size.

Such clinical results are not dissimilar to those of our previous study of patients who underwent cementless total hip arthroplasties (30).

All the cases complicated by an intraoperative fracture showed osseous stabilization of the stem at an average follow-up of 46 months. Two cases (one An.C.A. : # 3, one Lord : # 6) presented with fibrous stabilization of the acetabular component with the presence of a "halo" (radiolucent line delimiting a sclerotic border at the bone-prosthesis interface) at a follow-up of 50 and 68 months, respectively. In a third case (Lord : # 11) the acetabular component appeared unstable because of the presence of a continuous radiolucency at the bone-prosthesis interface at a follow-up of 64 months. The remaining 13 cases showed osseous stabilization of the acetabular component.

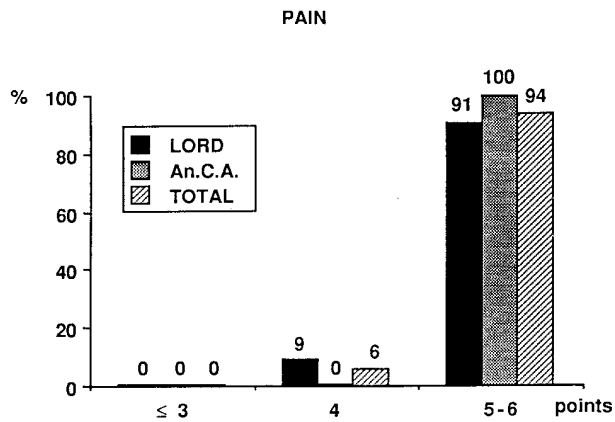


Fig. 2a

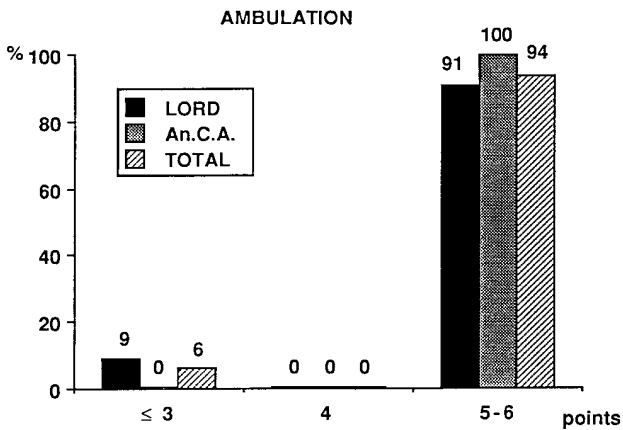


Fig. 2b

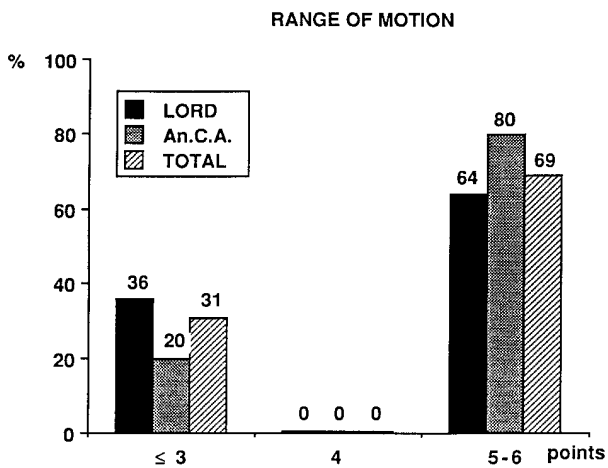


Fig. 2c

Fig. 2. — Results of the postoperative clinical evaluation using the methods of Merle d'Aubigné. Study of three parameters : pain (a), ambulation (b), and range of motion (c).

When the incidence of intraoperative fractures is divided into 2-year intervals (fig. 3a) it can be seen that the cases with the straight-stemmed prosthesis have a higher and steady incidence as compared to cases with the anatomic stem prosthesis, which have a lower and decreasing incidence over time (fig. 3b).

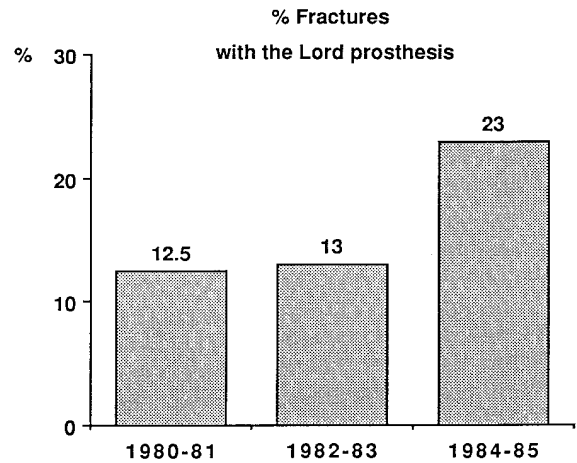


Fig. 3a

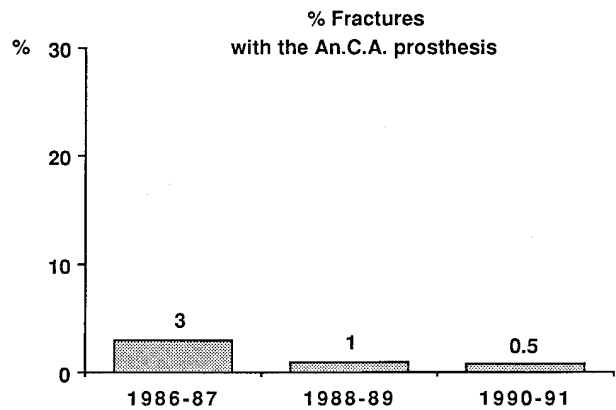


Fig. 3b

Fig. 3. — Percent of intraoperative fractures with the Lord prosthesis (a) and An.C.A. prosthesis (b), subdivided into biennial periods.

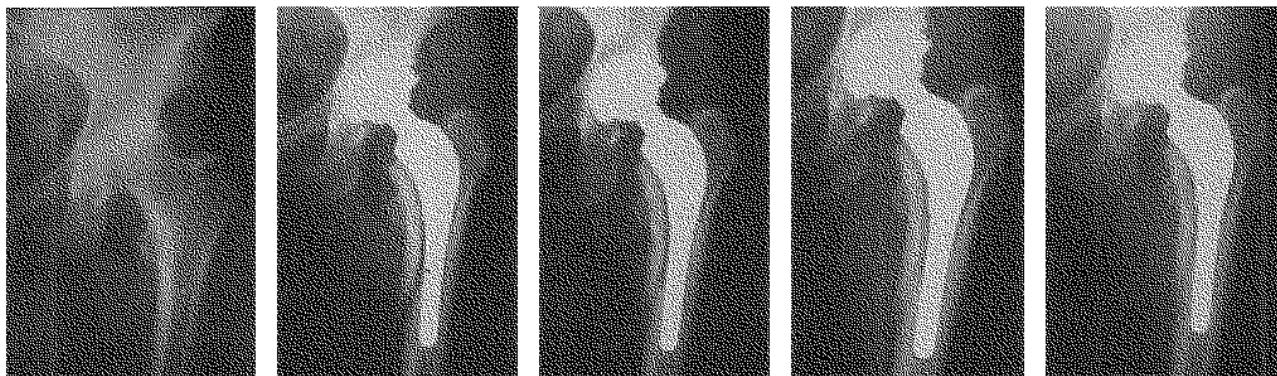


Fig. 4a

Fig. 4b

Fig. 4c

Fig. 4d

Fig. 4e

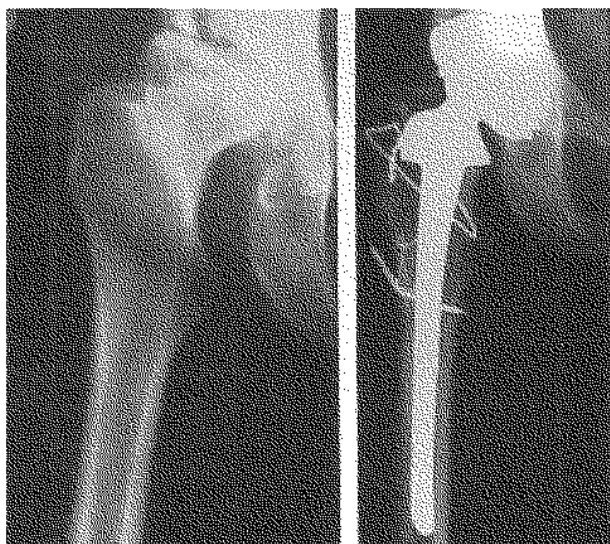

Fig. 5a

Fig. 5b

Fig. 5. — Case # 7 :

- a) Aseptic necrosis of the hip.
- b) Follow-up 2 months after circlage wiring and casting for 40 days for a metaphyseal fracture.

DISCUSSION

This study reveals an overall incidence of intraoperative fractures during implantation of cementless prostheses of 4%, which agrees with the reports of other authors (2, 3, 9, 11-14, 21-24, 26, 30) and is correlated with the necessity to insert such prosthesis tightly in the femoral canal to obtain sufficient primary stability.

In agreement with other authors (9, 11, 14, 16, 21, 23, 26) we can confirm from this study that

Fig. 4. — Case # 4 :

- a) Osteoarthritis of the hip.
- b) Medial metaphyseal fracture with no effect on the stability of the prosthesis.
- c) X ray 4 months after surgery : initial fracture callus.
- d) X ray at 11 months shows complete fracture repair.
- e) The prosthesis is stable 36 months after surgery.

the incidence of intraoperative fractures is related to the type of prosthesis and the surgical technique. In relation to the type of prosthesis used, the incidence of fracture is particularly elevated when using the straight-stemmed Lord prosthesis (18%) with respect to the anatomic stem prosthesis (1.5%), in which the stem is anatomically shaped and adapts better to the contours of the femur. The stem length appears to have minor relevance since there is a slightly lower incidence for those anatomic stem prostheses with a shorter stem (1.5% vs 2%). Different geometric configurations of the prosthesis caused different types of fractures. In fact, the trochanteric fractures occurred only with the Lord prosthesis which required a 90° intertrochanteric osteotomy in order to insert the stem. The impossibility to obviate this unfavorable tendency by modification of the surgical technique, even after much experience, is supported by the fact that the incidence of intraoperative fractures with this prosthesis, considered by year of implant, shows a uniform distribution. For the anatomic prosthesis it is possible, on the contrary, to demonstrate a decreasing incidence over time, supporting the belief that refinements

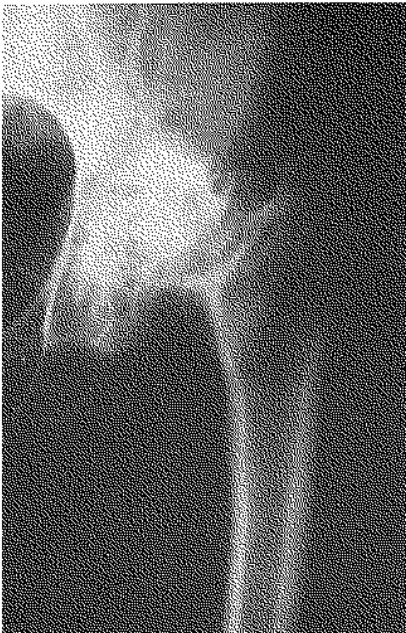

Fig. 6a

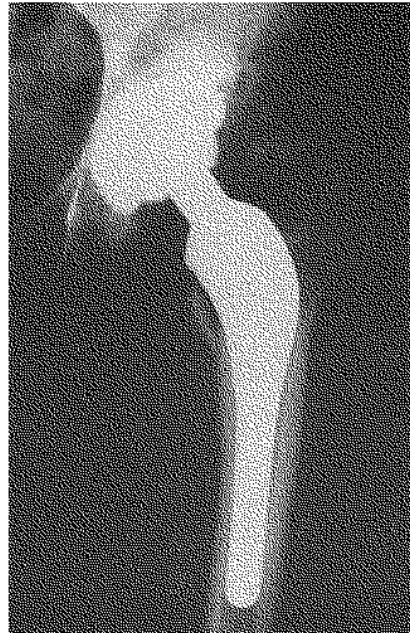

Fig. 6b

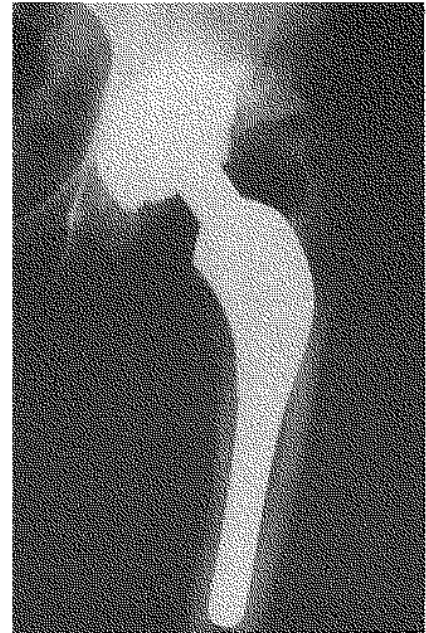

Fig. 6c

Fig. 6. — Case # 1 :

- a) Preoperative x ray of left hip affected by congenital dysplasia.
- b) Spiral fracture near the lesser trochanter.
- c) X ray at 21 months shows complete fracture repair.

in surgical technique can lead to an optimal “press-fit” with minimal risk of intraoperative fracture.

Intraoperative fractures can occur beginning with the dislocation of the hip joint, throughout the phase of preparation of the femoral canal, and during final reduction of the implanted prosthetic articulation (1, 2, 4, 12, 18, 25). In our cases all fractures occurred during rasping of the femoral canal or during insertion of the prosthesis.

Among the causes of this complication, other than improper surgical technique (8, 17), are various predisposing local factors. Important among these factors are: dysmorphism of the hip, anomalies spanning from the neck to the diaphysis of the femur, the effects of pertrochanteric fractures, femoral neck fractures, or existing osteotomies and, above all, the altered osseous structure caused by internal fixation with various hardware. This accounts for the elevated incidence (7.7%) of fractures in patients with hip dysplasia. Such alterations are possible to detect by a careful preoperative study of the x rays of the hip, made

in two orthogonal projections. By superimposing template transparencies of various types of prostheses on the x ray image of the hip, a good approximation of both the type and size of the prosthesis can be made for each particular femoral configuration. This, along with adequate preparation of the femoral canal with the appropriate rasp, will greatly diminish the risk of femoral fracture, as stated also by other authors (9, 11, 23).

It is necessary to pay particular attention to the preoperative state of bone mineralization of the proximal femur and, in particular, to cases with advanced osteoporosis. For us, 13% of the fractures occurred in cases with evident osteoporosis (evaluated according to the method of Engh and Bobyn) (7) and only 1.4% in cases without osteoporosis. The high incidence of intraoperative fractures during implantation of cementless stems in osteoporotic femurs constitutes another factor which should reinforce the contraindication for the use of these prostheses in such patients. With the aim of identifying cases with advanced osteo-

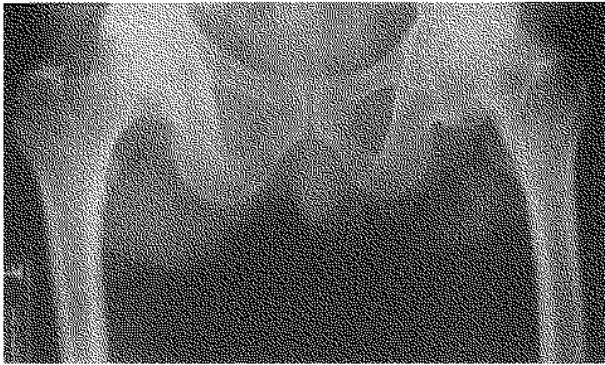


Fig. 7. — Case # 8 :
 a) Osteoarthritis of the hip.
 b) Diaphyseal fracture.
 c) Circlage wiring and interfragmentary screws.
 d) Fibrous union after 7 months.
 e) Follow-up 4 years after internal fixation with plate and screws ; consolidation.

Fig. 7a

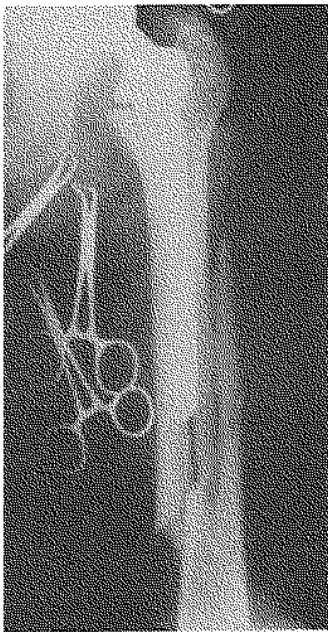


Fig. 7b

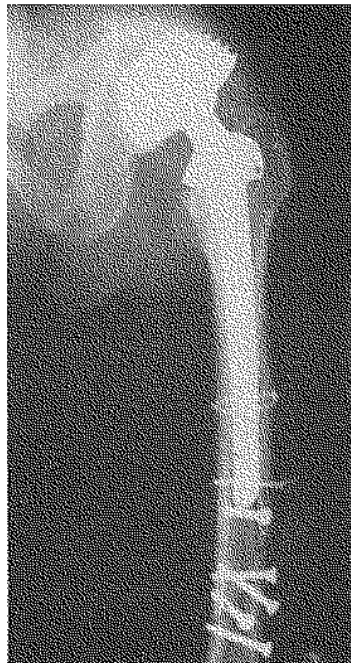

Fig. 7c




Fig. 7d

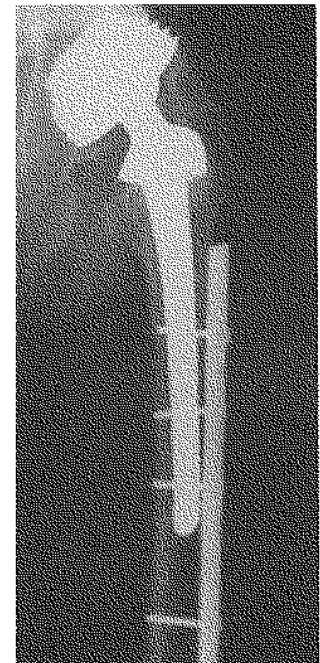


Fig. 7e

porosis and, thus, cases at higher risk for intraoperative fractures, it is useful to keep in mind the various types of pathology which frequently occur secondary to demineralization. For example, femoral neck fractures are almost always a result of osteoporosis. Osteoporosis of the femoral head can be the result of demineralization secondary to a diminished level of function of the hip and to limited weight-bearing, as in the case of a painful hip.

The intraoperative fracture obviously decreases primary stability of the stem but this does not necessarily cause definitive compromise of stability.

In fact, our experience shows that even minimal treatment (no internal fixation in 8 cases) may result in only delayed recovery of functional weight-bearing without aseptic loosening.

The treatment of intraoperative fractures has not been uniform since subtle differences make every fracture unique. Treatment is established each time according to the site of the fracture, its extent and the residual stability of the implanted prosthesis. In our cases we preferred to treat the metaphyseal fractures nonoperatively (6 out of 8) ; circlage wiring was used in only 2 cases. Most of the trochanteric fractures were treated with

internal fixation (5 out of 6 cases) because it is necessary to preserve the integrity of the abductor mechanism of the hip. A metaphyseal fracture, if sufficiently reduced, does not significantly compromise the stability of the prostheses.

The diaphyseal fractures deserve separate consideration. There were only two in our experience : the treatment was nonoperative in the case in which the fracture did not reach the tip of the prosthesis (fig. 4), while we proceeded with internal fixation with circlage wiring and screws in the case in which the fracture, which was extensive, involved the tip of the prosthesis, compromising its stability.

In this last case (fig. 7), among the first we performed, insufficient internal fixation was applied ; a plate or a longer prosthesis bridging the fracture site should have been employed.

None of the cases treated with internal fixation developed infection. The clinical results are comparable, on the basis of the type of prosthesis used, to those patients who did not experience intraoperative fractures.

In conclusion minimal fixation or simple immobilization with delayed weight-bearing is almost always sufficient to allow consolidation of the fracture, as is well shown in figs. 4 and 6, in which there is stability of the implant at 11 and 21 months, respectively.

In cases with diaphyseal fracture we must attempt to evaluate the residual implant stability : if it is not compromised, immobilization in a cast is sufficient to permit consolidation (fig. 4). In cases where the fracture causes instability, which can be shown with rotational maneuvers of the femur, the indication is internal fixation with either a plate and screws or with a long revision prosthesis (23-25 cm). Such a prosthesis would substitute for the implanted prosthesis and provide for stability of the stem and stabilization of the fracture simultaneously, obviating the need for internal fixation with a plate and screws.

CONCLUSION

Intraoperative femoral fractures almost always occurred during rasping of the diaphyseal canal or during insertion of the stem of the prosthesis.

We can confirm in this study that the incidence of intraoperative fractures is related to the type of prosthesis and the surgical technique. In relation to the type of prosthesis used, the incidence of fracture is particularly high when using the straight-stemmed Lord prosthesis as compared to the anatomic stem prosthesis, in which the stem is anatomically shaped and adapts better to the contours of the femur. The stem length appears to have minor relevance. Trochanteric fractures occurred only with use of the Lord prosthesis which required a 90° intertrochanteric osteotomy in order to insert the stem.

Among predisposing local factors were dysmorphism of the hip, anomalies spanning from the neck to the diaphysis of the femur, the effects of trochanteric fractures, femoral neck fractures, or previously existing osteotomies and the altered osseous structure caused by internal fixation with various hardware.

It is necessary to pay particular attention to the preoperative state of bone mineralization of the proximal femur and, in particular, to cases with advanced osteoporosis. The high incidence of intraoperative fractures during implantation of cementless stems in osteoporotic femurs constitutes another factor which should enforce the contraindication for the use of these prostheses in such patients.

REFERENCES

1. Ali Kahn M. A., O'Driscoll M. Fractures of the femur during total hip replacement and their management. *J. Bone Joint Surg.*, 1977, 59-B, 36-41.
2. Andrew T. A., Flanagan J. P., Gerundini M., Bombelli R. The isoelastic, noncemented total hip arthroplasty. Preliminary experience with 400 cases. *Clin. Orthop.*, 1986, 127-138.
3. Baldini N., Toni A., Greggi T., Sudanese A., Giunti A. Fratture intraoperatorie del femore nell'intervento di artroprotesi d'anca non cementata. *Chir. Organi Mov.*, 1986, 71, 337-341.
4. Barrington T. W., Johansson J. E., Mc Broom R. Fractures of the femur complicating total hip replacement. In R. S. Ling (ed.) : *Complications of total hip replacement*. Churchill Livingstone, Edinburgh, 1984, pp. 30-40.
5. Charnley J. The long-term results of low-friction arthroplasty of the hip performed as a primary intervention. *J. Bone Joint Surg.*, 1972, 54-B, 61-76.

6. Dolanc B. Local perioperative complications. In N. Gschwend and H. U. De Brenner (eds): Total hip prosthesis. Huber, Bern, 1976, pp. 66.
7. Engh C. A., Bobyn J. D. Biological fixation in total hip arthroplasty. Slack Inc., Thorofare, 1985.
8. Federici A., Carbone M., Sanguineti F. Fratture intraoperatorie della diafisi femorale negli interventi di artroprotesi d'anca. Giorn. Ital. Ortop. Traum., 1988, 14, 319-330.
9. Fitzgerald R. H., Brindley G. W., Kavanagh B. F. The uncemented total hip arthroplasty. Intraoperative femoral fractures. Clin. Orthop., 1988, 235, 61-66.
10. Griss P., Hackenbroch M., Jager M., Pressner B., Schafer R., Van Eimeern W. (eds): Findings on total hip replacement for ten years. Huber, Bern, 1982, pp. 39-40.
11. Jensen J. S., Repten J. B. Failures with the Judet non-cemented total hip. Acta Orthop. Scand., 1987, 58, 23-26.
12. Johansson J. E., Mc Broom R., Barrington T. W., Hunter G. A. Fractures of the ipsilateral femur in patients with total hip replacement. J. Bone Joint Surg., 1981, 63-A, 1435-1442.
13. Lord G., Bancel P. The madreporic cementless total hip arthroplasty. New experimental data and a seven-year clinical follow-up study. Clin. Orthop., 1983, 176, 67-76.
14. Lord G., Marotte J. H., Guillamon j. L., Blanchard J. P. Cementless revisions of failed aseptic cemented and cementless total hip arthroplasties. 284 cases. Clin. Orthop., 1988, 235, 67-74.
15. Lord G. A., Hardy J. R., Kummer F. J. An uncemented total hip replacement. Experimental study and review of 300 madreporic arthroplasties. Clin. Orthop., 1979, 41, 2-16.
16. Mallory T. H., Klaus T. J., Vaughn B. K. Intraoperative femoral fractures associated with cementless total hip arthroplasty. Orthopedics, 1989, 12, 213-239.
17. Moroni A., Ruggieri N. Le fratture intraoperatorie di femore in corso di protesizzazione d'anca. Clin. Org. Mov., 1980-1981, 66, 703-713.
18. Mueller L. E. Complication of total hip replacement. In N. Gschwend and H. U. De Brenner (eds): Total hip prosthesis. Huber, Bern, 1976, pp. 319.
19. Poss R., Ewald F. C., Thomas W. H., Sledge C. B. Complications of total hip replacement arthroplasty in patients with rheumatoid arthritis. J. Bone Joint Surg., 1976, 58-A, 1130-1133.
20. Ranieri L., Toni A., Olmi R., Moroni A., Graci A. Considerazioni sulle possibilità di miglioramento delle protesi d'anca: cemento composito con idrossiapatite, protesi non cementate a conformazione anatomica dello stelo. In Campanacci M., Dal Monte A., Gui L., Ranieri L., Ruggieri F. (eds): Attualità in chirurgia ortopedica. A. Gaggi, Bologna, 1982, pp. 441-448.
21. Reichelt A., Blasius K. First experience with the P.M. prosthesis. In E. Morscher (ed): The cementless fixation of hip endoprostheses. Springer, New York, 1984, pp. 181-183.
22. Rupp G. Experience with the Lord prosthesis. In E. Morscher (ed.): The cementless fixation of hip endoprostheses. Springer, New York, 1984, pp. 139-143.
23. Scholliner D., Elsner K. H. Early results of Judet total hip replacement arthroplasty. In E. Morscher (ed): The cementless fixation of hip endoprostheses. Springer, New York, 1984, pp. 146-149.
24. Schwartz J. T., Mayer J. G., Engh C. A. Femoral fracture during non-cemented total hip arthroplasty. J. Bone Joint Surg., 1989, 71-A, 1135-1142.
25. Scott R. D., Turner R. H., Leitzes S. M., Aufrank O. E. Femoral fractures in conjunction with total hip replacement. J. Bone Joint Surg., 1975, 57-A, 494-501.
26. Stampfel O., Pommer W., Trauner R., Santner V. 3 1/2 years' results of Lord primary total hip arthroplasties and 1 1/2 years' experience with revision arthroplasties for loose cemented prostheses. In E. Morscher (ed): The cementless fixation of hip endoprostheses. Springer, New York, 1984, pp. 265-274.
27. Taylor M. M., Meyers M. H., Harvey J. P. Intraoperative femur fractures during total hip replacements. Clin. Orthop., 1978, 137, 96-103.
28. Toni A., Baldini N., Greggi T., Sudanese A., Nigrisoli M., Dallari D., Giunti A. Valutazione radiografica delle artroprotesi d'anca non cementate. Chir. Org. Mov., 1987, 72, 7-15.
29. Toni A., Sudanese A., Ciaroni D., Dallari D., Greggi T., Giunti A. Anatomical ceramic arthroplasty (An.C.A.): preliminary experience with a new cementless prosthesis. Chir. Org. Mov., 1990, 75, 81-97.
30. Zweymuller K. First clinical experience with an uncemented modular femoral prosthesis system with a wrought Ti-6AL-4V stem and an Al₂O₃ ceramic head. In E. Morscher (ed): The cementless fixation of hip endoprostheses. Springer, New York, 1984, pp. 150-155.

SAMENVATTING

A. TONI, D. CIARONI, A. SUDANESE, F. FEMINO, M. D. MARRARO, A. L. BUENO LOZANO, A. GIUNTI. Peroperatoire femurfraktuur. Vergelijking van een cementloze prothese met rechte steel en van een anatomische totale heupprothese.

De auteurs rapporteren over de frekwentie van peroperatieve femurfracturen (16 gevallen) tijdens 395 cementloze totale heupprothesen, geplaatst in het Orthopedisch Instituut Rizzoli van november 1980 tot juni 1991. De rechte steel (prothese van Lord) gaf aanleiding tot peroperatieve fracturen in 18% van de gevallen; bij anatomische steel (A.C.A.) was er een fractuur bij 1,5% van de patiënten. Een peroperatieve fractuur gebeurde in 13% van de patiënten met osteoporose en slechts in 1,4% wanneer er een normale mineralisatie van het proximaal uiteinde van het femur aanwezig

was. Voor 7 gevallen gebeurde een metalen cerclage ; één patiënte werd behandeld met interfragmentaire schroeven. Bij de overige patiënten bestond de behandeling in gipsimmobilisatie of verlengd steunverbod. Vijftien fracturen consolideerden binnen de 10 weken. De gevallen, behandeld met cerclage en met schroeven, gaven aanleiding tot pseudarthrosen. Na 7 maanden gebeurde een fixatie met geschroefde plaat, gevolgd met consolidatie, 5 maanden later. Na 40 maanden waren al de stelen radiografisch stabiel.

RÉSUMÉ

A. TONI, D. CIARONI, A. SUDANESE, F. FEMINO, M. D. MARRARO, A. L. BUENO LOZANO, A. GIUNTI. Fracture peropératoire du fémur. Comparaison d'une prothèse à tige droite avec l'arthroplastie sans ciment.

Les auteurs analysent l'incidence des fractures peropératoires du fémur (16 cas) au cours de 395 arthroplasties

totales de hanche, non cimentées, pratiquées à l'Institut Orthopédique Rizzoli de novembre 1980 à juin 1991. La prothèse à tige droite (type Lord) est à l'origine de 18% de fractures opératoires alors que la prothèse anatomique (A.C.A.) n'a donné lieu à une fracture que dans 1,5% des cas. Une fracture peropératoire survint chez 13% des malades qui présentaient de l'ostéoporose et chez 1,4% des opérés avec une minéralisation normale de l'extrémité supérieure du fémur. Dans 7 cas on eut recours à un cerclage métallique. Un cas fut traité par un vissage interfragmentaire de la diaphyse.

Les autres malades furent traités par plâtre ou mise en charge différée. Quinze fractures ont consolidé endéans les 10 semaines.

Les fractures traitées par cerclage et vissage donnèrent lieu à une pseudarthrose. Après 7 mois, on eut recours à une fixation par plaque vissée, suivie d'une consolidation après 5 mois.

Toutes les tiges étaient radiographiquement stables, avec un recul de 40 mois.