

MENISCAL TRANSPLANTATION

R. VERDONK

The aims of a meniscal replacement are :

- 1) to reduce the pain experienced by some patients following meniscus resection ;
- 2) to prevent the degenerative changes of cartilage and the changes in subchondral bone following meniscus resection ;
- 3) to avoid or reduce the risk of osteoarthritis following meniscus resection ;
- 4) to restore optimally the mechanical properties of the knee joint after meniscal resection.

The results of meniscus transplantation have been studied in animals. There is no proof from these experiments that replacement of a meniscus can reduce the risk of arthritis, but there are indications that it can decrease the development of cartilage degeneration.

In humans, the results of meniscus transplantation have been reported in several series of patients, operated with different techniques. There are no controlled studies of meniscus replacement in humans.

In case of meniscal allograft implantation surgery should be minimally invasive, not sacrificing the original meniscal insertion points. It appears preferable to use an open technique in medial transplantation, whereas the arthroscopic approach appears to allow for easier lateral implantation.

Keywords : meniscus ; meniscectomy ; meniscal transplantation ; meniscal allograft.

Mots-clés : ménisque ; méniscectomie ; arthrose ; transplantation méniscale ; allogreffe méniscale.

The anterior horn of a medial meniscus, which had been torn 10 months previously, was sutured to its former peripheral attachment. The patient was discharged after 10 weeks with an almost normally functioning knee.

Since that time arthrotomy and meniscectomy have become common orthopedic procedures. In the 1950s and the 1960s total meniscectomy was performed for almost any meniscal tear that was diagnosed on clinical examination. In the last two decades, however, arthroscopy of the knee joint has provided us with a means of performing adequate meniscectomy following the technical rules laid down by several authors including Jackson (7), Sprague (13) and Rand (12).

The period between 1970 and 1980 showed that with a carefully executed arthroscopic meniscectomy for a torn medial meniscus, functional restoration was achieved in more than 90% of the cases.

The short-term results of these resections are comparable to those of open meniscectomy as far as the medial compartment of the knee is concerned.

In the longer term and in the event of medial meniscectomy, factors such as varus malalignment and mechanical overload increase the risk of degeneration of the load-bearing cartilage in the medial compartment (fig. 1). Not only will the

INTRODUCTION

Why save the meniscus ?

On November 16, 1883 Thomas Annandale (2) was the first to perform a medial meniscal suture.

Department of Orthopedic Surgery, Physical Medicine and Rehabilitation, Ghent University Hospital.

Correspondence and reprints : R. Verdonk, Department of Orthopedic Surgery, Physical Medicine and Rehabilitation, Universitair Ziekenhuis, De Pintelaan 185, 9000 Gent, Belgium.

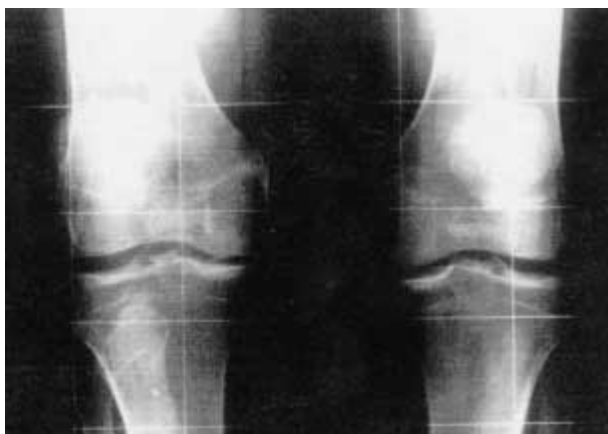

Fig. 1. — In the event of a medial meniscectomy (right knee), factors such as varus malalignment and mechanical overload increase the risk of degeneration in the load-bearing medial compartment.

buffer function of the semilunar cartilage be absent between the femoral condyle and medial tibial plateau, but the stabilizing factor, i.e. the meniscal wall, will also be lacking. As a result, there will be an increased anteroposterior shift of the femoral condyle in relation to the medial tibial plateau (fig. 2).

Any ligamentous laxity produced by the initial trauma will increase the degenerative changes in the load-bearing area. Of even more importance but medically uncontrollable is the magnitude of the mechanical load. This load is a separate element dependent on the weight of the patient and on work- and sports-related activities.

The same rules apply to the older age groups. The short-term results of accurate arthroscopic meniscectomy are superior to those of open total meniscectomy because of the preservation of the meniscal wall. Again, the quality of the load-bearing cartilage will determine the functional outcome in this age group. In the long run, only 50% of the patients will benefit from arthroscopic medial meniscectomy. These poor to fair results in the older age groups have cautioned against the negative consequences of meniscectomy, so that a meniscal suture is performed whenever this is feasible.

Within a short time, the meniscal suture will lead to meniscal healing, and one can expect a function-

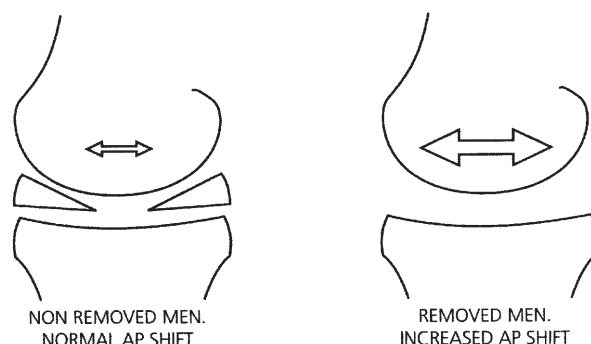


Fig. 2. — With total meniscectomy an increased anteroposterior shift can be expected.

ally competent knee and an anatomical restoration in 90% of the cases (3).

If chondral congruity is indeed improved by the presence of the medial meniscus under loading conditions, then this certainly applies to the lateral compartment. Indeed, the convex lateral femoral condyle articulates with an almost convex lateral tibial plateau. The contact area between both cartilaginous elements is flattened and widened only because of the presence of the O-shaped lateral meniscus. One should be even more cautious in the treatment of a lateral meniscal lesion than when confronted with a torn medial meniscus.

Clinical experience has shown that problems may arise even after correct and adequate resection of a torn lateral meniscus (1, 7, 12, 13).

ANIMAL EXPERIMENTS

Introduction

Meniscal allografts and tendon autografts have been shown in animal studies to heal (9) to the capsule and be repopulated with host cells as well as revascularized. Neither tendon nor meniscal allografts tend to gain the properties of normal menisci. Even though they appear to offer some protection to the cartilage in the knee joint, there is no evidence that degenerative changes can be prevented. It is not clear whether the cellular repopulation is sufficient to induce a restoration of adequate biomechanical properties. Tissue-engineered grafts are

still under investigation, but are showing promising results.

Different types of meniscal substitutes

1. *Meniscal prostheses*

Teflon and Dacron prostheses have demonstrated some chondroprotective effect in the rabbit knee. However, with respect to the biomechanical properties, the implanted joint appears closer to a meniscectomized joint than to a normal knee joint. Further research is investigating other types of implants (10).

2. *Tissue-engineered grafts*

Tissue-engineered menisci have been under investigation as an implant.

In rabbits at one year they appear macroscopically difficult to discern from the host meniscus. The histology offers the same appearance as a native meniscus. The biomechanical qualities of these engineered menisci seem to reflect the native tissue.

3. *Scaffolds*

Collagen scaffolds have been implanted, serving as a template to regenerate meniscal cartilage. Animal experiments have shown that host chondrocytes migrate into the new tissue. Although scaffolds were originally designed for partially meniscectomized joints, their use as complete meniscal replacement is under investigation.

4. *Fat-pad autografts*

In sheep the transplanted pediculated infrapatellar fat-pad results in the development of a meniscus-like structure within 6 months (8, 9). The tissue deteriorates over time, as observed at one year. It remains weak throughout and does not compare to the original meniscal tissue.

5. *Tendon autografts*

Communicable diseases can be avoided by using autografts. The patellar tendon in sheep used as a

graft remodels to meniscus-like tissue (8, 9). After one year strong circumferential collagen fiber bundles can be identified. However, the biomechanical properties seem to be inferior to the original meniscal tissue.

6. *Meniscal allografts*

Animal experiments regarding this type of implantation are numerous (9). Results seem to be dependent on the tissue conservation methods.

The experiments have shown that the allografts generally heal to the capsule and are revascularized and repopulated with host cells.

HUMAN EXPERIENCE

1. Introduction

The aims of a meniscal replacement are :

- to reduce the pain experienced by some patients following meniscus resection ;
- to prevent the degenerative changes of cartilage and the changes in subchondral bone following meniscus resection ;
- to avoid or reduce the risk of degenerative arthritis following meniscus resection ;
- to restore optimally the mechanical properties of the knee joint after meniscus resection.

In humans, the results of meniscus transplantation have been reported in several series of patients, operated with different techniques. There are no controlled studies of meniscus replacement in humans.

2. Technique

a) *Harvest*

Menisci are ideally harvested within 12 hours after the start of ischemia (14). In frozen grafts no cells survive. Cryopreservation allows the fibrochondrocytes to be preserved in 10 to 30 % of samples.

Meniscal implants are required to be readily available for transplantation. The material should

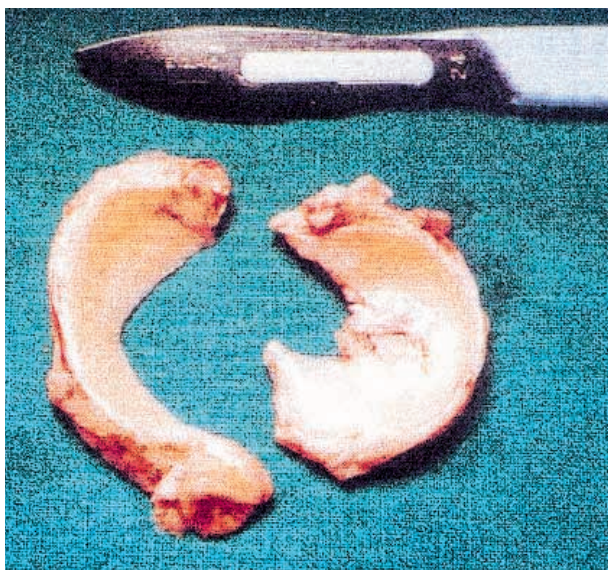


Fig. 3. — The menisci are removed from the donor knee joint. Only the medial meniscus is appropriate for transplantation. The lateral meniscus shows degeneration and is inappropriate for transplantation.

be safe regarding communicable diseases. Clinical immune response should be eliminated.

The meniscal bodies are removed from general organ donors (fig. 3). The freezing process can then be induced as fresh-frozen or following cryopreservation technique. The fresh-freezing process brings the material down to -78°C . In the cryopreservation process the deep-freezing is progressive, using DMSO (dimethylsulfoxide). The freezing temperature is -178°C .

According to Fabbriani *et al.* (4) the cryopreservation technique does not induce better histological results after implantation. The fresh-frozen allografts are inexpensive and allow easy storage. Sizing is also adequate in both techniques.

In viable meniscal allografting donor menisci are removed in an operating room under strict aseptic conditions, after the procurement of other organs from living (multiple-organ donors) or non-living donors. The cold ischemia time must not exceed 12 hours, during which the meniscus remains viable. Through a transverse arthrotomy, the lateral collateral ligaments and cruciate ligaments are divided and the knee is dislocated anteriorly.

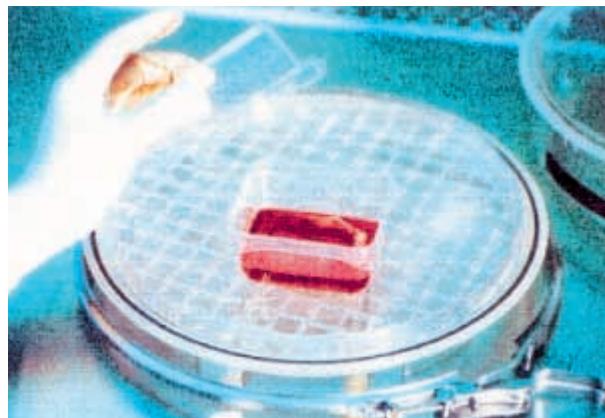


Fig. 4. — The plastic container is placed in an incubation chamber at a constant temperature of 37°C under continuous air flow.

The menisci can then be transported in a sterile physiological solution to the tissue bank. Under sterile conditions the specimens are then placed in culture, using Dulbecco's modified Eagle's medium with 0.002-M L-glutamine, 1/1000 antibiotic-antimycotic suspension (streptomycin 10 mg/ml, penicillin 10 U/ml, fungizone 0.025 mg/ml) and 20 % of the recipient's serum. This serum is prepared from the recipient's blood by centrifugation.

The menisci are then stored in a plastic container (DANCON; Teknunc - 4000 Roskilde, Denmark) to which 70 ml of incubation medium is added. The containers are placed in a modular incubation chamber (Flow Laboratories - Del Mar, California, USA) at a constant temperature of 37°C and under continuous air flow (95 % air and 5 % CO_2) (fig. 4). Humidity is controlled by placing an open receptacle filled with sterile water in the incubation chamber. The incubation media are replaced every three days.

The recipient's serum has been stored at -18°C and is appropriate for clinical use for a maximum of 6 weeks following venipuncture.

Results have shown that the transplanted allograft remains viable, producing fibrochondrocytes, proteoglycans and also collagen fiber structures. Normal cellular function can be expected from the moment of implantation, inducing potentially normal meniscal function, which may prove to be of great advantage compared to frozen allografts.

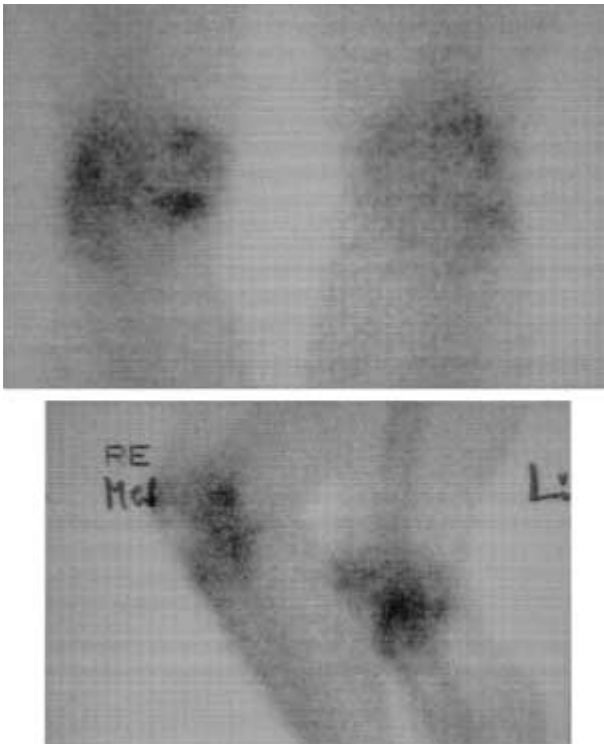


Fig. 5. — Disturbed homeostasis of the subchondral bone is well visualized by technetium bone scanning.

b. Preoperative planning

Introduction

Precise preoperative planning is mandatory to obtain good clinical results with meniscus transplantation (15). Any pathology in addition to the missing meniscus should be detected, including malalignment, and ligament instability. A full evaluation of the changes in the cartilage should be made. It is not known how precisely the donor meniscus needs to fit the size of the original meniscus to allow healing and regeneration.

Xrays

Anterior-posterior views are essential to exclude any major bone pathology. They will also indicate potential subchondral condensation and potential cystic degeneration.

Standing xrays

To properly determine any axial malalignment and potential joint space narrowing, standing xrays

are mandatory in the preoperative evaluation of the transplant recipient. Load-bearing xrays in 45° of flexion and 10° of ray inclination allow for better visualization of degenerative joint disease.

Bone scan

Disturbed homeostasis of the subchondral bone is appropriately visualized by technetium bone scanning (fig. 5). It is an excellent method to confirm mechanical pathology. Moreover, it allows for follow-up evaluation. Functional normalization of the joint after meniscus transplantation may result in normalization of the bone scan.

CT-scan

Both the donor's and the recipient's joints can be sized using CT-scan. It is appropriate to use this technique for evaluating the recipient's knee joint, as correct information about size of the allograft meniscus is obtained when the allograft is removed from the donor and measured.

MR-evaluation

MR-evaluation is mandatory to illustrate preoperative findings. Indeed, meniscal allografting is only indicated in **total** meniscectomy. Theoretically dynamic MRI may give valuable information about the mechanical behavior of the knee (ligaments, menisci(us)) before the operation, and after meniscus replacement.

Arthroscopy

Arthroscopy is the only means to evaluate the chondral status of the knee and thus to exclude extensive chondral deterioration (from grade 4) (fig. 6). Obviously, arthroscopy can also confirm that the meniscus is actually missing. If the arthroscopy is performed elsewhere, information (photo prints or video documents) should be available to the surgeon and correlated with MRI findings.

c) Surgical technique

In case of meniscal allograft implantation, surgery should be minimally invasive, not sacrificing the original meniscal insertion points (6). It appears to be preferable to use an open technique in medial transplantation, whereas the arthroscopic

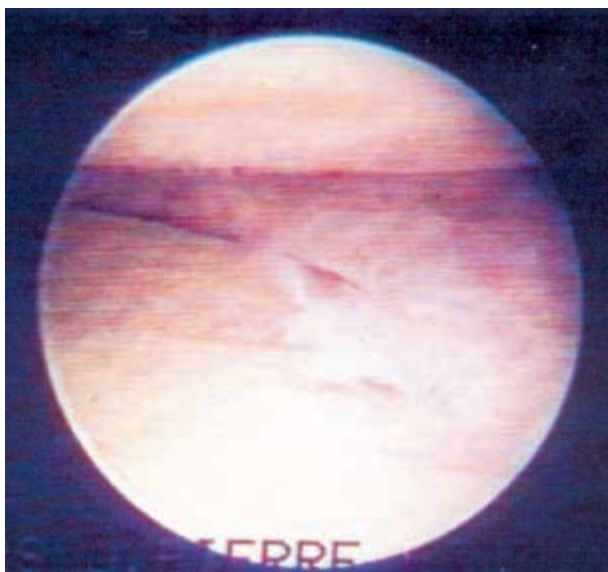


Fig. 6. — Arthroscopy is the only means to evaluate the chondral status of the knee efficiently and thus to exclude extensive chondral deterioration (from grade 4).

approach appears to allow for easier lateral implantation.

Transplantation of the medial meniscus

Epidural anesthesia is induced and a tourniquet is applied. The patient is placed supine, and a medial anterior arthrotomy is performed. The possible meniscal remnant is resected down to the meniscosynovial junction until a potentially bleeding surface is exposed. Whether a standard medio-posterior incision is made to facilitate transplantation and further removal of the meniscal remnant, or an osteotomy of the medial collateral ligament is performed, the meniscus can be inserted using 2.0 PDS sutures. In case of bone plug fixation, one should consider the increased difficulty in regard to a more difficult technique and the increased risk of improper placement of the bone plugs (11).

Transplantation of the lateral meniscus

Because of inherent increased varus laxity versus valgus laxity, the arthroscopic technique has a greater indication in lateral meniscal transplantation.

The lateral meniscal allograft is prepared, whether associated with bone plug fixation or

meniscal wall suture or fixation, and the allograft is inserted through a lateral arthroscopic portal, allowing easy passage through the skin.

In case of an open approach, an extended lateral skin incision allows for an osteotomy with bone plug of the lateral collateral ligament and popliteal tendon insertion. This approach opens up the lateral compartment and makes implantation of the lateral meniscus from posterior to anterior possible (fig. 7a, b).

Technique for tendon transplantation

Kohn (6) described a modified medial hockey-stick incision, allowing detachment of the medial collateral ligament with a bone block. This allows medial opening of the knee joint and precise drill hole preparation, with correct insertion of the tendon autograft. The graft thickness should be at least 5 mm to permit correct graft fixation.

3. Results

Meniscal transplants

In a 12-year period, a total of 98 patients have been operated in our department. Seventy-eight patients are included in a 10-year follow-up. Nine patients had to be excluded. Five of these 9 patients underwent total knee arthroplasty owing to progressive osteoarthritis of their knees with severe incapacity. Two foreign patients could only be contacted by telephone and were not included in the results. Two patients were lost to follow-up. Sixty-two percent of the patients ($n = 69$) resumed their original work. Eighty-seven percent of the patients said they would undergo transplantation again if necessary.

The HSS-score increased postoperatively and remained constant afterwards. There was only a decrease ($p < 0.05$) in the HSS-score in patients with a 10-year follow-up compared with patients with a 9-year follow-up. The preoperative HSS-score was 113 ± 27 (fig. 8). At a mean follow-up of 5 years 4 months, 79% of the 69 patients still scored more than 175 points, 21% scored from 100 to 175 points, and none fell below 100 points.

Pre- and postoperative pain evaluation was significantly different ($n = 69$; $p < 0.05$) (fig. 9).

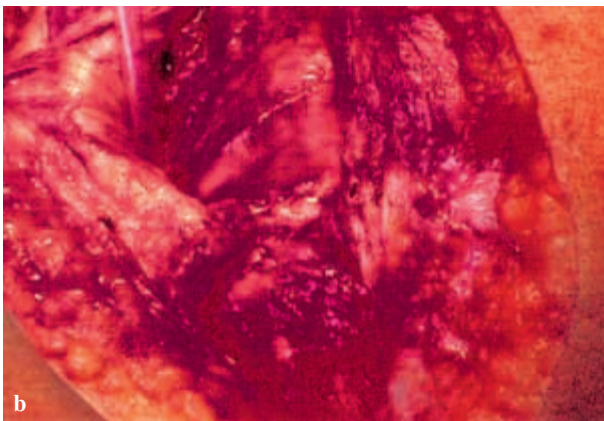
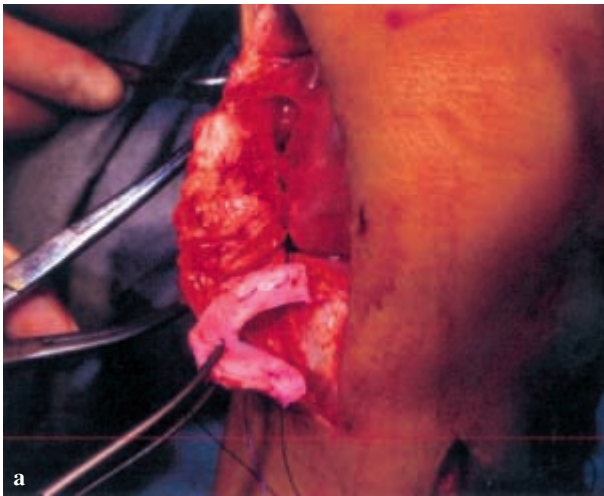


Fig. 7. — *a.* The threaded viable meniscal allograft is inserted from posterior to anterior. An osteotomy of the femoral insertion of the lateral collateral ligament allows for easy access to the posterolateral corner of the lateral knee joint. *b.* Once the lateral meniscus is in place, fixation of the anterior horn in its original location allows for appropriate fitting of the meniscus *in situ*.

There was no significant statistical difference in the HSS-score between medial transplantation and medial transplantation in association with a valgus osteotomy ($p = 0.39$) nor between lateral meniscal transplantation and medial meniscal transplantation in association with a valgus osteotomy ($p = 0.19$). When the purely medial and lateral transplants were compared, no difference was found in HSS-score ($p = 0.17$) or in pain relief (fig. 10).

Wirth *et al.* (16) presented comparable results with deep-frozen meniscal implants. When lyophi-




Fig. 8. — The preoperative score was 113 ± 27 . At a mean follow-up of 5 years and 4 months, 79% of the 69 patients still scored more than 175 points, 21% scored from 100 to 175 points, and none fell below 100 points.

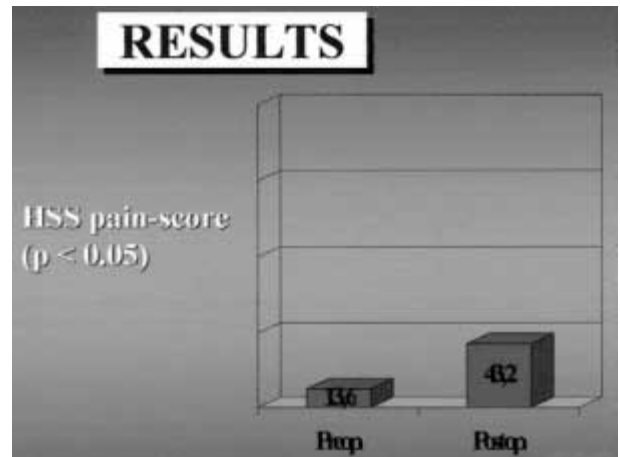


Fig. 9. — Pre- and postoperative pain evaluation was significantly different ($n = 69$; $p < 0.05$).

lization techniques are used for meniscal preservation, less than optimal results are obtained.

Tendon allograft

Kohn *et al.* (8) have reported their experience in 28 patients to compensate for medial meniscectomy. It appears that the quadriceps tendon autograft does not change into a tendon meniscus as was reported in animal experiments. However, there was a tendency to some range of motion decrease, associated with improved anterior/posterior stability in 70° of flexion. Progression of chondromalacia was seen arthroscopically, although no progress of osteoarthritis could radiologically be retained.

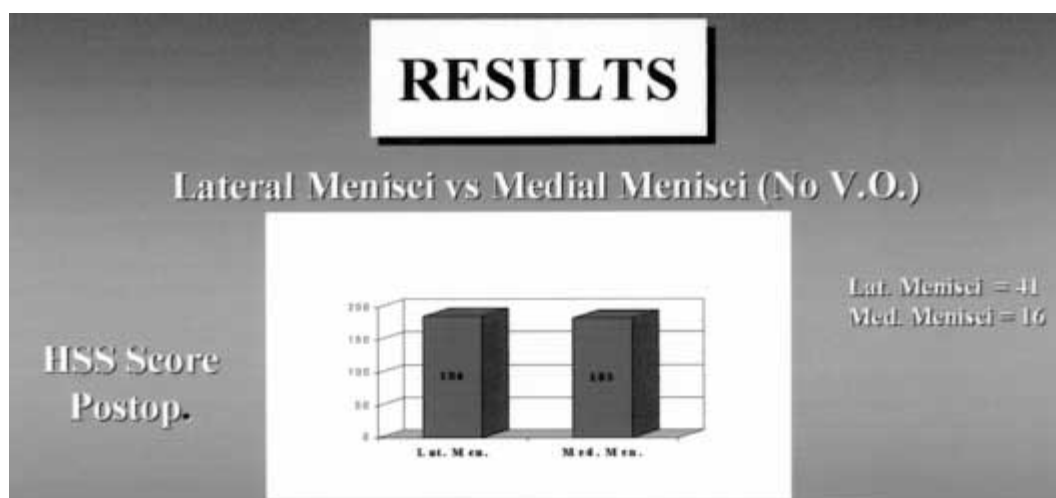


Fig. 10. — There was no statistical difference between medial and lateral transplants ($p = 0.17$) in regard to pain relief

4. Rehabilitation

Postoperative regimen

Some studies on meniscal allograft transplantation recommend a continuous passive motion machine during the first postoperative days (8). Passive and active nonweight-bearing motion from 0 to 60° or to 90° is recommended from 4 to 6 weeks. Especially for knees that have had concomitant anterior cruciate ligament reconstruction, more accelerated rehabilitation is indicated in order to prevent fibrosis. It is generally recommended that weight bearing the first 4-6 weeks should be brace-controlled with full extension in order to avoid shear forces to the allograft. These restrictions arise from basic knowledge of the meniscal loading pattern during motion. Load stress on the meniscus increases with increased knee flexion; in particular the medial posterior horn is stressed in knee angles over 60°, but femoral anterior-posterior translation and rotation also affect the load pattern of the meniscus. However, some weight bearing should be allowed, as controlled stress stimulates collagen synthesis and increases the strength of connective tissues (Wolff's law). Thus, probably the meniscal allograft too benefits from repetitive hoop stress during knee joint weight loading, and adapts with increased tensile properties over time. That is, of

course, only if the repopulated host cells in the graft are sufficient to restore the meniscal collagen architecture and strength. These rather crucial questions in meniscal allograft transplantation remain unanswered, and should be addressed in biomechanical studies.

Approximately six weeks postoperatively, gait training and weight-loaded, closed kinetic-chain activities up to 60° flexion can be introduced. Among other beneficial effects, this training stimulates the known proprioceptive properties of the meniscus. Muscle strength training is also of importance in rehabilitation, in particular quadriceps strength, because this muscle serves as a secondary shock absorber to the knee joint, and thus relieves load stress on the meniscus. From 6 to 12 months, full weight bearing, full range of motion, and return to previous activity are recommended.

5. Conclusion

The general clinical indication in meniscal transplantation has been disabling pain in case of total meniscectomy in the skeletally mature individual. The healing of the graft to the capsule occurs in more than 80 % of the control transplants. Revascularization and cell repopulation have been retained but can be variable.

Combined concomitant surgery can influence the appreciation of the result.

Graft preservation induces variable results as most patients experience pain decrease allowing for increased activity levels postoperatively. Frozen or cryopreserved allografts appear to be the most promising in short-term results. Viable meniscal allografts seem to survive transplantation as donor fibrochondrocytes are found at DNA fingerprinting evaluation at two years. The clinical outcome does not correlate with meniscal imaging.

Quadriceps tendon autograft appears to induce clear pain relief, even though follow-up arthroscopy does not reveal meniscus-like tissue.

There is no clinical proof that substitutes can protect the hyaline cartilage of both femur and tibia when meniscal substitution has been performed. Three factors however have been identified to decrease meniscal substitute function: poor fixation at the anterior and posterior meniscal horn, limited transplant contact with the articulating surfaces of the knee and abnormal horn positioning.

REFERENCES

1. Aagaard H., Verdonk R. Function of the normal meniscus and consequences of meniscal resection. *Scand. J. Med. Sci. Sports*, 1999, 9, 134-140.
2. Annandale T. H. An operation for displaced semilunar cartilage. *Brit. Med. J.*, 1885, 1, 779-781.
3. De Meulemeester C., Verdonk R., Van Eetvelde G., Claessens H. The value of CT. scan in the evaluation of meniscal sutures. *Proceedings of the 103rd Annual meeting of the American Orthopaedic Association*, Boston, Massachusetts, 1990, p. 103.
4. Fabbriciani C., Lucania L., Milano G., Schiavone P. A., Evangelisti M. Meniscal allografts: Cryopreservation vs deep-frozen technique. An experimental study in goats. *Knee. Surg. Sports Traum. Arthrosc.*, 1997, 5, 124-134.
5. Goble E. M., Kohn D., Verdonk R., Kane S. M. Meniscal substitutes – Human experience. *Scand. J. Med. Sci. Sports*, 1999, 9, 146-157.
6. Goble E. M., Verdonk R., Kohn D. Arthroscopic and open surgical techniques for meniscus replacement – Meniscal allograft transplantation and tendon autograft transplantation. *Scand. J. Med. Sci. Sports*, 1999, 9, 168-176.
7. Jackson R. W. The role of arthroscopy in the management of the arthritic knee. *Clin. Orthop.*, 1974, 101, 28-35.
8. Kohn D., Aagaard H., Verdonk R., Dienst M., Seil S. Postoperative follow-up and rehabilitation after meniscus replacement. *Scand. J. Med. Sci. Sports*, 1999, 9, 177-180.
9. Kohn D., Verdonk R., Aagaard H., Seil R., Dienst M. Meniscal substitutes – Animal experience. *Scand. J. Med. Sci. Sports*, 1999, 9, 141-145.
10. Messner K., Kohn D., Verdonk R. Future research in meniscal replacement. *Scand. J. Med. Sci. Sports*, 1999, 9, 181-183.
11. Messner K., Verdonk R. Is it necessary to anchor the meniscal transplants with bone plugs? A mini-battle. *Scand. J. Med. Sci. Sports*, 1999, 9, 186-187.
12. Rand J. A. Arthroscopic management of degenerative meniscus tears in patients with degenerative arthritis. *Arthroscopy*, 1985, 1, 253-258.
13. Sprague N. F. III. Arthroscopic debridement for degenerative knee joint disease. *Clin. Orthop.*, 1981, 160, 118-123.
14. Verdonk R., Kohn D. Harvest and conservation of meniscal allografts. *Scand. J. Med. Sci. Sports*, 1999, 9, 158-159.
15. Verdonk R., Kohn D. Meniscus transplantation: Preoperative planning. *Scand. J. Med. Sci. Sports*, 1999, 9, 160-161.
16. Wirth C. J., Milachowski K. A., Weismeier K. Die Meniskus-transplantation im Tierexperiment und erste klinische Ergebnisse. *Z. Orthop.*, 1986, 124, 508-512.

SAMENVATTING

R. VERDONK. Meniscustransplantatie.

Een meniscustransplantatie heeft als doel

- 1) de pijn te verlichten die sommige patiënten ervaren na een meniscusresectie;
- 2) kraakbeendegeneratie en veranderingen in subchondraal bot te voorkomen;
- 3) het risico van artrose na een meniscusresectie te vermijden of te verminderen;
- 4) de mechanische eigenschappen van het kniegewricht maximaal te herstellen.

De resultaten van meniscustransplantatie werden bestudeerd bij dieren en er werd geen enkel bewijs gevonden dat het vervangen van een meniscus het risico van artrose doet dalen. Er zijn echter wel aanwijzingen dat de ingreep het optreden van kraakbeendegeneratie kan verminderen.

Er werden ook studies gewijd aan het effect van meniscustransplantatie bij verschillende reeksen patiënten die met verschillende technieken werden geopereerd, maar gecontroleerde studies werden bij de mens nog niet verricht.

Het implanteren van een meniscusallotransplantaat dient minimaal invasief te gebeuren, zonder de oorspronkelijke meniscusale insertiepunten op te offeren. Voor

transplantatie van de mediale meniscus lijkt een open techniek de voorkeur te verdienen, terwijl een arthroscopische aanpak de implantatie van de laterale meniscus lijkt te vergemakkelijken.

RÉSUMÉ

R. VERDONK. La transplantation méniscale.

La transplantation méniscale a pour but :

- 1) de réduire la douleur consécutive à la méniscectomie totale ;
- 2) de prévenir ou du moins de limiter la dégénérescence cartilagineuse ;
- 3) de diminuer le risque d'arthrose après méniscectomie ;
- 4) de restaurer les caractéristiques mécaniques du genou normal.

Les résultats de la transplantation méniscale chez l'animal n'ont pas prouvé qu'elle élimine le risque d'arthrose évolutive, mais elle semble limiter la dégénérescence articulaire.

Il n'y a pas encore, dans la littérature, d'études contrôlées qui pourraient démontrer un effet bénéfique à long terme sur le genou suite à une transplantation méniscale réalisée par l'une ou l'autre technique.

De toute façon il semble clair que la transplantation doit se faire avec une technique aussi atraumatique que possible, en respectant l'insertion anatomique originelle du ménisque.

La transplantation méniscale semble se faire avec plus d'efficacité par chirurgie classique dans le compartiment interne, tandis que dans le compartiment externe, l'implantation de l'allogreffe méniscale peut se faire par voie arthroscopique.