

FAITS CLINIQUES — CASE REPORTS

EN-BLOC RESECTION OF THE DISTAL FIBULA FOR ANEURYSMAL BONE CYST

J. CASO MARTÍNEZ, J. GONZALEZ ACHA, J. I. GONZALEZ GALARRAGA, J. M. SAROBE ANDUEZA

A 21-year-old woman who presented with a voluminous aneurysmal bone cyst in the distal left fibula was treated with en-bloc resection. After 30 months of follow-up, the stability and range of motion of the left ankle were similar to that of the contralateral ankle.

Keywords : aneurysmal bone cyst ; distal fibula ; en-bloc resection.

Mots-clés : kyste anévrisimal de l'os ; péroné ; résection en bloc.

INTRODUCTION

The localization of a bone tumor in the distal fibula is a problem for ankle stability when resection is indicated. Carrell (1) described a surgical procedure where the distal tibiofibular joint is reconstructed with the proximal fibula. En-bloc resection without reconstruction of the distal tibiofibular joint has been described by Carnesale (2) and Marcove (3). This paper reports another case of en-bloc resection with a follow-up of 30 months.

CASE REPORT

A 21-year-old woman was seen in the outpatient clinic with swelling and pain in her left ankle. Six months previously she had been treated for a bone cyst in the distal fibula with three methylprednisolone acetate infiltrations but was then lost to follow-up. The xrays showed an extensive lytic lesion with bone trabeculae in the distal fibula (fig. 1). A presumptive radiographic diagnosis of aneurysmal bone cyst (ABC) was made. The pathologist confirmed this diagnosis.

A resection with marginal margin was performed according to Campanacci *et al.* (4) and Enneking (5), without additional surgical reconstruction of the ankle (fig. 2). Postoperatively the




Fig. 1. — Radiograph of the tumor.

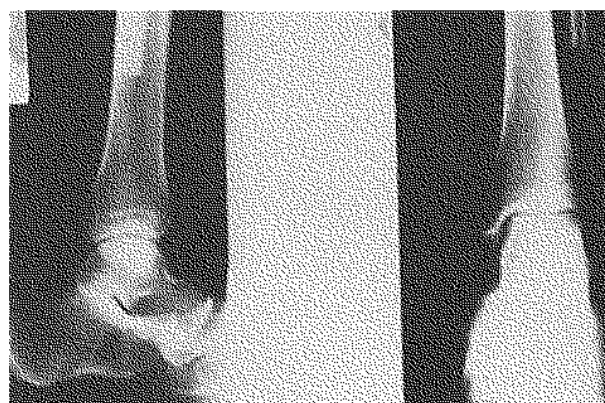

Fig. 2. — The ankle after resection of the distal fibula.

Traumatology and Orthopedic Service, Azantazu Hospital, San Sebastian, Spain.

Correspondence and reprints : J. Caso Martínez, Pescadores de Gran Sol 12 3° D, San Sebastian, E-20014, Spain.

ankle was immobilized in a cast during one week ; a dynamic orthosis was then worn for two months. The dynamic orthosis allowed free flexion-extension but no varus-valgus movements of the ankle.

At 30 months of follow-up the patient presented a stable ankle in varus-valgus (fig. 3, 4), and the range of motion was the same as in the contralateral ankle. She was able to run and jump without subjective instability.




Fig. 3. — Forced varus of both ankles after 30 months.




Fig. 4. — Forced valgus of both ankles after 30 months.

DISCUSSION

ABC in the distal fibula is an uncommon localization with a frequency varying between 1.5 and 3.8% in different series (4, 6, 7).

The tumor was stage 2-3 in the Enneking classification or aggressive-active grade II in the Campanacci classification. Both authors recommend resection.

The main problem after resection of the distal fibula is the potential ankle instability. Carrell (1) described reconstruction with the proximal fibula but this procedure could imply knee instability due to the lesion of the lateral collateral ligament of the knee, or ankle pain after reconstruction due to incongruity of the articular surfaces.

It is our presumption that cicatricial fibrous tissue can provide ankle stability after resection of the distal fibula as in the cases of Carnesale (2) and Marcove (3) and in this case report.

CONCLUSION

En-bloc resection seems a good surgical treatment for tumors that require resection of the distal fibula. However if instability appears after a short period of time, stability can be obtained through the Carrell procedure or even a fibular allograft. If instability appears after a long period of time a tibiotalar arthrodesis can be performed.

REFERENCES

1. Carrell W. B. Transplantation of the fibula in the same leg. *J. Bone Joint Surg.*, 1938, p. 627.
2. Carnesale P. G. *Campbell's operative orthopaedics*. Mosby year book, St. Louis, 1987, p. 719.
3. Marcove R. C. En-bloc resection for osteogenic sarcoma. *Can. J. Surg.*, 1977, 20, 521-528.
4. Campanacci M., Capanna R., Picci P. Unicameral and aneurysmal bone cyst. *Clin. Orthop.*, 1986, 204, 25-36.
5. Enneking W. F. A system of staging musculoskeletal neoplasms. *Clin. Orthop.*, 1986, 204, 9-24.
6. Martinez V., Sissons H. A. Aneurysmal bone cyst. A review of 123 cases including primary lesions and those secondary to other bone pathology. *Cancer*, 1988, 61, 2291-2304.
7. Ruitter D. J., Van Rijssel T. G., Van Der Velde E. A. Aneurysmal bone cyst. A clinicopathological study of 105 cases. *Cancer*, 1977, 2231-2239.

SAMENVATTING

J. CASO MARTÍNEZ, J. GONZALEZ ACHA, J. I. GONZALEZ GALARRAGA en J. M. SAROBE ANDUEZA. En-bloc resectie van het distale uiteinde van de fibula, wegens aneurysmale botcyste.

De auteurs rapporteren het geval van een 21-jarige vrouw met een volumineuze aneurysmatische botcyste

t.h.v. het distale uiteinde van de fibula, behandeld met en-bloc resectie. Dertig maanden na de ingreep waren beweeglijkheid en stabiliteit volledig gerecupereerd.

l'extrémité inférieure du péroné gauche, traité par résection en-bloc. Trente mois après l'intervention, la stabilité et la mobilité de la cheville étaient revenues à la normale.

RÉSUMÉ

J. CASO MARTÍNEZ, J. GONZALEZ ACHA, J. I. GONZALEZ GALARRAGA et J. M. SAROBE ANDUEZA. Résection en bloc de l'extrémité inférieure du péroné pour kyste osseux anévrisimal.

Les auteurs rapportent le cas d'une femme de 21 ans, présentant un volumineux kyste osseux anévrisimal de