

VERTEBRAL OSTEOMYELITIS A CASE WITH MASSIVE OSTEOLYSIS AND COMPRESSION OF THE DURAL SAC

by M. A. VILATELA, J. HUGUET, F. GIRVENT and A. NUÑEZ

We present a case of a 59-year-old male with 6 bilateral sensory and motor involvement of spinal roots L₅ through S₄ due to compression of the dural sac caused by a *staphylococcus* infection. We also discuss the treatment and favorable progress with major recuperation of the motor, sensory and sphincter functions.

Keywords : vertebral osteomyelitis ; *staphylococcus* infection ; osteolysis ; dural sac.

Mots-clés : ostéomyélite vertébrale ; infection staphylococcique ; ostéolyse ; sac dural.

RÉSUMÉ

M. A. VILATELA, J. HUGUET, F. GIRVENT et A. NUÑEZ. *Ostéomyélite vertébrale. Présentation d'un cas avec ostéolyse massive et compression du sac dural.*

Les auteurs décrivent le cas d'un homme de 59 ans, présentant une atteinte sensitivo-motrice des racines L₅ à S₄, par compression du sac dural, causée par une infection staphylococcique. Ils discutent le traitement et décrivent l'évolution favorable avec bonne récupération des déficits moteurs, sensibles et sphinctériels.

SAMENVATTING

M. A. VILATELA, J. HUGUET, F. GIRVENT en A. NUÑEZ. *Osteomyelitis van de wervelkolom. Eén geval met massieve osteolyse en compressie van de dura.*

De auteurs beschrijven het geval van een 59-jarige man met bilaterale sensitivo-motorische uitval in de wortelgebieden L₅ tot S₄, door compressie van de

dura, veroorzaakt door een staphylococceïnfectie. Beschrijving van de behandeling en van het beloop met gunstige recuperatie van motoriek, sensibiteit en sphincter-functie.

Hematogenous osteomyelitis in adults is more frequent in males, especially in those older than 60 years of age (1), and shows a clear predilection for the vertebral bodies (4). Although it is not a common pathology, the frequency is increasing (5). The majority of authors concur with the opinion that *Staphylococcus aureus* is the most frequently implicated germ, as it is isolated in 50% of the reported cases (4).

Wiley and Trueta (6) based their studies on the blood supply to the vertebral bodies and concluded that :

1. Bacteria penetrate through the nutrient branches of the posterior spinal arteries, whereas veins are an inaccessible route.
2. The initial lesion develops in the area of greatest arterial capillary irrigation, that is the Antero-Superior Vertebral Body. This region is destroyed, and the process then invades the intervertebral disk and the lower portion of the vertebral body immediately above. For this reason spondylitis is really *osteoarthritis of the spine* (3). The initial bacteremia can go unnoticed as local clinical manifestations usually appear much later, 54 days on the average (4). The clinical symptoms

Department of Traumatology, Sabadell Hospital, Barcelona (Spain).

and biological signs of infection may also be very slight. This frequent atypia of the manifestations is usually the cause of a late diagnosis, from 2 to 4 months in the majority of series (4). The main symptom is *pain*, a deep, constant ache localized in a vertebral area, that does not diminish with rest and that requires analgesia. We must always consider *spondylitis* when faced with any adult with persistent spinal pain, whether or not there is fever or any other indication of infection.

The radiological alterations can appear weeks or months after the onset of clinical symptoms. In 30 cases studied by Digby and Kersley (2) the sequences were as follows: pinching of the disk (2 weeks), rarefaction of the bone (6 weeks), reactive perifocal sclerosis (8 weeks), peripheral neo-ossification (12 weeks) and osseous fusion (6 months).

This disease must be better understood. The need for *early diagnosis and suitable treatment* in order to prevent serious complications leads us to present the following case report.

CASE REPORT

A 59-year-old male patient was transferred from the internal medicine department because of massive osteolysis of L₅, as well as bilateral acromial osteolysis. He was in poor general condition.

Past medical history was notable for obesity, psoriasis since the age of 15 years and malaria at age 11.




Fig. 1. — Osteolysis of the left acromion.

Ten months prior to admission the patient exhibited signs of a toxic syndrome (asthenia, anorexia, loss of 6 kg and insomnia), dysphagia mainly for solids, dysarthria and subjective weakness of both lower limbs that occasionally caused falls. The weakness was accompanied by dysesthesias that appeared as “sharp pains” and “cramps”. He had consulted various medical specialists and, after several investigations, his complaints were classified as possibly having a functional etiology. Finally he was admitted to the internal medicine department of our hospital. Physical examination showed slight rigidity and loss of strength in the lower limbs, slight hyperreflexia of the right patellar tendon reflex, moderate increase of the erythrocyte sedimentation rate, a moderate, predominantly parietal, cortical atrophy with a small right frontoparietal ischemic infarction on tomographic study of the brain.

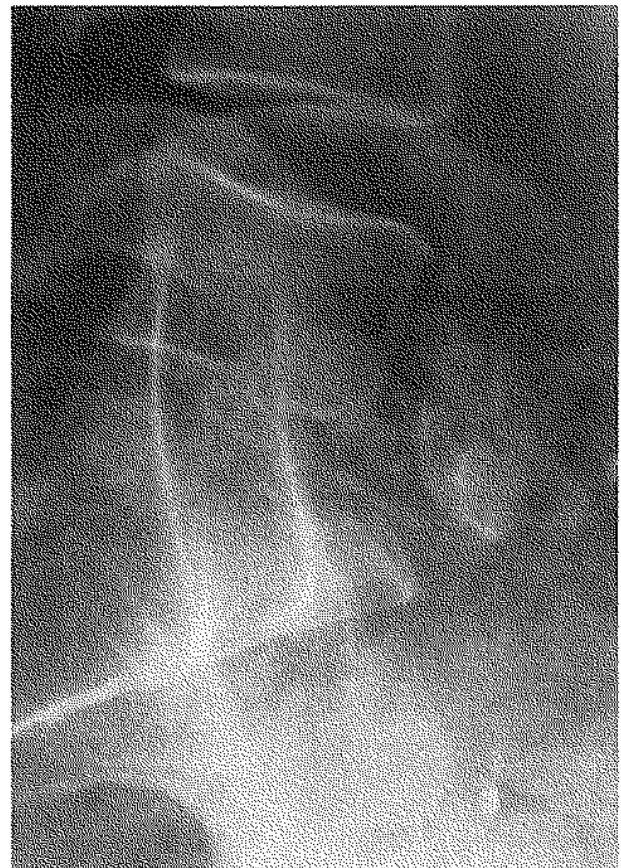


Fig. 2. — Lateral x-ray showing massive osteolysis of the 5th lumbar vertebra and its collapse into the vertebral space.

The patient then developed a left parotitis accompanied by general symptoms 15 days after admission. In a series of cultures of the blood and the urine *Staphylococcus aureus* was isolated. This was treated with intravenous cloxacillin. A few days later he developed an abscess of the right elbow; this was opened and a culture once again showed *Staphylococcus aureus*. At the same time he began to lose strength in the lower limbs, leading to paraparesis and urinary incontinence. At this stage he was transferred to our department. The patient was febrile and in poor general condition, and showed cutaneous psoriatic lesions. There was complete paralysis of the anterior tibial, peroneals, extensors and bilateral triceps surae muscles, paresis of the psoas, which showed only isometric contractions, as well as of the quadriceps and the ischiotibial muscles. There was complete anesthesia from L₅ to S₄, with absence bilaterally of the patellar tendon reflexes and bilateral triceps surae reflexes with an indifferent cutaneous plantar reflex. There was pain and functional impairment of both shoulders, more pronounced over the acromion, with no signs of local inflammation. There were decubitus ulcers on the heels and in the sacral region.

Laboratory analyses showed an increased erythrocyte sedimentation rate, hypochromic and microcytic anemia, and hypoproteinemia with hypoalbuminemia. Radiography and tomography of both shoulders showed bilateral acromial osteolysis. Radiography and CT scan of the lumbosacral area demonstrated massive osteolysis of L₅ and the superior surface of S₁ resulting in a collapse of the 5th lumbar vertebral body with L₄ occupying the space of L₅; multiple bone fragments were displaced towards the interior of the spinal canal. Isotope scans (technetium and gallium) showed increased uptake in both the acromion and L₅ to S₄, compatible with an infectious or an inflammatory process. Acromial aspiration resulted in isolation of *Staphylococcus aureus*.

The patient therefore had symmetric bilateral acromial osteolysis and massive osteolysis of the 5th lumbar vertebra of infectious origin with compression of the dural sac at the L₅ level producing a motor, sensory and vegetative deficit from L₅ to S₄.

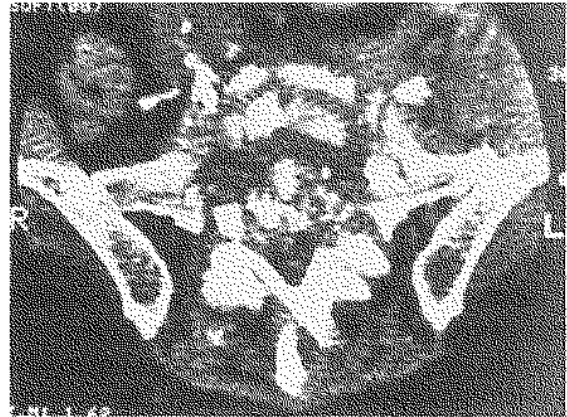


Fig. 3. — CT-Scan of the lumbosacral column showing the destruction of the body of L₅ and the upper surface of S₁ with reduction in the diameter of the spinal canal and narrowing of both foramina.

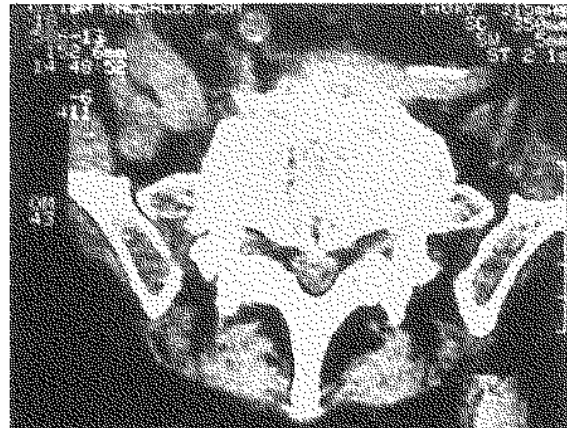


Fig. 4. — CT-Scan of the lumbosacral region of the spine 4 months after discharge from the hospital. The increase in the density of the lesions with calcification and stabilization of the process can be seen.

The patient was placed on strict bed rest; with intravenous cloxacillin, postural changes with intensive care of decubitus ulcers, thromboembolic prophylaxis with calciheparin, analgesia, a high-protein diet and the establishment of a rehabilitation program. Consideration was given to surgical decompression of the dural sac and osteosynthesis via a posterior approach, but this was not performed owing to the presence of the decubitus ulcer in the sacral region.

As part of the problem was localized anteriorly in the spine, an anterior approach was also considered. However the patient was in poor

general condition, and the most important problem was the motor deficit from the compression of the dural sac and the nerve roots (mainly L₅ and S₁ roots). Decompression was therefore best carried out through a posterior approach, despite the anterior location of the lytic process. We believe that in the surgical treatment the decompression of the nerve roots is to be preferred to the vertebral arthrodesis (see conjunction holes in CAT-scan). Essentially, it is difficult to obtain the decompression of the nerve roots through an anterior approach of the spine, and the poor general condition of the patient does not recommend an aggressive technique.

After 4 months of treatment the fever resolved the erythrocyte sedimentation rate returned to normal, and the decubitus ulcers healed. The urinary incontinence resolved, and there was a progressive increase in strength in the lower limbs. The pain disappeared completely and sensibility returned to normal.

Four months after discharge the patient is walking and going up and down stairs with the aid of crutches. The CT-scan shows an increase in the density of the L₅-S₁ lesion with calcification and stabilization of the process.

BIBLIOGRAPHY

1. COSENTINO R. Osteomielitis vertebral. In: Raquis. *Semiología con consideraciones clínicas y terapéuticas*. 2^o ed. Ed. El Ateneo, Argentina, 1986, 173-176.
2. DIGBY J. M., KERSLEY J. B. Pyogenic Non-tuberculous Spinal Infection. *J. Bone Joint Surg.*, 1979, 61-B, 47-55.
3. DROBNIC L., SALVADOR R. *Afecciones osteoarticulares de origen infeccioso. Infecciones de partes blandas*. In: *Enfermedades infecciosas*. Verger, G. Ed. Doyma Barcelona, 1988, 564-577.
4. FERNANDEZ VILADRICH P. *Infección osteoarticular*. In: Foz A., Drobnic L. and Gudiol F. *Patología infecciosa básica: enfermedades bacterianas*. Ed. Idepsa Madrid, 1981, 218-229.
5. GANTZ N. M. *Vertebral osteomyelitis*. In *Manual of clinical problems in infectious disease*. Little Brown and Company, Boston, 1979, 253-256.
6. WILEY A. M., TRUETA J. The vascular anatomy of the spine and its relationship to pyogenic vertebral osteomyelitis. *J. Bone Joint Surg.*, 1959, 41-B, 796-800.

M. A. VILATELA

Av. Francesc Macia N° 78, 3°-A
08206 Sabadell, Barcelona (Spain)