

METATARSAL HEAD RESECTION IN THE DEFORMED, SYMPTOMATIC RHEUMATIC FOOT A COMPARISON OF TWO METHODS

P. J. M. VAN LOON¹, R. P. ARIES¹, R. P. KARTHAUS², B. J. J. M. STEENAERT³

Metatarsal head resection for the symptomatic, deformed, rheumatic foot was performed in 83 feet of 49 patients via a modified plantar approach with functional aftertreatment, and in 64 feet of 41 patients via a dorsal approach, followed by placement in a plaster cast for 6 weeks. Both groups were comparable with regard to age, sex, and follow-up. From 1975 to 1985, 147 feet (90 patients) were operated in two different hospitals. Of these, 25 patients (39 feet) were lost to follow-up. The average follow-up was 83.3 mo. (range 33-136 mo.). Data were obtained by studying the medical records and by questionnaires sent to all patients. The results in both groups were quite similar. However a higher rate of wound-healing problems was found with the dorsal approach. The plantar approach resulted in an increased recurrence of metatarsalgia, requiring surgical revision.

Keywords : metatarsal head ; resection ; rheumatic foot.

Mots-clés : tête métatarsienne ; résection ; pied rhumatoïde.

INTRODUCTION

Surgery for the painful, deformed forefoot in rheumatic disease usually involves resection arthroplasties. Unfortunately patients seek help in the later stages of the disease, when the advanced destruction and deformity of the forefoot becomes increasingly painful, and more conservative measures tend to fail.

We studied the results of metatarsal head resection in the rheumatic foot, comparing the

plantar approach with functional aftertreatment versus the dorsal approach with plaster casting and unguinal traction for 6 weeks.

MATERIALS AND METHODS

In the period 1975 to 1985 resection arthroplasties of the metatarsophalangeal (MTP) joint were performed in 147 feet of 90 patients in the orthopedic department of the University Hospital Nijmegen and the Municipal Hospital of Arnhem (table I). Data for follow-up were obtained from the medical records and by questionnaires sent to all patients concerning pain, walking ability, footwear before and after the operation and satisfaction about the results of the operation and aftertreatment, as well as on the form of the foot after operation. The two groups were generally comparable (table I).

The operative indication was metatarsalgia in the severely deformed rheumatic forefoot, causing limitation in duration of walking to less than half an hour. Infected bursae or clavi and evident clinical signs of vasculitis were contraindications to surgery.

All operations were performed with a tourniquet.

Patients in group I were operated via a dorsal approach (fig. 1). In this approach according to Larmon (3), three longitudinal incisions were used (fig. 1) for metatarsal II-V head resection, whereas the procedure for the first metatarsal was performed according to the modified Mayo-Hueter technique, trimming the first metatarsal head.

¹ University Hospital, Nijmegen, The Netherlands.

² Medisch Spectrum Twente, 7522 HB Enschede, The Netherlands.

³ Municipal hospital, 6500 HB Arnhem, The Netherlands.

Correspondence and reprints : P. J. M. Van Loon.

Postoperatively a below-knee plaster cast with transungual traction via an Esmarck splint was applied for 6 weeks. Mobilization was allowed after 1 week ; partial weightbearing after 3 weeks.

The patients in group II were operated via a plantar approach (fig. 2) and had functional aftertreatment with a bulky dressing. The plantar approach is a modification of the Lelievre procedure (4), through an incision over the top of the round foot (fig. 2) with

a longitudinal extension to reach the first and fifth metatarsal head for subcapital resection of II-V and trimming of the first metatarsal head. An incidental debasement of a proximal phalanx was carried out in case of a persistent dorsal contraction of a toe. Abundant subcutaneous fat tissue or skin was never resected. The foot was placed in a bulky dressing for 2 weeks. Full weightbearing was allowed after 5 to 6 days as initial wound healing had started.

Table I. — Characteristics of the series of patients from the University Hospital Nijmegen (Group I, dorsal approach), and from the Municipal Hospital Arnhem (Group II, Plantar approach)

	Dorsal approach (I)	Plantar approach (II)
Total number of operated feet	64	83
Number of patients	41	49
lost to follow-up		
- death	8	12
- unknown	2	3
Follow-up		
- patients	31	34
- operated feet	47	61
male/female	7-24	8-26
R/L	23-24	30-31
F-up		
av. (mo)	84.1	91.8
range (mo)	33-136	34-128

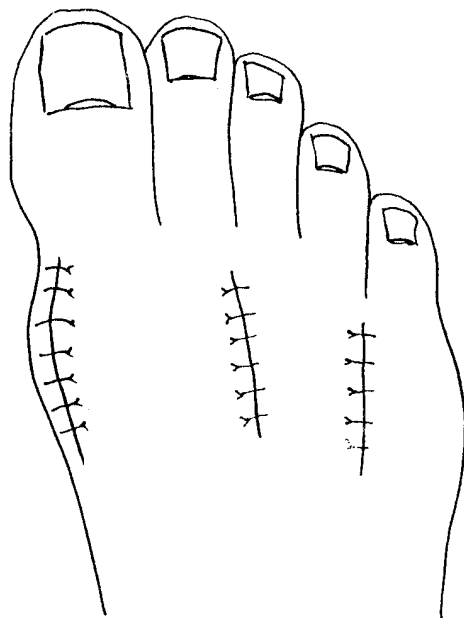


Fig. 1. — Dorsal approach for metatarsal head resection.

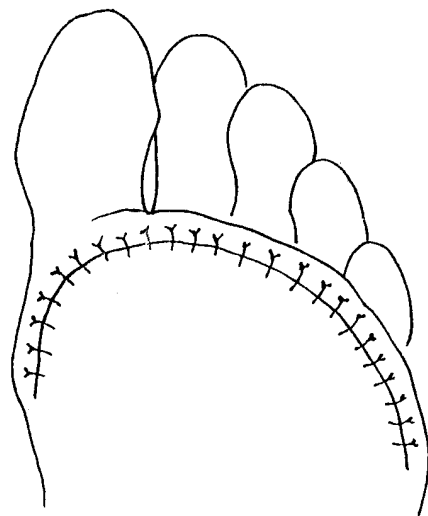


Fig. 2. — Plantar approach for metatarsal head resection.

Table II. — Local postoperative complications of 147 feet, 90 patients

	Dorsal approach (I) Feet	Plantar approach (II) Feet
Wound healing problems		
* Dehiscence	2	0
* Superficial infection	3	1
* Deep infection	1	0
* Wound edge necrosis	2	0
* Uncomplicated	56 (87.5%)	82 (98.7%)
	64 Feet	83 Feet

RESULTS

Local postoperative complications all healed with conservative treatment (table II), except a 68-years-old diabetic woman with a psychiatric history, who died 8 weeks postoperatively because of sepsis and gangrene, probably due to a neglected pressure sore under the plaster.

There were no thromboembolic or neurovascular complications.

Reoperations for better alignment by shortening of one or two metatarsal stumps were performed in 8 feet of group II. A complete realignment was done in one foot of group I. All these reoperations were performed within the first year after the initial procedure, because of recurrent metatarsalgia.

For the follow-up study completed questionnaires of 108 feet of 65 patients were available. There were 5 non-responders, and 20 patients had died. Group I included 28 patients (41 feet) and group II, 37 patients (67 feet). Scores for satisfaction and pain showed no differences for the two groups. With respect to walking ability and footwear improvement after operation, patients in group II had a better score; however with respect to changes in the form of the foot, patients of group I scored better (table III). Minor disabilities such as hammer toes, plantar callosities and (infected) clavi were more frequent in group II (table III).

DISCUSSION

Libscomb (5) stated that the deformities of the forefoot in rheumatoid arthritis are so extensive

and the pain so severe that operation certainly cannot make the condition worse. The good results of the metatarsal head resections in our series, seen as a salvage procedure, seem to confirm his statement. Furthermore the subjective results are reasonably good.

Other techniques such as debasement of the first phalanx, or resection of the first phalanx combined with partial (2, 5) or total metatarsal head resection (1) may give similar results.

In our groups 35% of the operated feet had a broadening of the foot after the operation. In the first 6 weeks postoperatively the plaster cast used in group I should prevent broadening, whereas patients in group II had no such support. The subjective scoring on the form of the foot shows that the plaster cast which is rather uncomfortable for the patient, gives a better result, but this did not result in an equivalent increase in overall satisfaction.

Nowadays in the University Hospital patients receive an elastic forefoot bandage for 6 months to prevent (excessive) broadening of the foot, with promising results of a more convenient size of the forefoot.

The plantar approach offers a better and more direct view of all metatarsal stumps than the dorsal approach. This may permit an easier approach to the metatarsal ends resulting in greater salvage of bone length. If the bone resection is insufficient, recurrent bursitis and pain may occur because of osseous spicae remaining from the metatarsal heads, requiring reoperation.

Furthermore some difficulties may occur in the dorsal approach when the MT-joints are luxated. Traction hooks, used for better exposure, may

Table III. — Follow-up data of 108 feet, 65 patients

	Dorsal approach (I) Feet	Plantar approach (II) Feet
Subjective score		
* Very satisfied	18 (44%)	35 (52%)
* Satisfied	18 (44%)	28 (42%)
* Unsatisfied	5 (12%)	4 (6%)
Pain		
* Never	28 (68%)	45 (67%)
* Walking (long)	8 (20%)	17 (25%)
* Walking (always)	5 (12%)	5 (8%)
* Always	0 (0%)	0 (0%)
Walking distance		
* Increased	21 (52%)	48 (72%)
* Unchanged	17 (41%)	15 (22%)
* Decreased	3 (7%)	4 (6%)
Footwear improvement		
* Yes	11 (27%)	46 (68%)
* No	30 (73%)	21 (32%)
Changes of form of foot		
* Less broad	5 (12%)	13 (19%)
* Unchanged	28 (68%)	24 (36%)
* Broader	8 (20%)	30 (45%)
Minor disabilities at follow-up (as seen by patients)		
* Clavi	2 (5%)	13 (20%)
* Hammertoes	4 (10%)	9 (14%)

damage the skin and subcutaneous tissues, causing wound-healing problems as described.

In comparison to other plantar approaches we think that the over-the-top incision is a more convenient and safer procedure with regard to the neurovascular bundles and soft tissue healing.

Furthermore the wound is situated in a healthier part of the plantar fat pad and in a non-weight-bearing area with low risk of wound-healing problems or pain in the plantar scar.

CONCLUSION

The metatarsal head resection for the deformed painful rheumatic foot has similar long-term subjective scores for satisfaction and pain whether performed via the dorsal or plantar approach.

In our series the dorsal approach showed a higher rate of wound-healing problems in the immediate postoperative period, but less recur-

rence of metatarsalgia in the first year requiring surgical revision.

The authors retain a preference for the plantar approach because of the more convenient, less immobilizing aftertreatment, lower rate of postoperative complications, and the similar outcome of both procedures over time.

REFERENCES

1. Clayton M. L. Surgery of the forefoot in rheumatoid arthritis. *Clin. Orthop.*, 1960, 16, 136.
2. Fowler A. W. A method of forefoot reconstruction. *J. Bone Joint Surg.*, 1959, 41-B, 507.
3. Larmon W. A. Surgical treatment of deformities of rheumatoid arthritis of the forefoot and toes. *Bull. Northwestern Univ. Med. School*, 1951, 25, 39.
4. Levievre J. *Pathologie du pied*. 2nd ed., Masson, Paris, 1961, 737-739.
5. Libscomb P. R., Benson G. M., Sones D. A. Resection of proximal phalanges and metatarsal condyles for deformities of the forefoot due to rheumatoid arthritis. *Clin. Orthop.*, 1972, 82 : 24.

SAMENVATTING

P. J. M. VAN LOON, R. P. ARIES, R. P. KARTHAUS en B. J. J. M. STEENAERT. Metatarsale kopjes resectie bij de gedeformeerde symptomatische rheumavoet. Vergelijking van twee methoden.

De metatarsale kopjes resectie als behandeling van de symptomatische, gedeformeerde rheuma voet werd uitgevoerd bij 83 voeten van 49 patiënten via een gemodificeerde plantaire benadering met functionele nabehandeling, en bij 64 voeten van 41 patiënten via een dorsale benadering, en nabehandeling met onderbeensgips voor 6 weken.

Beide groepen waren vergelijkbaar ten aanzien van leeftijd, geslacht en follow-up.

Honderd zeven-en-veertig voeten (90 patiënten) zijn geopereerd in twee verschillende klinieken, in de periode 1975-1985.

Vijfentwintig patiënten (39 voeten) ontbraken bij de follow-up. De gemiddelde follow-up bedroeg 83,3 maanden (33-136 maanden).

Gegevens werden verzameld via de medische dossiers en via vragenlijsten, opgestuurd naar alle patiënten.

De resultaten in beide groepen waren nagenoeg hetzelfde. Er was echter een hoger aantal wondgenezingsstoornissen bij de dorsale benadering. Bij de plantaire benadering waren meer recidieven van metatarsalgie, waarvoor operatieve correctie nodig was.

RÉSUMÉ

P. J. M. VAN LOON, R. P. ARIES, R. P. KARTHAUS et B. J. J. M. STEENAERT. Résection des têtes métatarsiennes dans le pied rhumatoïde déformé et symptomatique. Comparaison de 2 techniques.

Chez 49 malades, présentant 83 pieds rhumatoïdes, déformés et symptomatiques, la résection des têtes métatarsiennes fut pratiquée par voie plantaire, suivie de rééducation fonctionnelle immédiate. Chez 41 malades, 64 pieds ont été opérés par voie dorsale, intervention suivie d'immobilisation en botte plâtrée pendant 6 semaines. Les 2 groupes étaient similaires quant à l'âge, au sexe et au recul.

Cent-quarante-sept pieds (90 malades) furent opérés dans 2 différentes cliniques, entre 1975 et 1985. Les dossiers sont incomplets pour 25 malades (39 pieds). Le recul moyen est de 43,3 mois (avec des extrêmes de 33 et de 136 mois). Les données furent recueillies dans les dossiers médicaux et par par questionnaires, adressés à tous les patients. Les résultats sont presque semblables dans les 2 groupes. On note un nombre plus important de retards de cicatrisation après intervention par voie dorsale. Après abord plantaire, il y eut plus de récurrences de métatarsalgie, nécessitant parfois une intervention secondaire.