

# FRACTURES AND NONUNIONS OF THE CARPAL SCAPHOID IN CHILDREN

O. FABRE, H. DE BOECK, P. HAENTJENS

**Fractures of the carpal scaphoid in children show some quite remarkable differences with respect to fractures of the carpal scaphoid in adults. A review of the literature shows that fractures in children are more often located in the distal third, are more often incomplete and are usually not displaced. Our experience with 23 fresh fractures of the carpal scaphoid in children confirms these findings of the literature. Nonunion of the carpal scaphoid is exceedingly rare in children. When reviewing the literature we could find only 29 published cases of nonunion of the carpal scaphoid in children. In most articles describing carpal scaphoid nonunion in children, bone grafting is recommended as the treatment of choice. We report two children with a nonunion of the carpal scaphoid treated successfully by cast immobilization. Therefore, we propose that a child with a nonunion of the carpal scaphoid bone that has never been immobilized previously should be treated by cast immobilization. Surgery should be considered only if there is no indication of healing after 3 months of immobilization.**

**Keywords :** scaphoid bone ; fracture ; nonunion ; children.

**Mots-clés :** scaphoïde carpien ; fracture ; pseudarthrose ; enfant.

---

## INTRODUCTION

Fractures of the carpal scaphoid in children differ from fractures of the carpal scaphoid in adults. In children these fractures are more often incomplete, undisplaced and located in the distal third (3, 19). These fractures usually heal uneventfully after

conservative treatment, and, consequently, nonunion of the carpal scaphoid in childhood is very rare (3, 19). For the treatment of a nonunion of the carpal scaphoid in childhood most authors recommend bone grafting as the treatment of choice (4, 14, 20). Although in adults the treatment of a scaphoid nonunion is indeed best done by means of bone grafting, our experience suggests that in children conservative treatment might be the first choice.

The purpose of this paper is to report our experience with 23 fresh fractures of the carpal scaphoid in children, and to report the history of two children with a nonunion of the carpal scaphoid treated successfully by cast immobilization.

## PATIENTS AND METHODS

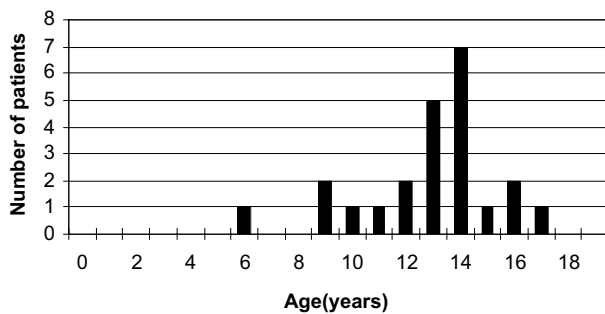
**Fractures :** From 1977 through 1997, 23 children with a fresh carpal scaphoid fracture were treated in the Department of Pediatric Orthopedics and Trauma at the University Hospital of the Vrije Universiteit Brussel. The mean age at the time of injury was 12.9 years (fig. 1). There were 7 girls and 16 boys.

All 23 children had open physal growth plates at the time of injury, and they all had a closed fracture. Treatment in all children was conservative and consisted

---

Department of Pediatric Orthopedic Surgery, University Hospital of the Vrije Universiteit Brussel.

Correspondence and reprints : O. Fabre, Department of Orthopedics and Trauma, AZ-VUB, Laarbeeklaan 101, B-1090 Brussels, Belgium. E-mail: Olivier.Fabre@az.vub.ac.be.



**Fig. 1.** — Age distribution of 23 children with a carpal scaphoid fracture.

of a period of immobilization in a thumb-spica above-elbow cast. The cast was removed after clinical and radiographic healing were obtained.

**Nonunions :** During the same period 2 children (one 8.5-year-old girl and one 10-year-old boy) were referred to us because of persistent wrist pain. Both children sustained an injury, respectively 7 months and 11 months before presentation. In both children, the injury was first considered as a simple sprain, and therefore no xrays were taken. In the ensuing months, there was no other trauma but the pain persisted. Physical examination showed pain and tenderness in the anatomical snuffbox. Radiographs showed nonunion of the carpal scaphoid with sclerosis and cyst formation at the fracture site. Treatment in both children was conservative.

## RESULTS

**Fractures :** Initially, four fractures were missed in the emergency room, but were diagnosed in the outpatient clinic within 2 days of the initial injury. All other fractures were correctly diagnosed at first presentation. In all cases the mechanism of injury was a fall on the outstretched hand. Displacement of the fracture was less than one mm in all patients. There were 5 avulsion fractures of the distal pole, one fracture of the proximal pole and all the other 17 fractures were located in the middle and distal third of the scaphoid.

The mean time of immobilization was 6.9 weeks (range 2 to 12 weeks). The distal avulsion fractures usually needed the shortest period of immobilization (mean : 5 weeks ; range 2 to 9 weeks).

The mean follow-up time was 25.7 months (range 1 to 120 months). At final evaluation all fractures were healed, and all patients were free of complaints and had full range of motion of the elbow, wrist and finger joints.

**Nonunions :** In the 8.5-year-old girl, a long-arm cast with the elbow flexed at 90° and including the thumb was applied for 2 months and was then replaced by a short-arm cast for another 6 weeks. In the 10-year-old boy the period of immobilization was 6 weeks.

At final evaluation both children had no complaints and had painless, full range of motion of the elbow, wrist and finger joints. xrays confirmed healing without signs of carpal instability.

## DISCUSSION

Our experience with 23 fresh fractures of the carpal scaphoid in children confirms the findings reported in the literature. Fractures of the carpal scaphoid in children are often incomplete and are usually not displaced. Nonunion may occur in adequately treated cases of scaphoid fracture in children, but is very rare. A review of the literature, summarized in table I, shows that of the 371 children whose fresh scaphoid fracture was treated by cast immobilization, only three (0.8%) developed a nonunion.(3, 7, 8, 10, 15, 19, 20).

It is not surprising, therefore, that a review of the literature yields only 29 published cases of nonunion of the carpal scaphoid in children (table II). In each case, the differential diagnosis with a bipartite scaphoid must be made by means of clinical history and imaging techniques (5).

Among those children with a nonunion of the carpal scaphoid, two main groups can be distinguished :

- In a first group are those children whose fracture is correctly diagnosed and to whom a plaster is applied, but for several reasons this cast is removed too soon.
- In a second group are those children in whom — as in our two patients — the injury was neglected, no xrays were taken at the time of injury and consequently the fracture was not recognized.

Table I. — Nonunion after scaphoid fracture in children, as reported in the literature

Author (reference)	Country	Year	Fractures	Nonunions
Müssbichler (15)	Sweden	1961	100	2 (2%)
Grundy (8)	England	1969	8	0
Vahvanen and Westerlund (20)	Finland	1980	108	0
Christodoulou and Colton (3)	England	1986	77	1 (1.3%)
Langhoff and Andersen (10)	Denmark	1988	34	0
Stanciu and Dumont (19)	Canada	1994	21	0
Current series	Belgium	2001	23	0
Total			371	3 (0.8%)

Table II. — Treatment of nonunion of the carpal scaphoid in children, as reported in the literature

Author (reference)	Year	Nonunions	Treatment
Müssbichler (15)	1961	2	N.A. *
Southcott (18)	1977	8	Autograft
Maxted (13)	1982	2	Bone grafting
Pick (17)	1983	1	Surgery **
Onuba (16)	1983	2	Screw fixation
Borde (1)	1984	1	Surgery **
Greene (7)	1984	2	Bone grafting
Christodoulou (3)	1986	1	Bone grafting
Larson (11)	1987	1	Surgery **
Herbert (9)	1990	2	K-wire fixation
Caputo (2)	1995	1	Bone grafting
Mintzer (14)	1999	5	Bone grafting and Herbert screw
Godley (6)	1997	1	Pulsed electromagnetic field
Current series	2001	2	Plaster cast

\* N.A. : data not available.

\*\* Type of surgery not specified.

The vast majority of authors recommend surgery for the treatment of nonunion of the carpal scaphoid in children (table II). Quite remarkably, all these authors refer to the paper published in 1977 by Southcot and Rosman (18) who recommend a Matti-Russe procedure for the treatment of nonunion of the carpal scaphoid in children. Lichtman, however, recommends either surgery or conservative treatment (12). In agreement with this report, our experience in two children confirms that a nonunion of the carpal scaphoid can be treated successfully by cast immobilization.

## CONCLUSIONS

The diagnosis of a carpal scaphoid fracture in a child depends on the increased awareness of the possibility of scaphoid fractures in children. Whenever a child complains of pain in the anatomical snuffbox, xrays of the wrist and carpal scaphoid should be performed. These fractures have a very good prognosis after conservative treatment.

We also recommend cast immobilization for the treatment of scaphoid nonunion in children. Surgery should be considered only if there is no

clinical or radiographic indication of healing after a period of immobilization of at least 3 months. Our policy is based on two cases of nonunion of the carpal scaphoid in children treated successfully in our department. Furthermore, children are less prone to joint stiffness after prolonged immobilization.

## REFERENCES

1. Borde J., Lefort J. In : *Traité de chirurgie de la main*. Tubiana R., ed. Masson, Paris, vol. 2, 1984, pp. 722-740.
2. Caputo A. E., Watson H. K., Nissen C. Scaphoid nonunion in a child : A case report. *J. Hand. Surg.*, 1995, 20-A, 243-245.
3. Christodoulou A. G., Colton G. L. Scaphoid fractures in children. *J. Pediatr. Orthop.*, 1986, 6, 37-39.
4. De Boeck H., Van Wellen P., Haentjens P. Nonunion of a carpal scaphoid fracture in a child. *J. Orthop. Trauma*, 1991, 5, 370-372.
5. Dubrana F., Le Nen D., Hu W., Poueyron Y., Pazart F., Lefevre C. Scaphoïde carpien bipartite bilatéral : Affection congénitale ou pseudarthrose méconnue? Mise au point à propos d'un cas clinique. *Rev. Chir. Orthop.*, 1999, 85, 503-506.
6. Godley D. R. Nonunited carpal scaphoid fracture in a child : Treatment with pulsed electromagnetic field stimulation. *Orthopedics*, 1997, 20, 718-719.
7. Greene M. H. Scaphoid fractures in children. *J. Hand Surg.*, 1984, 9-A, 536-541.
8. Grundy M. Fractures of the carpal scaphoid in children. A series of eight cases. *Br. J. Surg.*, 1969, 56, 523-524.
9. Herbert T. The fractured scaphoid. Quality Medical Publishing, Inc., 1990, pp. 163-172.
10. Langhoff O., Andersen J. L. Consequences of late immobilization of scaphoid fractures. *J. Bone Joint Surg.*, 1988, 13-B, 77-79.
11. Larson B., Light T. R., Ogden J. A. Fracture and ischemic necrosis of the immature scaphoid. *J. Hand Surg.*, 1987, 12-A, 122-127.
12. Lichtman M. D. (ed.), *The Wrist and its Disorders*, Philadelphia, WB Saunders Company, 1997, pp. 234-268
13. Maxted M. J., Owen R. Two cases of non-union of carpal scaphoid fractures in children. *Injury*, 1982, 13, 441-443.
14. Mintzer C. M., Waters P. M. Surgical treatment of pediatric scaphoid fracture nonunions. *J. Pediatr. Orthop.*, 1999, 19, 136-139.
15. Müssbichler M. Injury of the carpal scaphoid in children. *Acta Radiol.*, 1961, 361-368.
16. Onuba O., Ireland J. Two cases of non-union of fractures of the scaphoid in children. *Injury*, 1983, 15, 109-112.
17. Pick R. Y., Segal D. Carpal scaphoid fracture and non-union in an eight-year-old child. Report of a case. *J. Bone Joint Surg.*, 1983, 65-A, 1188-1189.
18. Southcot R., Rosman M. A. Non-union of carpal scaphoid fractures in children. *J. Bone Joint Surg.*, 1977, 59-B, 20-23.
19. Stanciu C., Dumont A. Changing patterns of scaphoid fractures in adolescents. *Can. J. Surg.*, 1994, 37, 214-216.
20. Vahvanen W., Westerlund M. Fracture of the carpal scaphoid in children. *Acta Orthop. Scand.*, 1980, 51, 909-913.

## SAMENVATTING

*O. FABRE, H. DE BOECK, P. HAENTJENS. Fracturen en pseudartrosen van het os scaphoideum bij kinderen.*

Fracturen van het os scaphoideum bij kinderen tonen meerdere verschillen met deze bij volwassenen. De literatuur toont, dat bij kinderen de fracturen meer distaal gelocaliseerd zijn en minder verplaatst zijn. Onze ervaring bij 23 verse fracturen van het os scaphoideum bevestigt deze bevindingen. Een pseudartrose van het os scaphoideum is uiterst zeldzaam bij kinderen. In de literatuur vonden we slechts 29 gevallen terug. De meerderheid van de auteurs raadt een heelkundige behandeling aan voor deze pseudartrosen. Wij beschrijven twee gevallen van pseudartrose van het os scaphoideum bij kinderen die met succes behandeld werden met gips-immobilisatie. Daarom stellen wij voor om, eerst een conservatieve behandeling te proberen alvorens over te gaan tot heelkunde. Een heelkundige behandeling van een pseudartrose van het os scaphoideum bij een kind zou slechts moeten overwogen worden als er na 3 maanden gipsimmobilisatie nog geen teken is van consolidatie.

## RÉSUMÉ

*O. FABRE, H. DE BOECK, P. HAENTJENS. Fractures et pseudarthroses du scaphoïde carpien chez l'enfant.*

Les fractures du scaphoïde carpien chez l'enfant présentent plusieurs différences par rapport aux fractures de l'adulte. Une revue de la littérature montre que, chez l'enfant, les fractures sont plus souvent localisées au niveau de la partie distale ; en outre, elles sont presque jamais déplacées. Notre expérience de 23 fractures fraîches confirme ces données.

La pseudarthrose du scaphoïde carpien est extrêmement rare chez l'enfant. Une revue de la littérature en révèle 29 cas. La plupart des auteurs recommandent une inter-

vention chirurgicale avec greffe osseuse comme traitement de choix ; nous rapportons cependant deux cas de pseudarthrose du scaphoïde carpien chez l'enfant, traités avec succès par immobilisation plâtrée. Dès lors, nous suggérons qu' une pseudarthrose du scaphoïde carpien

chez l'enfant devrait d'abord être traitée par immobilisation plâtrée avant d'envisager une intervention chirurgicale. Celle-ci ne devrait être envisagée qu'en l'absence de signes de consolidation après trois mois d'immobilisation plâtrée.