

## CASE REPORT

# BRACHIAL ARTERY INJURY IN CLOSED POSTERIOR ELBOW DISLOCATION CASE REPORT

P. REYNDERS, P. BROOS, D. STOFFELEN

**The authors describe a case with a closed posterior elbow dislocation associated with a distal radial fracture and complete transection of the brachial artery. The patient had a pulseless distal upper extremity and immediate gross swelling of the elbow and forearm. As closed reduction was not possible, open reduction had to be performed through an antero-medial approach to the elbow.**

**End-to-end suture of the brachial artery was successful. After fasciotomy and internal fixation of the distal radial fracture, the elbow was stabilized with an external fixator spanning the elbow joint. After two years, despite good function of the elbow, restoration of the hand function is not optimal owing to persistent motor deficit of the ulnar nerve.**

**Keywords :** elbow ; dislocation ; arterial injury.

**Mots-clés :** coude ; luxation ; lésion artérielle.

---

### INTRODUCTION

Although elbow dislocation occurs frequently, concomitant brachial artery injury is rare. Ninety percent of elbow dislocations are posterior or posterolateral (12). Adequate treatment of this injury includes prompt reduction of the dislocation, vascular repair and bridging fixation of the elbow with an external fixator. Management of this combined injury is discussed, and the literature is reviewed.

### CASE REPORT

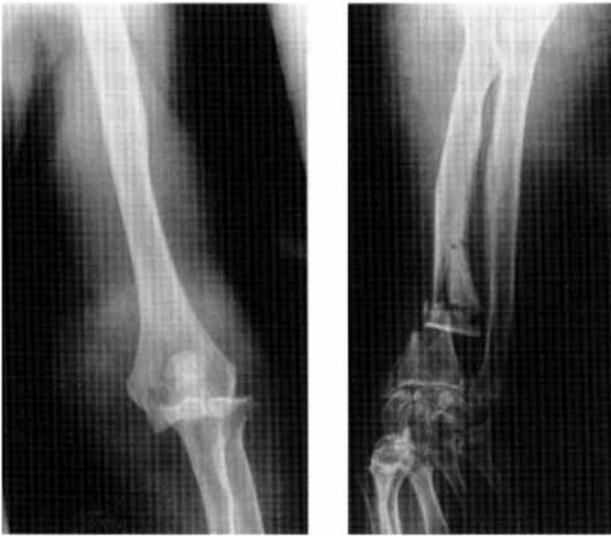An 84-year-old female with a dominant right hand fell while descending stairs and landed on her

outstretched left arm. She arrived at the emergency room of our hospital one hour later with pain, acute gross swelling and numbness of the left arm. Owing to the combination of swelling and obesity, no apparent deformity of the elbow was noticed. Although finger movement was possible, the mobility was restricted because of the excruciating pain and numbness of the whole arm. No radial pulse was detectable. Capillary refill was present. Radiographic examination revealed a posterior elbow dislocation associated with a comminuted wrist fracture (fig. 1). Under heavy sedation several attempts to reduce the elbow were unsuccessful. The patient was transferred to the operating room and a tourniquet put on, but not inflated. The elbow was approached through a long anteromedial incision with the patient in a supine position (fig. 2). There was brisk bleeding from the proximal stump of the ruptured brachialis artery, one centimeter proximal to the medial humeral condyle. The median nerve was stretched without any visible damage. The brachialis muscle and anterior joint capsule were lacerated. In addition, the ulnar collateral ligament was ruptured, creating an unstable joint. Through the anterior incision all the compartments of the forearm were decompressed, and plating of the distal radius was performed. The injured artery was debrided and sutured end-to-end (fig. 3). The

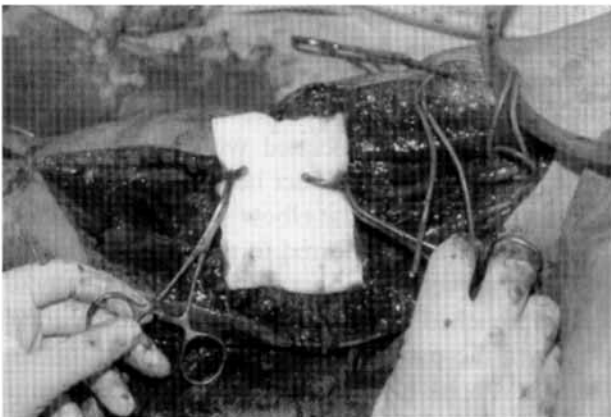
---

Department of Trauma, University Hospital K.U.Leuven.

Correspondence and reprints : P. Reynders, Department of Trauma, University Hospital K.U.Leuven, Herestraat 49, 3000 Leuven, Belgium.



**Fig. 1.** — *a.* Radiograph of the dislocated elbow.  
*b.* Radiograph of the comminuted distal radius and ulna fracture.

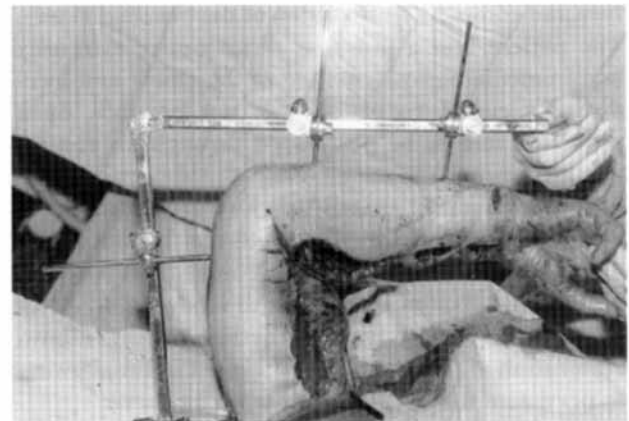


**Fig. 2.** — View of the ruptured brachial artery.

reduced dislocation was unstable, and a spanning external fixator was used to stabilize the joint in 90° flexion (fig. 4). Only the arterial repair and the median nerve were covered with soft tissue, leaving the rest of the incision open. A delayed primary closure was performed on the third postoperative day. After three weeks the external fixator was removed, and active mobilization of the elbow, wrist and fingers was begun. During the first four weeks, mobility of the fingers and wrist was weak. The radial pulse was good, there was complete

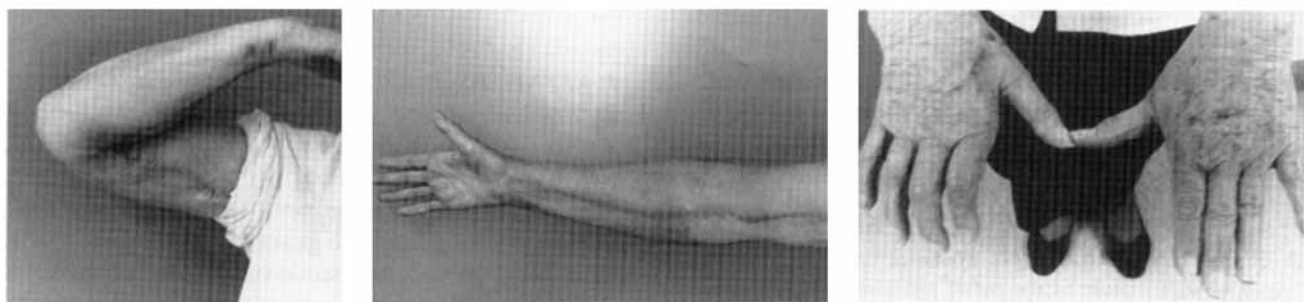


**Fig. 3.** — End-to-end suturing of the brachial artery.

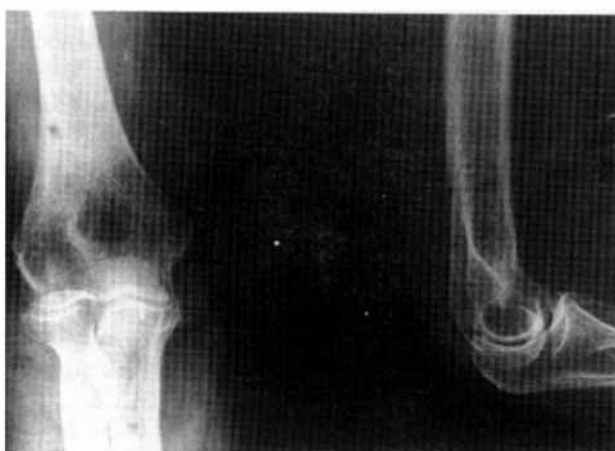

**Fig. 4.** — Situation after fasciotomy and partial closure of the skin incision. An external fixator spans the elbow joint in 90° of flexion.

motor and sensory deficit of the ulnar nerve which did not resolve completely. Finger and wrist motion improved steadily, but some residual stiffness of the metacarpophalangeal joints persisted after 25 months of follow-up. Elbow motion then revealed 110° of flexion and -25° of extension. Pronation and supination were restricted; supination was -40° and pronation -10°. The elbow felt stable, and the patient complained of no elbow pain (fig. 5). There was no myositis ossificans visible on xray (fig. 6). It took seven months for the bony healing of the distal radius to occur.



**Fig. 5.** — *a,b,c.* Functional result of the elbow and fingers at 25 months.  
Elbow function is normal. Clawing of the hand due to ulnar palsy.



**Fig. 6.** — Radiographs of the elbow at 25 months.

## DISCUSSION

In the older literature on arterial injuries with elbow dislocations, the advocated treatment has been ligation of the brachial artery. The rationale for doing so was the allegedly rich anastomotic circulation around the elbow and the very few reports of forearm gangrene after ligation of the brachial artery (8, 3, 2, 13, 11). Of great interest is the cadaveric study performed by Louis *et al.* (6). They created a posterior elbow dislocation on 14 upper extremities. In 13 of the 14 limbs studied, the anastomosis between the inferior ulnar collateral artery and the anterior ulnar recurrent artery was disrupted, indicating that this injury can produce concomitant injury to some of the collateral blood supply around the elbow. Because of our patient's age we suspected a diminished collateral circulation

around the elbow, so we did not take the risk of ligation of the brachial artery. Although most authors recommend arteriography, not only to substantiate the clinical diagnosis, but also to define the anatomical location of the lesion (12, 10, 4, 7), we did not perform arteriography because of the rapid ongoing swelling of the elbow and forearm. This together with an unreducible posterior elbow dislocation made anterior exploration of the cubital fossa an urgent necessity. Of interest is the observation of the irreducibility of the elbow. This can be explained by the huge hematoma around the elbow preventing the reduction.

In closed elbow dislocation with a concomitant arterial lesion, direct suturing of the arterial laceration is often possible (14, 15). After high-energy trauma the dislocation may be associated with segmental laceration of the brachial artery, making interposition of a vein graft desirable.

In these cases it is of utmost importance to perform a fasciotomy of all the compartments in the forearm to prevent a compartment syndrome after reperfusion. An important issue is stabilization of the joint. Most authors agree that in acute dislocation of the elbow ligamentous repair is futile (1, 5, 9). Because of the importance of wound care we advocate the use of an external fixator which spans the joint in 90° flexion for six weeks. It was amazing to see the nearly perfect recovery of mobility of the joint after removal of the fixator. In our case the only negative outcome was the ulnar palsy which had not completely resolved after two years. With her sedentary life style this handicap was not of great importance to the patient.

## REFERENCES

1. Baulot E., Giroux E. A., Ciry-Gomez M., Grammont P. M. Brachialis artery rupture following closed posterior elbow dislocation. *Ann. Chir. Main*, 1997, 16, 258-262.
2. Debakey M. E., Simeone F. A. Battle injuries of the arteries in World War II. An analysis of 2471 cases. *Ann. Surg.*, 1946, 123, 534-542.
3. Eliason E. L., Brown R. B. Posterior dislocation at the elbow with rupture of the radial and ulnar arteries. *Ann. Surg.*, 1937, 106, 1111-1114.
4. Hoffmann K. E. III, Moneim M. S., Omer G. E., Ball W. S. Brachial artery disruption following closed posterior elbow dislocation in a child-assessment with intravenous digital angiography. *Clin. Orthop.*, 1984, 184, 145-149.
5. Josefsson P. O., Johnell O., Gentz C. F., Wendeberg B. Surgical versus non-surgical treatment of ligamentous injuries following dislocation of the elbow joint. A prospective randomized study. *J. Bone Joint Surg.*, 1987, 69-A, 605-608.
6. Louis D. S., Ricciardi J.E., Spengler D. Arterial injury : A complication of posterior elbow dislocation. *J. Bone Joint Surg.*, 1974, 56 A, 1631-1635.
7. Mains D. B., Freeark R. J. Report on compound dislocation of the elbow with entrapment of the brachial artery. *Clin. Orthop.*, 1975, 106, 180-185.
8. Marnham R. Dislocation of the elbow with rupture of the brachial artery. *Br. J. Surg.*, 1934, 22, 181-185.
9. O'Driscoll S. W. M. Elbow instability. *Acta Orthop. Belg.*, 1999, 65, 404-413.
10. Rubens M. K., Aulicino P. L. Open elbow dislocation with brachial artery disruption . Case report and review of the literature. *Orthopedics*, 1986, 9, 539-542.
11. Sadat-Ali M. Brachial artery injury in closed elbow dislocation. Case report and review of literature. *Arch. Orthop. Trauma Surg.*, 1990, 109, 288-290.
12. Seidman G. D., Koerner P. A. Brachial artery rupture associated with closed posterior elbow dislocation : A case report and review of the literature. *J. Trauma*, 1995, 38, 318-321.
13. Sherrill J. B. Direct suture of the brachial artery following rupture, results of traumatism. *Ann. Surg.*, 1913, 58, 534-536.
14. Slowik G. M., Fitzimmons M., Rayhack J. M. Closed elbow dislocation and brachial artery damage. *J. Orthop. Trauma*, 1993, 7, 558-561.
15. Sturm J. T., Rothenberger D. A., Strate R. G. Brachial artery disruption following closed elbow dislocation. *J. Trauma*, 1978, 18, 364-366.

## SAMENVATTING

*P. REYNDERS, P. BROOS, D. STOFFELEN. Letsel van de brachiale arterie in gesloten posterieure elleboog dislocaties. Gevalbespreking.*

De auteurs beschrijven het geval van een gesloten posterieure elleboogdislocatie geassocieerd met een distale radiusbreuk en volledige sectie van de arteria brachialis. De patiënt vertoonde geen distale pols in het bovenste lidmaat. Vanwege de ernstige zwelling was een gesloten reductie niet mogelijk. Via een anteromediale toegang werd de elleboog gereduceerd.

Een termino-terminale anastomose van de arteria brachialis werd met succes uitgevoerd. Na fasciotomie van de voorarm en inwendige fixatie van de distale radiusfractuur, werd de elleboog met een externe fixator gestabiliseerd.

Na twee jaar, ondanks een goed functioneel resultaat van de elleboog, is de restauratie van de handfunctie suboptimaal omwille van een motorisch persisterend deficit van de nervus ulnaris.

## RÉSUMÉ

*P. REYNDERS, P. BROOS, D. STOFFELEN. Lésion traumatique de l'artère brachiale associée à une luxation du coude. Présentation d'un cas.*

Les auteurs présentent un cas de luxation postérieure fermée du coude associée à une fracture du radius et une section complète de l'artère brachiale. La patiente n'avait plus de pouls distal au membre supérieur et le coude et l'avant-bras étaient fort oedématisés. Comme une réduction fermée n'était pas possible, il fut nécessaire d'effectuer une réduction ouverte par abord antéro-médial du coude. Une suture termino-terminale de l'artère brachiale a été faite avec succès. Après fasciotomie et ostéosynthèse de la fracture du radius distal, le coude a été stabilisé par un fixateur externe pontant l'articulation. Avec un recul de deux ans, la fonction du coude est bonne, mais la fonction de la main est imparfaite à cause d'un déficit moteur persistant du nerf ulnaire.