



Anastomosis between the median and ulnar nerve in the forearm An anatomic study and literature review

Konstantin J. KAZAKOS, Anastasios SMYRNIS, Konstantin C. XARCHAS, Alexandra DIMITRAKOPOULOU,
Dionysios-Alexandros VERETTAS

From the Orthopaedic Department, Democritus University of Thrace, Alexandroupolis, Greece

Anastomosis between the median and ulnar nerve in the forearm has been shown to be of clinical significance. We aimed to determine the presence of median to ulnar nerve communications in the forearm of the Greek population by anatomical studies. At the same time we defined the types and patterns of the anastomoses found and compared them to those reported in similar studies that were retrieved after a wide review of the literature. One hundred and sixty three forearms from 100 cadavers (53 males, 47 females, 25-91 years old) were carefully dissected to observe median and ulnar nerve communication. The anastomosis was found in 10 cadavers ; it was bilateral in 4 and unilateral in 6, on the right side in four and on the left side in two. It occurred in 7 of the 53 male cadavers (14%) and in 3 of the 47 females (6,5%). Overall, the anastomosis was found in 14 of the 163 forearms (8,6%). No case of ulnar to median nerve anastomosis in the forearm was found in anatomical examination.

INTRODUCTION

Anastomoses between the median and ulnar nerve are known as the most common form of "anomalous" innervation. These anastomoses in the forearm and hand provide variations in the innervation of the intrinsic hand muscles, as proved by anatomical and nerve conduction studies (11, 12). Such anastomoses have been reported in the upper part of the forearm, rarely in the distal forearm (23),

and finally in the palm between the recurrent branch of the median and the deep branch of the ulnar nerve (12).

Martin (13) was the first to report such an anastomosis in 1763. He described a branch between the median and ulnar nerves that "sometimes runs under the pronator teres muscle". He also described a connection between median and ulnar nerves in the palm, the "arcus volaris nervorum". Martin made no comment on the content of these connecting branches, whether they were motor or sensory. He did not speculate on the final destination of their fibers. Gruber (6) was apparently the next to mention these findings, in 1870. He dissected 212 forearms and found a connection between median and ulnar nerves in 38. The nerve branches generally coursed from the median nerve proximally to the ulnar nerve distally. Gruber never

-
- Konstantin J. Kazakos, MD, Assistant Professor.
 - Anastasios Smyrnis, MD, Orthopaedic Surgeon.
 - Konstantin C. Xarchas, MD, Lecturer.
 - Alexandra Dimitrakopoulou, MD, Orthopaedic Resident.
 - Dionysios-Alexandros Verettas, MD, Associate Professor.

Orthopaedic Department, Democritus University of Thrace, Alexandroupolis, Greece.

Correspondence : Konstantin C. Xarchas, Democritus University of Thrace, 6 I. Kaviri rd, 68100 Alexandroupolis, Greece.
E-mail : drkcxr@yahoo.com.

© 2005, Acta Orthopædica Belgica.

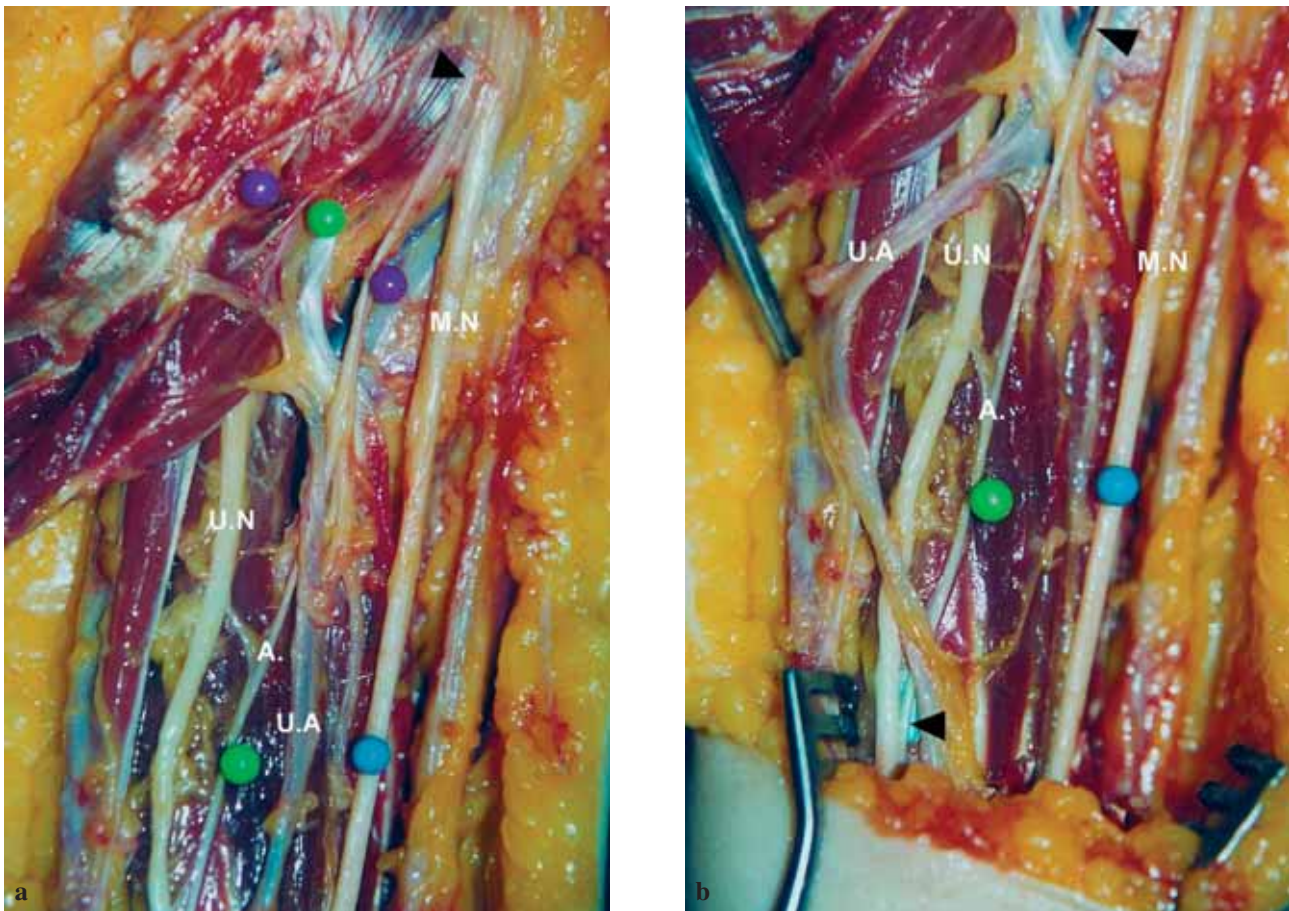


Fig. 1a and b. — Anastomosis (arrows) between the two nerves arising from the median nerve itself (Type II). UA : Ulnar artery, MN : Median nerve, A : Anastomosis, UN : Ulnar nerve.

described a branch coursing from the ulnar nerve proximally to the median nerve distally. This anastomosis is referred to as the Martin – Gruber anastomosis (MGA). It involves axons leaving either the main trunk of the median nerve or the anterior interosseous nerve, crossing through the forearm to join the main trunk of the ulnar nerve and ultimately innervating the intrinsic hand muscles. This variation has been reported to occur in as many as 15-31% of subjects (12, 29). Most often the anomalous axons innervate the first dorsal interosseous muscle and less often the hypothenar and thenar muscles (8). Its reported incidence differs between physiologic and anatomic studies. In the former it has been described as occurring in 5-40% of cases (12, 8, 4, 27) whereas anatomic studies report a

narrower range of incidence between 10% and 30.6% (6, 9, 14, 21, 24).

These anastomoses may cause confusion in the diagnosis of conditions affecting the nerve supply to the intrinsic muscles of the hand. The crossing axons may innervate intrinsic muscles supplied by the ulnar nerve, the median nerve or both.

Table I. — Distribution of the anastomoses between the median and ulnar nerve in the forearm, related to sex and side

	Right	Left
Male (n = 7)	7	3
Female (n = 3)	1	3
Total (n = 10)	8	6

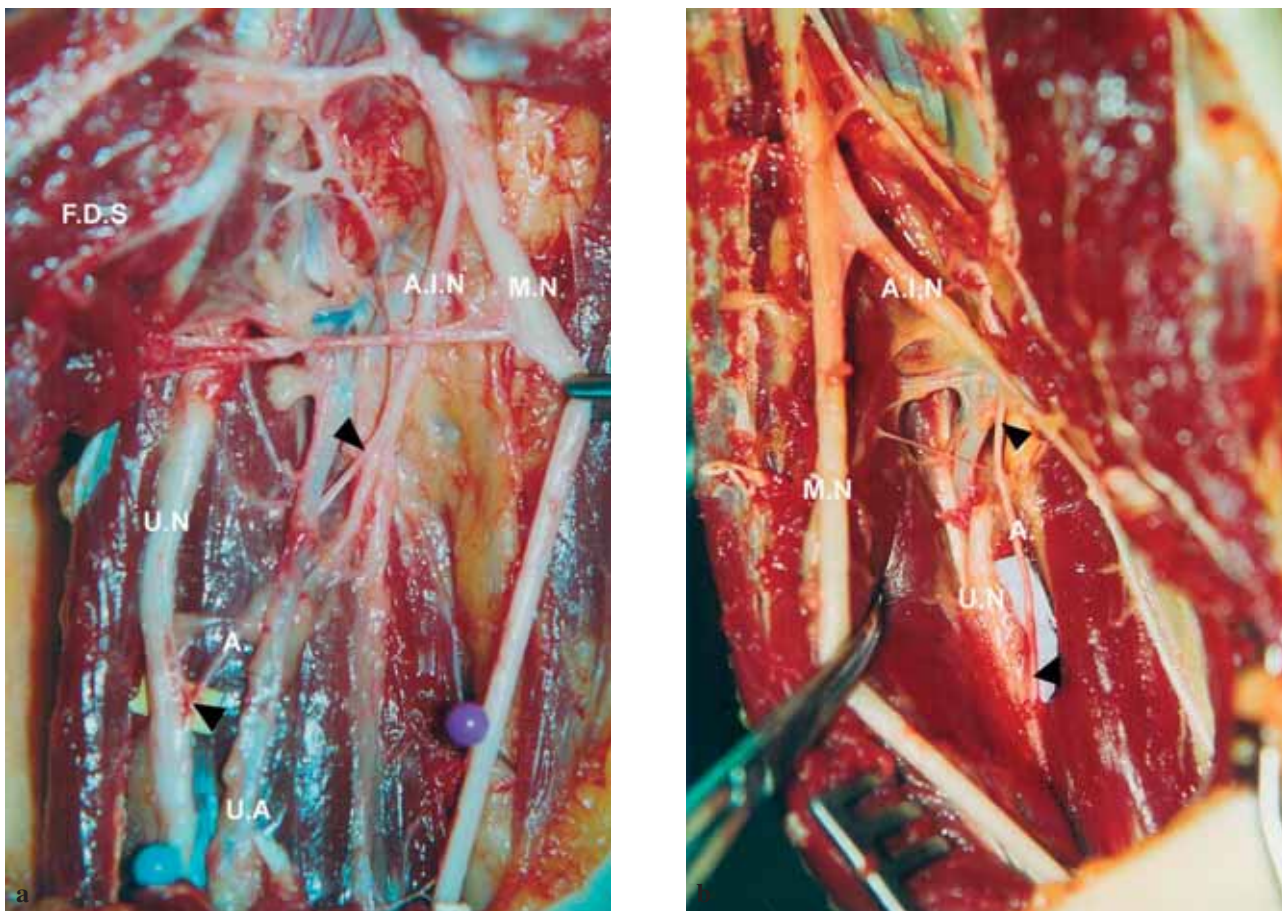


Fig. 2a and b. — Anastomosis (arrows) between the two nerves arising from the anterior interosseous nerve (Type III). UA : Ulnar artery, MN : Median nerve, A : Anastomosis, UN : Ulnar nerve, AIN : Anterior interosseous nerve, FDS : Flexor digitorum superficialis muscles.

Depending on the level of the nerve injury, an increased or decreased motor deficit of the intrinsic hand muscles can be detected. The knowledge of these anastomoses and the resulting anomalous innervation patterns is of major importance for assessment of traumatic or entrapment lesions of the median and ulnar nerve (11, 28).

The purpose of our research was to determine the incidence and also the types of this anastomosis in the Greek population and compare our results to those of similar previous studies. The findings and literature review are presented, to guide the hand surgeon when dealing with forearms with a possible anastomosis.

MATERIAL AND METHODS

One hundred fresh frozen cadavers were dissected in the morgue of Athens during a time period of three years. From these, 53 belonged to males and 47 to females. Sixty-three cadavers (30 male and 33 female) were studied bilaterally and 37 (23 male and 14 female) unilaterally. In total, 163 forearms were dissected. The age of cadavers ranged from 25 to 91 years.

An 'S' shaped incision was carried out, covering the whole anterior surface of the forearm. The superficial fascia was opened and the flexor carpi ulnaris muscle and tendon mobilised to give full exposure of the ulnar artery and ulnar nerve. The branches of the ulnar nerve in the forearm were dissected and all possible anasto-

moses between median and ulnar nerves were documented. The level at which the connections joined the median and ulnar nerves was measured using the medial epicondyle of the humerus as reference (point 0). The research was made with the use of magnifying glasses (4 ×).

Statistical comparisons were performed in the department of statistics in the National School of Public Health of Athens using the chi-squared test. $P < 0.05$ was regarded as statistically significant.

RESULTS

Anastomoses between the median and ulnar nerve were found in 10 out of 100 samples of cadavers, which were studied. It occurred in 7 of the 53 male cadavers (3 bilateral and 4 only in the right forearm) and in 3 of the 47 female cadavers (1 bilateral and 2 only in the left forearm). Therefore, the anastomosis between the two nerves was found in 14 of the 163 forearms, which were dissected (table I). The incidence in the male forearms was 14% and 6.5% in the female forearms. These anastomoses were classified into three types depending on the level of origin of the anastomosis from the median nerve. Type I originates from the branch of the median nerve to the superficial forearm flexor muscles, Type II from the median nerve itself (fig 1) and Type III from the anterior interosseous nerve (fig 2). Type I occurred in one case ($n = 1-7\%$), type II occurred in one case ($n = 1-7\%$) and type III occurred in 12 cases ($n = 12-87\%$) and the branch passed medially to join the ulnar nerve in either its upper or middle one-third.

The average length of the anastomosis was 6.4 cm. Its origin was on average 6.8 cm distal to the medial epicondyle, and its connection to the ulnar nerve was on average 11.0 cm distal to the medial epicondyle. The anastomosis joined the ulnar nerve as a single branch in twelve cases and split into two branches in two cases. The superior branch had a recurrent course and the inferior one ran downwards. Anastomoses between ulnar nerve proximally to the median nerve distally were not found out, nor were anastomoses between these nerves and the radial nerve.

With regard to the analysis of frequency the following were found : a) Cross – correlation between

sex and presence or absence of the anastomosis in the right forearm according to the Pearson test, gave the following data : $X^2 = 0.11$ and $p = 0.73$; b) the same cross – correlation for the left forearm gave the following values : $X^2 = 4.27$ and $p = 0.038$ (table I). This confirms that absence of the anastomosis in the left forearm is more rare in females than in males, or else that the anastomosis in the left forearm is 1.2 times more frequent in females than in males.

DISCUSSION

Anastomoses between median and ulnar nerves in the forearm are of phylogenetic significance (2). In many mammals and frequently in primates there are similar connections between the median and ulnar nerve at or below the elbow. Anastomoses could be remnants of the common ventral nerve trunk innervating flexor muscles in the upper extremity, which is noted in the early stages of evolution. Anastomoses occur frequently in humans and are therefore considered a variation rather than an anomaly.

It has been estimated that in the forearms of 15% to 31% of individuals, motor axons descend from the median nerve, crossing to the ulnar nerve, and ultimately innervating intrinsic hand muscles which are normally supplied by the ulnar nerve (12, 29). This anastomosis gives rise to changes in motor conduction studies, identifying its presence. When this anastomosis exists in a patient with carpal tunnel syndrome, it may result in unusual findings in evoked muscle potentials (10).

There is no consensus in the literature about the classification of anastomosis between the two nerves. Numerous classifications have been proposed by Nakashima (14), Hirasawa (9), Thomson (25), Shu *et al* (21), Srinivasan and Rhodes (22) and Rodriguez-Niedenfuhr *et al* (17) ; their classifications were based on anatomical dissections. Uchida and Sugioka (26), Oh *et al* (15) and Kimura *et al* (11) proposed classifications based on electrophysiological examinations and Shu (21) proposed another classification based on histological examinations. A summary of these classification schemes is shown in table II.

Table II. — Classifications of anastomosis between the median and ulnar nerves. (Abbreviation : MN : median nerve, UN : ulnar nerve, AIN : anterior interosseous nerve, TM : thenar muscles, HM : hypothenar muscles, FDP : flexor digitorum profundus muscle, FDI : first dorsal interosseous)

Anastomosis between	Hirasawa (10)	Thomson (17)	Srinivasan (18)	Nakashima (11)	Rodriguez (19,22)	Shu (12)	Uchida (20) Oh (21) Kimura (1)
AIN and UN	Oblique anastomosis	Class I	Type I,II,VI	Type Ia	Pattern I (Type Ic) Pattern II	Type I	
MN and UN	Oblique anastomosis	Class II	Type III	Type Ib	Pattern I (Type Ia, Ib)	Type II	
MN and UN innervating HM.							Type I
MN and UN Innervating the FDI muscle							Type II
MN and UN innervating TM muscles							Type III
Muscular branch to FDP muscle	Looped anastomosis	Class III		Type II		Type III	
AIN and UN, muscular branches FDP muscle originated from the connection						Type IV	
Combination or other	Combined anastomosis		Type IV, V	Type III (combination of Type Ia, Ib, and II)		Type V (two anastomotic branch)	

The incidence of anastomosis between the two nerves in earlier reports was 15.2% according to Gruber (6), 15.5% according to Thomson (25), 10.5% according to Hirasawa (9), 15.5% according to Mannerfelt (12), 23% according to Taams (24), 21.3% according to Nakashima (14), 13.1% according to Rodriguez-Niendenfuhr *et al* (17).

Mannerfelt (12) was the first to use electrodiagnostic techniques to detect anastomosis between the two nerves and reported a 15% incidence in a study of 41 patients. Crutchfield and Gutmann (4) found an incidence of 28% in the general population and 62% in 29 relatives of 5 subjects with anastomosis. Several other authors, using electrodiagnostic techniques, have reported incidences of anastomosis ranging from 8% to 26% in patients

with carpal tunnel syndrome (CTS) and from 15% to 39% in either normal or unselected subjects. Uchida and Sugioka (26) determined the incidence of anastomosis in patients without and with cubital tunnel syndrome and found an incidence of 16% in the normal controls and 17% in the cubital tunnel syndrome group. In other electrodiagnostic studies the highest incidence of the anastomosis was found for the first dorsal interosseous muscle (FDI). Wilbourn and Lambert (29) reported that anomalous axons innervate the FDI muscle much more commonly (95%) than the hypothenar (41%) and thenar muscles (14%). In 22 limbs showing the anastomosis in our study, the anastomotic median axons innervated the FDI area 21 times, hypothenar muscles in 9 cases and thenar muscles in 3 cases.

Kimura *et al* (11) studied 656 arms of 328 subjects using electrophysiological methods and found anastomosis in 57 (17%) subjects and 96 arms (15%). The incidence of anastomosis in our study was 8.6%.

We used the classification of patterns and types (18) to compare our results to those of previous reports. Pattern I comprises cases with one anastomotic branch, and Pattern II those with two anastomotic branches. Types a, b, and c are subdivisions depending on the level of origin of the anastomosis from the median nerve. Type a originates from the branch of the median nerve to the superficial forearm flexor muscles. Type b originates from the median nerve itself and Type c from the anterior interosseous nerve. Our results confirm that the anastomosis appears as one branch with various origins from the median nerve or its branches, as already described by Thomson (25), Srinivasan and Rhodes (22) and Taams (24) (table III). Intramuscular anastomosis has also been described (14, 17), but we found no such anastomosis despite the use of magnification during dissection.

The course of the anastomosis has been more frequently described as transverse or oblique than arched (6, 9). We found that the transverse or oblique course depended on whether the anastomotic end at the ulnar nerve was in the superior or middle one-third of the forearm.

At its termination, the anastomosis has been recorded either as a single branch or as a single branch which divided into two branches, one with an oblique course and the other with a recurrent course (9). Like Gruber (6), we found a single connection more frequently than a double one.

It has been suggested that unilateral anastomosis between the two nerves occurs more often on the right side than on the left (24). In our study anastomoses were also found mainly on the right side in anatomical examination (four against two).

Crutchfield and Gutmann (4) and Piza-Katzer (16) found median-ulnar nerve communication in the family members of persons who showed this anomalous connection, and suggested that there is familiar inheritance, probably autosomal dominant. In the present study, we did not study familiar occurrence.

Occurrence frequency for ulnar to median nerve communication was reported as 5% by Rosen (19) and 16.7% by Golovchinsky (5). In the present study, we did not find any ulnar to median communication.

No statistically significant difference was found between men and women regarding the frequency of these anastomoses. This was an expected result, in view of earlier analyses, which indicated autosomal dominant inheritance of these innervation variants (4).

There is now electrophysiological evidence that median – ulnar nerve anastomoses convey motor fibers from the median to the ulnar nerve in the forearm for innervation of the intrinsic muscles in the hand (7, 10). These electrophysiological findings indicate that there is motor communication from the median to the ulnar nerve in the forearm. Median nerve stimulation at the elbow evoked not only muscle action potentials (MAP) from the thenar muscles, but also from the hypothenar and the first dorsal interosseous muscles.

Table III. — Patterns and types of anastomosis shown by different authors

	Pattern I	Type Ia	Type Ib	Type Ic	Pattern II
Gruber	95%	13%	8%	74%	5%
Thomson	100%	3%	19%	78%	–
Hirasawa	50%	15.4%	–	34.6%	50%
Srinivasan and Rhodes	100%	6%	3%	91%	–
Nakashima	95.6%	–	4.35%	91.3%	4.35%
Taams	100%	7%	–	93%	–
Shu	64.7%	–	17.6%	47.1%	35.3%
Rodriguez-Niedenfuhr	89.5%	47.3%	10.6%	31.6%	10.5%
Our results	100%	7%	7%	87%	–

It is therefore clear that the anastomoses between median and ulnar nerves are clinically relevant. These connections are often suggested as causes for unusual motor losses of the muscles in the hand after peripheral nerve lesions (3, 20). Symptoms of carpal tunnel syndrome with co-existence of this anastomosis may be incomplete because of proper functionality of thenar muscles (10). By recognising the existence of different types of anastomosis, mistakes in the diagnosis of peripheral nerve lesions or compression neuropathies in the forearm can be avoided (1, 28).

REFERENCES

1. **Bergman FO, Blom SE, Stenstrom SJ.** Radical excision of a fibro-fatty proliferation of the median nerve, with no neurological loss symptoms. *Plast Reconstr Surg* 1970 ; 46 : 375-380.
2. **Bunnell S.** *Surgery of the Hand*. 3rd ed. JB Lippincott, Philadelphia, 1956, p 54.
3. **Cliffon E.** Unusual innervation of the intrinsic muscles of the hand by median and ulnar nerve. *Surgery* 1948 ; 23 : 12-31.
4. **Crutchfield CA, Gutmann L.** Hereditary aspects of median-ulnar nerve communications. *J Neurol Neurosurg Psychiatry* 1980 ; 43 : 53-55.
5. **Golovchinsky V.** Frequency of ulnar-to-median nerve anastomosis revisited. *Electromyogr Clin Neurophysiol* 1995 ; 35 : 67-68.
6. **Gruber W.** Über die Verbindung Des Nervus medianus mit dem Nervus ulnaris am Unterarme des Menschen und der Säugethiere. *Arch Anat Physiol Wissen Med* 1870 ; 37 : 501-522.
7. **Gutmann L.** Median - ulnar nerve communications and carpal tunnel syndrome. *J Neurol Neurosurg Psychiatry* 1977 ; 40 : 982-986.
8. **Gutmann L.** AAEM minimonograph #2 : important anomalous innervations of the extremities. *Muscle Nerve* 1993 ; 16 : 339-347.
9. **Hirasawa K.** Untersuchungen über das periphere Nervensystem, Plexus brachialis und die Nerven der oberen Extremität. *Arch Anat Inst Kaiserlichen Univ Kyoto* 1931 ; A2 : 135-136.
10. **Iyer V, Fenichel GM.** Normal median nerve proximal latency in carpal tunnel syndrome : a clue to coexisting Martin-Gruber anastomosis. *J Neurol Neurosurg Psychiatry* 1976 ; 39 : 449-452.
11. **Kimura J, Murphy MJ, Varda DJ.** Electrophysiological study of anomalous innervation of intrinsic hand muscles. *Arch Neurol* 1976 ; 33 : 842-844.
12. **Mannerfelt L.** Studies on the hand in ulnar nerve paralysis. A clinical-experimental investigation in normal and anomalous innervation. *Acta Orthop Scand* 1966 : Suppl 87 part 2 : 19-29.
13. **Martin R.** Tal om nervus allmanna Egenskaperi Mannisikans Kropp. *Las Salvius* 1763.
14. **Nakashima T.** An anatomic study on the Martin-Gruber anastomosis. *Surg Radiol Anat* 1993 ; 15 : 193-195.
15. **Oh SJ, Claussen GC, Ahmad BK.** Double anastomosis of median-ulnar and ulnar-median nerves : report of an electrophysiologically proven case. *Muscle Nerve* 1995 ; 18 : 1332-1334.
16. **Piza-Katzer H.** [Familial occurrence of Martin-Gruber anastomosis]. *Handchirurgie* 1976 ; 8 : 215-218.
17. **Rodriguez-Niedenfuhr M, Vazquez T, Parkin I, Logan B, Sanudo JR.** Martin-Gruber anastomosis revisited. *Clin Anat* 2002 ; 15 : 129-134.
18. **Rodriguez-Niedenfuhr M, Vazquez T, Ferreira B, Parkin I, Nearn L, Sanudo JR.** Intramuscular Martin-Gruber anastomosis. *Clin Anat* 2002 ; 15 : 135-138.
19. **Rosen AD.** Innervation of the hand : an electromyographic study. *Electromyogr Clin Neurophysiol* 1973 ; 13 : 175-178.
20. **Rowntree T.** Anomalous innervation of the hand muscles. *J Bone Joint Surg* 1949 ; 31-B : 505 - 510.
21. **Shu H, Chantelot C, Oberlin C, Alnot JY, Shao H.** [Anatomic study and review of the literature on the Martin Gruber anastomosis]. *Morphologie* 1999 ; 83 : 71-74.
22. **Srinivasan R, Rhodes J.** The median-ulnar anastomosis (Martin-Gruber) in normal and congenitally abnormal fetuses. *Arch Neurol* 1981 ; 38 : 418-419.
23. **Streib EW.** Ulnar-to-median nerve anastomosis in the forearm : electromyographic studies. *Neurology* 1979 ; 29 : 1534-1537.
24. **Taams KO.** Martin-Gruber connections in South Africa. An anatomical study. *J Hand Surg* 1997 ; 22-B : 328-330.
25. **Thomson A.** Third annual report of the Committee of Collective Investigations of the Anatomical Society of Great Britain and Ireland for the years 1891-1892. *J Anat* 1893 ; 27 : 183-194.
26. **Uchida Y, Sugioka Y.** Electrodiagnosis of Martin-Gruber connection and its clinical importance in peripheral nerve surgery. *J Hand Surg* 1992 ; 17-A : 54-59.
27. **Van Dijk JG, Bouma PA.** Recognition of the Martin-Gruber anastomosis. *Muscle Nerve* 1997 ; 20 : 887-889.
28. **Van Tieghem J, Vandendriessche G, Vanhecke J.** Martin-Gruber anastomosis : the explanation for late diagnosis of severe ulnar nerve lesions at the elbow. *Electromyogr Clin Neurophysiol* 1987 ; 27 : 13-18.
29. **Wilbourn AJ, Lambert EH.** The forearm median to ulnar nerve communication : electrodiagnostic aspects. *Neurology* 1976 ; 26 : 368.