



Recombinant human bone morphogenetic protein-2 : A novel osteoinductive alternative to autogenous bone graft ?

Marek SZPALSKI, Robert GUNZBURG

From the Hôpitaux Iris Sud, Bruxelles, Belgium and Eeuwfeest Kliniek, Antwerpen, Belgium

Autogenous bone grafts from the iliac crest have long been the gold standard for repair and reconstruction of bone ; however harvesting of the grafts from the iliac crest is associated with donor site morbidity, particularly chronic pain. The bone morphogenetic proteins (BMPs) are soluble bone matrix glycoproteins that induce the differentiation of osteoprogenitor cells into osteogenic cells and have the potential to act as autogenous bone graft substitutes. BMP-2, which can be produced with recombinant technology, is highly osteoinductive, inducing bone formation by stimulating the differentiation of mesenchymal cells into chondroblasts and osteoblasts. At present, more than 1,000 patients have received rhBMP-2 in clinical trials for acute open tibial fracture and interbody fusion procedures for the treatment of degenerative disc disease. Data suggest that rhBMP-2 therapy may offer an effective alternative to autogenous bone graft for recalcitrant bone unions and spinal fusion, obviating donor site morbidity.

INTRODUCTION

Autogenous bone grafts from the iliac crest have long been the gold standard for repair and reconstruction of bone, satisfying all of the requirements for bone generation (41, 63) and yielding high fusion rates (63). Unfortunately, harvesting of autogenous bone grafts is associated with the risk of iliac crest donor site morbidity (3, 4, 17, 20, 25, 28, 63, 69, 79). Indeed, the overall morbidity associated with iliac crest bone harvesting in lumbar fusion approaches

30% (49). Complications include vascular and nerve injuries, iliac wing fracture, haematoma, infection, cosmetic disfigurement, and particularly chronic pain.

Donor site pain is usually moderate in intensity, but is described as “significant”, “severe”, or “unacceptable” by some patients (20, 28, 69). In one large study (n = 300), 17% of patients who underwent autogenous bone grafting reported debilitating donor site pain or pain that required narcotic analgesic medication for at least 3 months after surgery (63). Pain usually lasts for more than a year in approximately one-quarter of the affected patients (20, 25, 28) ; in some individuals, it is severe enough to limit ambulation for at least 2 years after surgery (25).

Over the years, different bone substitutes have been proposed in an attempt to avoid the donor site morbidity associated with autogenous bone grafts, and to provide suitable alternatives when insufficient donor bone is available (table I). A true bone

■ Marek Szpalski, MD, Chairman.

Department of Orthopaedics, Hôpitaux Iris Sud, Bruxelles, Belgium.

■ Robert Gunzburg, MD, PhD, Orthopaedic Surgeon.

Afdeling Orthopedie, Eeuwfeestkliniek, Antwerpen, Belgium.

Correspondence : Marek Szpalski, 21 Avenue Coghén, 1180 Bruxelles, Belgium. E-mail : marek.szpalski@win.be.

© 2005, Acta Orthopædica Belgica.

Table I. — Properties of bone graft materials (63). Reproduced with kind permission of the *Journal of Neurosurgery* from Sawin PD, Traynelis VC, Menezes AH. A comparative analysis of fusion rates and donor-site morbidity for autogeneic rib and iliac crest bone grafts in posterior cervical fusions. *J Neurosurg* 1998 ; 88 : 255-265

Graft material	Osteoprogenitor cells	Osteoinductive factors	Osteoconductive matrix	Immuno-genicity	Disease transmission	Donor site morbidity
Autogenous bone graft [†]	++	++	++	–	–	++
Fresh allograft bone [†]	–	+	++	++	++	–
Frozen allograft bone [†]	–	+	++	+	++	–
Freeze-dried allograft bone [†]	–	+/-	++	+/-	+/-	–
Demineralised bone matrix	–	++	+	–	+/-	–

[†]Corticocancellous or cancellous bone ; ++ = high ; + = intermediate ; +/- = minimum ; – = none.

substitute that is able to induce bone healing and formation requires two components : an osteoconductive scaffold to permit bony apposition, and an osteoinductive signal, which will allow the recruitment and differentiation of bone forming cells from the host's tissues. Allografts are a popular alternative to autogenous bone grafts. However, it appears that only osteoconductive capacity is retained, with osteoinductive properties being lost. Furthermore the quality of allografts is often inconsistent and there is a limited, but existing, potential for transmission of infectious disease (14, 74).

In the 1960s, Urist *et al* (7) discovered the bone morphogenetic proteins (BMPs) : soluble bone matrix glycoproteins that induce the differentiation of osteoprogenitor cells into osteogenic cells. Their potential to act as bone inductive agents, which could be used in several applications where bone generation was needed, was soon recognised. Following the isolation and expression of BMP complementary DNA, two recombinant human proteins – rhBMP-2 and rhBMP-7 (OP-1) – are now commercially available for acute and revision orthopaedic surgery.

Demineralised bone matrix (DBM), which is made by decalcifying allogeneic bone while maintaining the extracellular matrix appears to maintain a certain osteogenic potential owing to its content of expressed BMPs. However, variability in BMP content (particularly BMP-2, BMP-4, and BMP-7) within different lots of the same DBM product can be as much as four-fold (32). In addition, the BMP content of DBM is low ; it has been estimated that

it would take 100 kg of Grafton® DBM to achieve a 6 mg dose of rhBMP-2 (32). Despite manufacturing processing, the potential for transmission of diseases due to the human origin of DBM also cannot be ruled out.

Numerous other bone substitutes have been developed based on calcium ceramics (e.g. hydroxyapatite, beta-, bi-, or tri-calcium phosphates). These offer purely osteoconductive properties ; however, it seems that those with a higher microporosity and high interconnection structure offer optimal capillarity and wicking, allowing migration of osteogenic cells and growth factors (40, 71). Some also provide structural strength.

This article will review the role of BMPs in bone morphogenesis and the subsequent investigation of rhBMP-2 for orthopaedic application.

BONE MORPHOGENESIS

Bone is a rigid form of specialised connective tissue consisting largely of Type I collagen fibres. Mineralisation of the collagen bone matrix with solid particles of calcium phosphate in the form of hydroxyapatite crystals accounts for the rigidity of bone structure. Despite this rigidity, bone is a dynamic tissue that is continually being remodelled by the cells within it. This process enables the turnover and replacement of the matrix in the interior of the bone throughout an individual's life.

Three major cell types are found throughout the extracellular bone matrix : osteoblasts, osteocytes and osteoclasts. Osteoblasts, which develop from

mesenchymal stem cells, are responsible for bone formation, producing and secreting components of bone matrix, including Type I collagen, osteocalcin, osteonectin and alkaline phosphatase. They undergo several fates in humans. Some osteoblasts remain active, synthesising and regulating the deposition and mineralisation of bone, while others become embedded in their own secretions and are trapped within the hard mineralised bone matrix. These cells form resting osteocytes, which are incapable of cell division and are chiefly responsible for bone maintenance. Osteoclasts, which are also present in the bone matrix, are giant multinucleated cells that derive from haemopoietic stem cells in the bone marrow. These cells are involved in bone resorption and remodelling (fig 1).

Ossification of bone is a multifaceted process. Mesenchymal stem cells are attracted to and attach to the bone matrix, where they proliferate and differentiate into chondrocytes and osteoblasts. At the same time, proliferation and differentiation of haematopoietic stem cells to form osteoclasts enables the destruction of the original matrix to be coupled to the formation of new bone. Neovascularisation and mineralisation are also taking place. The BMPs appear to have roles in both the chemotaxis, mitogenesis and differentiation of mesenchymal stem cells, as well as the promotion of angiogenesis.

BONE MORPHOGENETIC PROTEINS

In 1971, Marshall Urist (75) coined the term "bone morphogenetic protein" to describe a protein component of DBM that could induce new bone formation in a manner recapitulating the normal events of endochondral ossification. A Medline search for the term today (March 2005) reveals the subsequent publication of more than 5,500 articles on BMPs, which, in addition to roles in bone and cartilage morphogenesis, are also implicated in prenatal development, postnatal growth of soft tissues, including eye, heart, lung, kidney, and skin, and various pathological processes, such as atherosclerosis, hypertension, and prostate cancer.

The human genome encodes more than 20 BMPs. The proteins have been grouped into

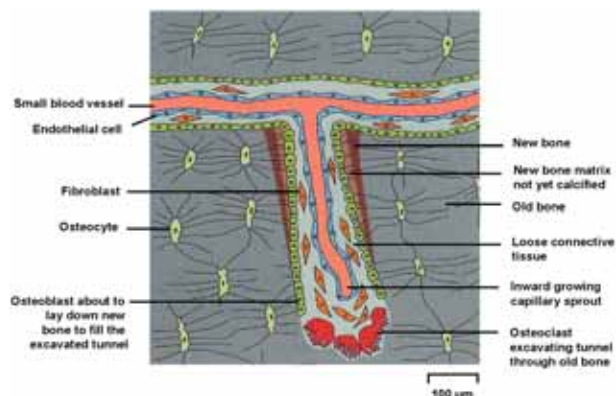


Fig. 1. — The remodelling of compact bone (31). Osteoclasts excavate a tunnel through old bone. Osteoblasts enter the tunnel behind the osteoclasts, line its walls, and begin to form new bone. Neovascularisation occurs down the centre of the tunnel. The tunnel will eventually become filled with concentric layers of new bone, with only a narrow central canal remaining to provide access for osteoblasts and osteoclasts and blood vessel(s) (to enable nutrient supply). Reproduced with the kind permission of the publishers (Blackwell Publishing Ltd) from Jaworski ZFG, Duck B, Sekaly G. Kinetics of osteoclasts and their nuclei in evolving secondary Haversian systems. *J Anat* 1981 ; 133 : 397-405.

subsets based on amino acid sequence homology (table II). With the exception of BMP-1, which was mistakenly classified as a BMP, these low-molecular weight, non-collagenous glycoproteins belong to the transforming growth factor-beta (TGF- β) superfamily. Other members of the TGF- β family are also involved in developmental processes, particularly embryonic development and the regeneration of skeletal tissues in adults. BMP-2, BMP-4 through to BMP-7, and BMP-9 have been shown to induce intramembranous and endochondral bone formation (58). Of these, BMP-2, BMP-6 and BMP-9 appear to have important roles in the induction of mesenchymal cell differentiation into osteoblasts (15).

BMPs are synthesised by osteoblasts as 400–500 amino acid peptides, each consisting of a leader sequence, a propeptide, and a mature osteoinductive domain at the carboxy-terminal (fig 2). The mature domain of each BMP contains a region of seven conserved cysteine amino acids, six of which are involved in forming a characteristic structural motif : a cysteine-knot with two finger-like double-

Table II. — Bone morphogenetic proteins : grouped by amino acid sequence homology (59). Adapted with the kind permission of the publishers (Medtronic Sofamor Danek) from Rodriguez WJ, Coakley MB. Basic bone biology. Training and development. Medtronic 2002

BMP group members	Alternative nomenclature
BMP-2 BMP-4	– BMP-2b
BMP-3 BMP-3b	Osteogenin GDF-10
BMP-5 BMP-6 BMP-7 BMP-8	– – OP-1 OP-2
BMP-9 BMP-10	OP-3 –
BMP-11	–
BMP-12 BMP-13 BMP-14-	GDF-7 or CDMP-2 GDF-6 or CDMP-1 –
BMP-15	GDF-9b

BMP = bone morphogenetic protein ; CDMP = cartilage-derived morphogenetic protein ; GDF = growth / differentiation factor ; OP = osteogenic protein.

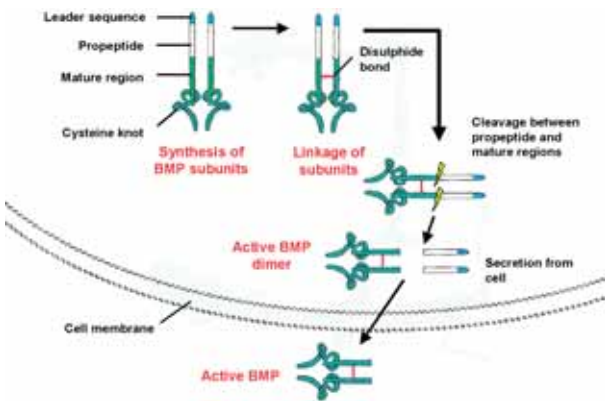


Fig. 2. — Activation of BMP (59). Reproduced with the kind permission of the publishers (Medtronic Sofamor Danek) from Rodriguez WJ, Coakley MB. Basic bone biology. Training and development. Medtronic 2002.

stranded sheets. The molecules exist mostly as biologically active homodimers linked by a disulphide bond between the seventh conserved cysteine residues, although naturally occurring hetero-

dimers and multimers that retain biological activity also exist. Prior to secretion from the osteoblast, BMP molecules are cleaved between the propeptide and mature regions to release the active BMP dimer.

Pre-clinical evidence suggests that active BMP dimers act as a chemoattractant for undifferentiated mesenchymal stem cells, causing them to move into the area of bone defect or injury (78). BMP then binds to serine/threonine kinase receptors (BMP receptor Type I and II) that are displayed on the stem cells' surface. Following ligand binding, the Type II receptor homodimer cross-phosphorylates the Type I receptor in the GS region, activating its kinase domain (fig 3) (19). The Type I receptor kinase then initiates downstream signalling by phosphorylating and activating intracellular messenger proteins called Smads. Distinct Type I and Type II receptors have been identified (33). The specific Smad protein to be activated depends on the type of BMP ligand and the Type I receptor it binds to. BMP-2, for example, binds to BMPiA and BMPiB receptors, whereas BMP-7 binds to ALK-2 or BMP-1b receptors.

Osteoinduction appears to be mediated by R-Smads (Smads 1, 5, and 8). Smads 1 and 5 are

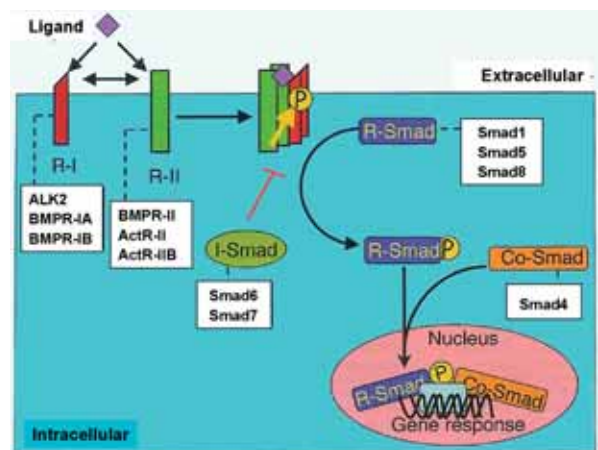


Fig. 3. — Signal transduction via BMP receptors (19). Reproduced with kind permission of the publishers (The Journal of Bone and Joint Surgery, Inc.) from ten Dijke P, Fu J, Schaap P, Roelen BAJ. Signal transduction of bone morphogenetic proteins in osteoblast differentiation. *J Bone Joint Surg* 2003 ; 85-A (Suppl 3) 34-38. © The Journal of Bone and Joint Surgery, Inc.

activated by BMP-Ia and BMP-Ib receptors, whereas Smads 1, 5, and 8 can be activated by ALK-2 receptors. Once activated, R-Smads combine with Smad 4 to form a nuclear signalling complex that is capable of altering specific patterns of gene expression to promote cell proliferation and stimulate the concentration-dependent transformation of daughter cells into chondroblasts or osteoblasts. Smads 6 and 7 compete for phosphorylation of Smad 4, and appear to be involved in the inhibition of osteoinduction; the mechanism of action is not yet understood, but probably involves negative feedback (46).

BMPs also promote angiogenesis during ossification (18, 47, 48, 50, 72) via a mechanism that involves osteoblast-derived VEGF-A (18). Studies in cell and animal models have shown that BMP-induced neovascularisation is critical for bone induction (47, 48, 50), probably playing an essential role in enabling the recruitment of BMP receptor-positive cells.

RECOMBINANT HUMAN BMP-2 IN ORTHOPAEDIC APPLICATIONS

Endogenous BMPs are typically found in the body at a concentration of less than 2 mg/kg in cortical bone (55) and are difficult to extract in sufficient quantities for clinical use. The isolation and cloning of the human BMP-2 gene and the subsequent production of its recombinant form (rhBMP-2; diboterminal alfa) in large quantities was, therefore, a landmark.

Recombinant human BMP-2 is highly osteoinductive (41). *In vitro* studies show that mesenchymal stem cells incubated with rhBMP-2 have increased alkaline phosphatase activity and undergo matrix mineralisation (16, 57). When implanted *in vivo*, rhBMP-2 induces osteoinduction by recruiting mesenchymal stem cells, then inducing the proliferation and differentiation of these cells into an osteoprogenitor lineage. The bone formed has exactly the same composition as bone elsewhere in the body (76).

In the human body, tissue clearance of BMPs is rapid; hence, a carrier is required to retain an effective concentration of rhBMP-2 at the site of

implantation. The carrier also provides a scaffold for new bone formation. Early studies in animal segmental defect models explored several materials (23, 36, 44, 53, 65). Type I collagen has proved to be the most bioactive, biocompatible and bioresorbable carrier, and all rhBMP products currently on the market incorporate forms of collagen I.

In Europe, rhBMP-2 is commercially available as the active pharmaceutical ingredient of the InductOS™ implant kit (Medtronic Sofamor Danek and Wyeth Pharmaceuticals) for treatment of acute open tibial fracture. The kit contains rhBMP-2 as a lyophilised powder, which is dissolved in sterile water and applied to an absorbable collagen sponge (ACS) made of Type I bovine collagen. In Europe and the USA, rhBMP-2 is available with ACS as the InFUSE™ bone graft (Medtronic Sofamor Danek), which includes a perforated, threaded, cylindrical, tapered, titanium interbody fusion cage, and is available for the clinical treatment of degenerative lumbar disc disease.

Few complications have been observed during clinical trials with rhBMP-2 at therapeutic dosages, despite the fact that BMPs – by virtue of their nature – have the potential to induce heterotopic bone formation. As with all exogenous protein molecules, antibody formation is a concern. Antibodies to rhBMP-2 and the bovine collagen carrier have been reported to occur in approximately 6% and 5-20% of patients, respectively, but titres have been low and transient and no clinical sequelae have been observed (73).

SPINAL FUSION

Fusion for chronic low back pain due to degenerative disc disease seems to alleviate pain in selected groups of patients (21). The oldest surgical technique is that of non-instrumented fusion (posterolateral or interbody). Different surgical options, combined with different types of fixation instrumentation have more recently become popular, including anterior lumbar interbody fusion (ALIF) with supplemental posterior instrumentation, posterior lumbar interbody fusion (PLIF) with posterolateral instrumentation, and transforaminal lumbar interbody fusion (TLIF) with posterolateral

instrumentation (51). However, the optimal technique for performing lumbar spinal fusion remains a subject of controversy. Proponents of the newer techniques claim that they permit better rates of solid arthrodesis and improved clinical results. For instance, proponents of so-called "360° fusion", which combines interbody with posterior fixation, argue that the technique gives increased stability. Nevertheless, to date there is only a limited number of well-conducted studies that have compared instrumented with non-instrumented fusion. Rates of solid fusion have been inconsistent. Even with autogenous bone grafts, pseudarthrosis rates of up to 35% have been reported (49). It is difficult to predict which patients will develop a pseudarthrosis (9). Although it appears that the fusion rate is indeed better with instrumented procedures, clinical results do not differ. Fritzell *et al* did not find any differences in clinical outcome between non-instrumented, posterolateral and 360° fusion during a high quality, randomised study (22).

The clinical use of rhBMP-2 as an osteoinductive alternative to autogenous bone graft has been investigated at posterolateral, anterior, posterior and transforaminal lumbar sites. Both instrumented and non-instrumented fusion have been studied. The results of these studies are summarised in table III and reviewed in detail in the sections below. Two in-depth reviews of rhBMP-2 have also been published recently, which provide deeper insight into the pre-clinical development of the agent than provided here (34, 46).

Posterolateral fusion

Early pre-clinical studies of posterolateral fusion showed that while rhBMP-2 plus ACS achieved fusion rates of 100% in lower animal models (rabbit and dog) (60, 64), in higher animal models the ACS appeared to be compressed by muscle fibres, hampering bone formation (43). Different carriers for rhBMP-2 have been investigated in an attempt to avoid this problem.

A biphasic calcium phosphate (BCP) ceramic carrier (60% hydroxyapatite; 40% tricalcium phosphate) has been developed (63). When used in conjunction with the BCP carrier in a non-human

primate model, rhBMP-2 dose-dependent fusion was observed. During the same investigation, no fusion was observed in animals receiving autogenous bone graft. Two pilot studies (table III) suggest that these findings are also applicable to humans (6, 42). In the first study, eight patients were treated bilaterally with rhBMP-2 (20 mg) plus BCP (10 cm³); a second group of seven patients was treated unilaterally with rhBMP-2 (15 mg) plus BCP (7 cm³), and contralaterally with autogenous bone graft (6). After 12 months, solid posterolateral fusion had occurred in all patients receiving rhBMP-2 bilaterally. Incomplete fusion was observed in the second group, although fusion was more likely on the side receiving rhBMP-2 than on the side receiving autogenous bone graft (86% vs 57%). Clinical success was achieved in 100% of patients receiving bilateral rhBMP-2, compared with 87% of patients receiving rhBMP-2 and autogenous bone graft. In the second study (42), patients received either rhBMP-2 (2.0 mg/ml) plus BCP with instrumentation (n = 11), rhBMP-2 (2.0 mg/ml) plus BCP without instrumentation (n = 9) or autogenous bone graft with posterior instrumentation (n = 5) (6). After 17 months, successful fusion was observed in all patients receiving rhBMP-2, compared with only 2/5 patients receiving the autogenous bone graft. Further studies are ongoing.

The pre-clinical development of other carriers is continuing. Recently, improved fusion rates have been reported with rhBMP-2 applied to carriers containing lower concentrations of hydroxyapatite (63, 67). Nano-hydroxyapatite/collagen composites have also shown promising results (39, 70). Other approaches include adding allograft chips or resorbable ceramic granules to ACS to prevent it from being compressed. Results from animal models demonstrate 100% fusion rates when rhBMP-2 is applied to these carriers (2, 45, 68).

Anterior lumbar interbody fusion

The anterior lumbar site is less challenging than the posterolateral environment and has become a popular alternative in spinal arthrodesis, enabling direct access to the anterior spinal column, indirect

Table III. — Clinical studies with rhBMP-2 in spinal interbody fusion (34). Reproduced (and updated) with the kind permission of the publishers (Ashley Publications) from Khan SN, Lane JM. The use of recombinant human bone morphogenetic protein-2 (rhBMP-2) in orthopaedic applications. *Expert Opin Biol Ther* 2004 ; 4 : 741-748

Trial (approach)	Comparators	Patients (n)	Carrier / cage or dowel	Follow-up (months)	Fusion rate (%)	Clinical outcomes	Reference
Posterolateral fusion							
P, NB, R, C	Bilateral rhBMP-2 (20 mg/10 cm ³)	8	BCP / -	12	100%	Clinical success in 100% in the bilateral rhBMP-2 group vs 87% in group also receiving autogenous bone graft	Boden <i>et al</i> 2002 (6)
	Unilateral rhBMP-2 (15 mg/7 cm ³) plus contralateral autogenous bone graft	7	BCP / -		87%		
P, NB, R, C	rhBMP-2 (2.0 mg/ml)+BCP+ instrumentation	11	BCP / -	17	100%	Clinical success equivalent between groups	Luque 2002 (42)
	rhBMP-2 (2.0 mg/ml) no instrumentation	9	BCP / -		100%		
	Autogenous bone graft + instrumentation	5	- / -	40%			
Anterior lumbar interbody fusion							
P, NB, R, C (open or laparoscopic)	rhBMP-2 (1.5 mg/ml)	11	ACS / titanium cage	6	100%	Pain improved earlier in the rhBMP-2 group	Boden <i>et al</i> 2000 (8)
	Autogenous bone graft	3	- / titanium cage		66%		
P, NB, R, C (open)	rhBMP-2 (1.5 mg/ml)	143	ACS / titanium cage	24	95%	Reduced operative times, blood loss, and hospital duration in the rhBMP-2 group	Burkus <i>et al</i> 2002 (11)
	Autogenous bone graft	136	- / titanium cage		89%		
P, NB, R, C (open)	rhBMP-2 (1.5 mg/ml)	22	ACS / titanium cage	12	100%	Rate of bone formation greater in the rhBMP-2 group	Burkus <i>et al</i> 2003 (10)
	Autogenous bone graft	20	- / titanium cage		95%		
P, NB, R, C (open)	rhBMP-2 (1.5 mg/ml)	24	ACS / allograft bone dowels	24	100%	Blood loss reduced and Oswestry Disability Index improved to greater extent in the rhBMP-2 group	Burkus <i>et al</i> 2002 (13)
	Autogenous bone graft	22	- / allograft bone dowels		68.4%		
P, NB (laparoscopic)	rhBMP-2 (1.5 mg/ml)	136	ACS / titanium cage	12	> 90%	Hospital duration reduced in the rhBMP-2 group	Zdeblick <i>et al</i> 2001 (80)
	Autogenous bone graft (historical control)	266	- / titanium cage		> 90%		

Table III. — Continuation

Trial (approach)	Comparators	Patients (n)	Carrier / cage or dowel	Follow-up (months)	Fusion rate (%)	Clinical outcomes	Reference
P, NR, NB (laparoscopic)	rhBMP-2 (1.5 mg/ml)	22	ACS / titanium cage	6	100%	Improvements vs baseline in Oswestry Disability Index, pain and functional capacity	Kleeman <i>et al</i> 2001 (35)
Integrated analysis† (open or laparoscopic)	rhBMP-2 (1.5 mg/ml)	277	ACS / titanium cage	24	94.4%*	Improved low back pain* and reduced operative times*, blood loss*, hospital duration*, re-operation rate*, and time before returning to work* in the rhBMP-2 group	Burkus <i>et al</i> 2003 (12)
	Autogenous bone graft	402	- / titanium cage		89.4%		
Posterior lumbar interbody fusion							
P, NB, R, C (Study halted)	rhBMP-2 (1.5 mg/ml)	34 33	ACS / titanium cage	24	92.3%	Improved back and leg pain and Oswestry Disability Index in rhBMP-2 group, but heterotopic bone formation seen in spinal canal	Haid <i>et al</i> 2004 (27)
	Autogenous bone graft		- / titanium cage		77.8%		
Transforaminal lumbar interbody fusion							
P, NB, NR	rhBMP-2 (1.5 mg/ml)	21	ACS / titanium cage	3-18	95.2%	58% of patients receiving iliac crest autograft complained of pain 6 months post-surgery	Mummaneni <i>et al</i> 2004 (52)
	Autogenous bone graft	19	- / titanium cage		94.7%		
P, NB, NR	rhBMP-2 (1.5 mg/ml)	43	ACS / biore-sorbable implant	6	98%	Improvements vs baseline in Oswestry Disability Index in 68% of patients at 6 months	Lanman & Hopkins 2004 (38)
NB, NR	rhBMP-2 (1.5 mg/ml)	22	ACS / biore-sorbable implant	6-18	97.4%	Operating time, blood loss and hospital stay consistent with previous reports. No infections, deep vein thromboses or implant complications	Kuklo <i>et al</i> 2004 (37)

C = controlled ; NB = non-blinded ; NR = non-randomised ; P = prospective ; R = randomised

*p < 0.05 vs autogenous bone graft

†Integrated analysis of four studies, including Burkus *et al* 2002 (11) and Kleeman *et al* 2001 (35) ; other studies unspecified.

decompression of the intervertebral foramen, and improvement of sagittal balance, while avoiding paraspinal muscle trauma and denervation (51). Early pre-clinical studies found that rhBMP-2 offered a safe and effective alternative to autogenous bone grafts for ALIF (7, 62, 80). In a sheep model of ALIF, radiological fusion occurred earlier and stiffness was consistently increased following insertion of a titanium interbody fusion cage filled with rhBMP-2 plus ACS compared with a similar cage filled with autogenous bone graft (62). Indeed, fusion rates were three times higher with rhBMP-2 than with autogenous bone graft. Similar results were seen in goats undergoing laparoscopic ALIF : fusion occurred in 95% of cages filled with rhBMP-2 plus ACS, compared with 48% of cages filled with autogenous bone graft (80).

Subsequently, two doses of rhBMP-2 were compared in primates (7). Titanium interbody fusion cages filled with rhBMP-2 plus ACS (0.75 or 1.5 mg/ml) or rhBMP diluent (control) were randomly inserted into eight rhesus monkeys undergoing laparoscopic ALIF. After 24 weeks, all animals that received rhBMP-2 had complete and solid bone bridging, whereas fusion had not occurred in the control animals. Computer tomography (CT) scans showed that fusion occurred earlier in animals that received the higher dose (1.5 mg/ml) of rhBMP-2. Hecht *et al* (29) reported similar findings when they compared the effects of a smooth cortical allograft dowel packed with either rhBMP-2 (1.5 mg/ml) plus ACS or autogenous bone graft in six rhesus monkeys undergoing ALIF. Extensive fusion occurred in all animals that received rhBMP-2, with radiographical evidence of fusion apparent as early as 8 weeks. In contrast, partial fusion occurred in only one of the animals that received autogenous bone graft, after 6 months.

A pilot study was conducted to investigate the effect of rhBMP-2 as a substitute for autogenous iliac crest bone graft for ALIF in humans (Table III) (8). The study involved patients with single-level symptomatic lumbar degenerative disc disease undergoing ALIF by an open or laparoscopic approach. Patients received two titanium interbody fusion cages filled with rhBMP-2 (1.5 mg/ml) plus ACS or autogenous bone graft

from the anterior iliac crest. After 3 months, 10/11 patients who received rhBMP-2 versus 2/3 patients receiving autogenous bone graft had solid interbody fusions. By 6 months, all patients in the rhBMP-2 group had solid interbody fusions, versus 66% in the control group. Pain (rated on the Oswestry Low Back Pain Disability Questionnaire) improved sooner (after 3 months) in the investigational than in the control group, while both groups showed similar improvement after 6 months.

The pilot study was expanded to include a total of 279 patients undergoing single-level ALIF via an open approach (Table III) (11). Patients were randomised to implantation of titanium interbody fusion cages filled with either rhBMP-2 plus ACS (1.5 mg/ml) (n = 143) or autogenous bone graft (n = 136). Eight patients (5.9%) who received the autogenous bone graft experienced adverse events relating to harvesting of bone at the iliac crest, including nerve injury, fracture, infection and haematoma. All patients in the group reported donor site pain. The incidence of pain was highest immediately following the operation (mean pain score : 12.7 on scale of 0-20) and decreased with time ; however 32% of patients were still experiencing pain 24 months later (mean pain score : 1.8). Patients treated with rhBMP-2 did not undergo a bone harvesting procedure and consequently, compared with patients receiving the autogenous bone graft, operative times were shorter (1.7 vs 2.0 hours), operative blood loss was less (109 vs 154 ml), and time spent in hospital was reduced (3.1 vs 3.3 days). After 24 months, 95% of patients who received rhBMP-2 and 89% of patients who received autogenous bone graft had radiographic and CT evidence of interbody fusion. In no case in either treatment group did ossification extend outside of the vertebral column. Back pain, leg pain and neurologic status improved in both treatment groups to a similar extent. Patients who were working before surgery were able to return to work within a similar time frame in both groups (median : 63.5 (rhBMP-2) vs 64.5 days (autogenous bone grafts), respectively) (fig 4).

A smaller study by the same group recorded similar effects (Table III) (10). Radiographic evidence of osteoinduction was apparent within

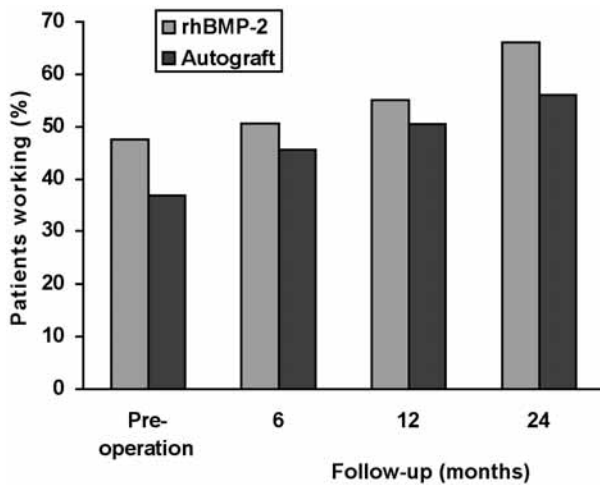


Fig. 4. — Proportion of patients working after a single-level ALIF with either rhBMP-2 or autogenous iliac crest bone graft (n = 279) (11). Reproduced with kind permission of the publishers (Lippincott Williams & Wilkins) from Burkus JK, Gornet MF, Dickman C, Zdeblick TA. Anterior lumbar interbody fusion using rhBMP-2 with tapered interbody cages. *J Spinal Disord Tech* 2002 ; 15 : 337-349.

6 months of implanting titanium interbody fusion cages filled with either rhBMP-2 (1.5 mg/ml) plus ACS (22/22 patients) or autogenous bone graft (19/20 patients). CT scans showed that the rate of bone formation in the rhBMP-2 group exceeded that seen in the autogenous bone graft group, almost doubling in the first 6 months, and increasing by a factor of almost 2.5 by 24 months. All new bone formation outside the cages occurred within the disc space with no evidence of ectopic bone formation.

The comparative effects of using rhBMP-2 (1.5 mg/ml) plus ACS or autogenous bone graft implanted within a cortical threaded allograft bone dowel, rather than a titanium fusion cage, were investigated in 46 patients undergoing single-level ALIF for degenerative disc disease (Table III) (13). Operative times and time spent in hospital were similar in patients randomised to receive rhBMP-2 (n = 24) or autogenous bone graft (n = 22) ; however operative blood loss was reduced in the rhBMP-2 group. A statistically significantly greater improvement in Oswestry Disability Index was

also seen in the rhBMP-2 group at 3 and 6 months post-surgery. After 12 months, all patients in the rhBMP-2 group had solid interbody fusions that remained fused at 24 months. In contrast, fusion rates in the autogenous bone graft group were lower (89.5% at 12 months and 68.4% at 24 months). Neurologic status, back and leg pain also improved to a greater extent in the rhBMP-2 group, and 24 months post-surgery more patients in this group were employed than had been before the operation (rhBMP-2 : 66.7% vs 45.8% ; autogenous bone graft : 35.0% vs 40.9%).

In recent years, surgeons have combined modern laparoscopic techniques with ALIF, to achieve what many believe to be a less invasive approach. Zdeblick *et al* (80) examined the effect of implanting titanium interbody fusion cages filled with rhBMP-2 (1.5 mg/ml) plus ACS via a laparoscopic approach in 136 patients undergoing ALIF for treatment of single-level degenerative disc disease. Operative times and blood loss were similar to historical control values taken from a study on 266 patients in whom laparoscopic insertion of titanium interbody fusion cages filled with autogenous bone graft had been performed ; however, time spent in hospital was markedly reduced. After 12 months, fusion rates were similar to historical control values for laparoscopic implantation of rhBMP-2 and laparoscopic implantation of autogenous bone graft. Similar results were reported from a case series in which titanium interbody fusion cages filled with rhBMP-2 plus ACS were inserted laparoscopically in 22 patients with degenerative disc disease (35). Significant improvement in Oswestry Disability Index, pain and functional capacity was observed after 6 and 12 months ($p < 0.001$) and all employable patients had returned to work within 12 months. Investigators observed contiguous ossification in 21 evaluable patients 6 months post-surgery. While two complications occurred as a result of the laparoscopic approach, no complications were attributed to use of rhBMP-2.

To confirm the statistical significance of the observed effects of rhBMP-2 during ALIF, Burkus *et al* (12) performed an integrated analysis of data from four multicentre trials. In total, 277 patients

who had received rhBMP-2 and 402 who had received autogenous bone graft were included in the analysis. All patients had undergone a single ALIF procedure – either by open (n = 279) or laparoscopic (n = 400) approach. Compared with patients receiving autogenous bone graft, those in the rhBMP-2 group had significantly shorter operative times (2.7 vs 1.8 hours ; p < 0.001), reduced operative blood loss (193 vs 127 ml ; p = 0.024), fewer days in hospital (3.1 vs 2.2 days ; p < 0.001), and demonstrated higher fusion rates after 24 months (89.4% vs 94.4% ; p = 0.022). In addition, low back pain improved at all time points (p < 0.01), patients underwent fewer re-operations (7.96% vs 2.89% ; p = 0.0036), and the median time that elapsed before patients returned to work was less (170.5 vs 116.0 days ; p = 0.0156).

POSTERIOR LUMBAR INTERBODY FUSION

During PLIF, lateral dissection is limited to the facet joints, eliminating the exposure of the transverse process. The technique enables direct neural decompression, combined with restoration of disc space height and sagittal balance. Preliminary data on the use of rhBMP-2 in PLIF have been reported from a single pilot study in 67 patients undergoing lumbar decompression for single-level degenerative disc disease (table III) (27). Patients had been randomised to receive stand-alone titanium interbody fusion cages packed with either rhBMP-2 plus ACS (n = 34) or autogenous bone graft (n = 33). Mean operative time was 2.6 vs 3.0 hours, and mean blood loss was 322.8 vs 372.7 ml, respectively. Back and leg pain and Oswestry Disability Index scores improved in both the rhBMP-2 and autogenous bone graft groups. Fusion rates were 92.3% for rhBMP-2 and 77.8% for autogenous bone graft after 24 months. There were no statistically significant differences between the groups for any of these parameters. Despite these beneficial outcomes, the trial was stopped following the detection of heterotopic bone formation in the spinal canal adjacent to the fusion cages in 24 patients receiving rhBMP-2 and 4 patients receiving autogenous bone graft. It was thought this effect might have resulted from cages that were

not correctly recessed within the confines of the disc space. Sagittal balance of the instrumented vertebral motion segment was also thought to have played a role. Concerns were also expressed about the long-term mechanical stability of stand-alone cylindrical cages, which are no longer widely used for spinal surgery. Modified surgical techniques and selection of patients with less vertebral slip may improve outcomes. Further studies with rhBMP-2 in posterior lumbar interbody fusion are currently ongoing.

TRANSFORAMINAL LUMBAR INTER-BODY FUSION

TLIF involves placing bone grafts and titanium cages into a distracted disc space via the posterolateral transforaminal route, with a pedicle screw construct. As the technique does not require anterior abdominal exposure, it should avoid vascular, abdominal wall and autonomic complications (51). Data have been reported on the use of rhBMP-2 plus ACS compared with autograft in TLIF (table III) (52). Forty patients received titanium interbody fusion cages packed with either rhBMP-2 plus ACS (n = 21) or autogenous bone graft (n = 19) in a non-randomised fashion. During a mean follow-up of 9 months, solid fusion was observed in all but one of the patients who received rhBMP-2 plus ACS. Similarly, one pseudoarthrosis was detected in patients who received autogenous bone graft. Notably, 58% of patients in whom an iliac crest autograft had been used complained of donor site pain 6 months post-surgery.

More recently, several studies have explored the use of synthetic poly (L-lactide-co-D, L-lactide) bioresorbable implants packed with rhBMP-2 as an alternative to titanium cages during TLIF (table III) (37, 38). These bioresorbable implants provide immediate stability whilst allowing gradual transfer of load to the developing fusion mass. A prospective study was conducted in 43 patients with degenerative disc disease ; nearly one-third of participants underwent multi-level fusions with bioresorbable implants packed with rhBMP-2 plus ACS (38). Improvements were seen in Oswestry Disability Index in 68% of patients after 6 months.

Solid interbody fusions were observed in 98% of patients. After 12 months, complete bridging of bone was seen in all patients for whom CT scans were available ($n = 11$). In another study (a consecutive case series of 22 patients undergoing single or multiple-level TLIF with bioresorbable implants packed with rhBMP-2 plus ACS) bridging bone was observed within 3 months (37). Solid fusion was observed in 97.4% (38/39) of fusion levels between 6 and 12 months post-surgery. The fusion mass appeared to increase with time. Notably, there were no reports of infections or implant complications.

TIBIAL TRAUMA AND NON-UNION

Standard care for acute open tibial fractures usually includes external fixation or intramedullary nail fixation and routine soft tissue management. Limited vascular supply, sparse tissue coverage, and a high risk of infection at the fracture site can hamper successful healing in spite of adequate and early management. Indeed, healing times for tibial fractures are frequently longer than for other fractures.

Based on the observed effects of rhBMP-2 plus ACS on healing in segmental defect models, its application to long bone fractures was investigated in goats (77). Bilateral closed tibial fractures were created, then stabilised using external fixation in 16 animals. The goats were randomised to receive rhBMP-2 (0.86 mg) plus ACS or buffer plus ACS applied to one tibial fracture; the contralateral fracture served as control. After 3 weeks, increased callus was observed in tibiae treated with rhBMP-2 plus ACS, and after 6 weeks radiographic healing scores were superior in this group compared with both controls.

A pilot study went on to investigate the effect of rhBMP-2 (0.43 mg/ml) plus ACS on fracture healing in 12 patients with open tibial fractures (Gustilo-Anderson classification II or higher) (56). Recombinant human BMP-2 plus ACS was associated with fracture healing (without secondary intervention) in 9/12 treated patients within 6 months.

More recently, a prospective, randomised, single-blind, multicentre study was conducted in

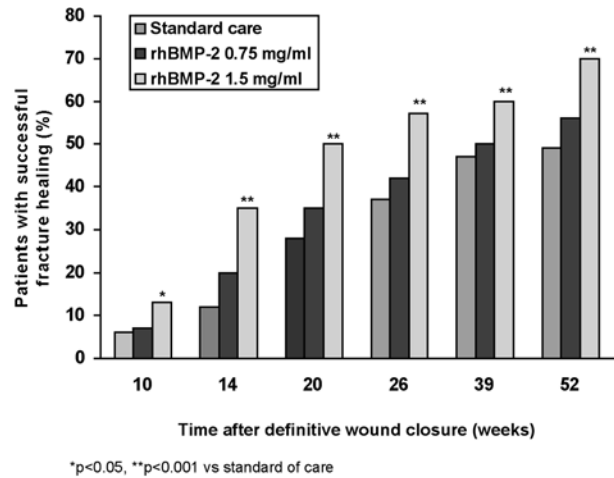


Fig. 5. — Rate of fracture healing for patients with acute open tibial fracture following treatment with rhBMP-2 0.75 or 1.5 mg/ml or standard care (26). Reproduced with kind permission from Govender S, Csimma C, Genant HK *et al.* Recombinant human bone morphogenetic protein-2 for treatment of open tibial fractures: a prospective, controlled, randomised study of four hundred and fifty patients. BMP-2 Evaluation in Surgery for Tibial Trauma (BESTT) Study Group. *J Bone Joint Surg* 2002; 84-A: 2123-2134. © The Journal of Bone and Joint Surgery, Inc.

450 patients with open tibial fracture to investigate the effect of rhBMP-2 plus ACS (0.75 or 1.5 mg/ml), compared with standard care alone (26). The investigators found a significant, dose-dependent decrease in the proportion of patients who required secondary intervention to promote healing in the groups receiving rhBMP-2 (0.75 and 1.5 mg/ml), compared with the standard care group (37% and 26% vs 46%; $p = 0.0004$). The risk of secondary intervention was reduced by 44% in patients receiving rhBMP-2 (1.5 mg/ml) compared with standard care alone ($p = 0.0005$). Similarly, fewer invasive secondary interventions were required in this group: a relative risk reduction of 52% in the invasive intervention rate ($p = 0.0264$).

Fracture healing (based on both clinical and radiological assessment) was significantly accelerated in the rhBMP-2 (1.5 mg/ml) group, compared with standard care – an effect that was seen from 10 weeks to 12 months after definitive wound closure ($p = 0.0008$) (fig 5). Indeed, there was a 39-day difference between the time at which fracture healing

occurred in 50% of patients within these groups (145 vs 184 days, respectively). The infection rate at the fracture site was similar overall between the treatment groups. However, it was significantly lower in patients with the most severe injuries (Gustilo-Anderson type-III A and IIIB) treated with rhBMP-2 (1.5 mg/ml) than those treated with standard care (24% vs 44% ; $p = 0.0219$). Healing of tibial fractures is classically prolonged in the presence of infection (24, 30). It might be hypothesised, therefore, that in addition to its direct effects on bone morphogenesis, the angiogenic effect of rhBMP-2 may increase protection against infection and thus play an indirect role in acceleration of the healing process. Observed statistically significant differences in terms of wound healing rate and pain that favoured rhBMP-2 (1.5 mg/ml) also suggest evidence of increased vascular supply. More rapid wound healing will also help to protect against infection.

A clinical study programme is underway to evaluate the use of injectable carriers for rhBMP-2, which could extend their use to treatment of patients with closed fractures (*reviewed in 66*).

CONCLUSIONS

Recombinant human BMP-2 plus ACS appears to offer an effective alternative to autogenous bone graft for spinal interbody fusion procedures, and is capable of producing rates of fusion that equal or exceed those seen with autogenous bone graft, whilst obviating the need for iliac crest bone grafts and associated donor site morbidity. Additional advantages associated with a single surgical site are apparent to both the patient and surgeon, and are reflected by shorter operative times, reduced operative blood loss, and less prolonged periods of time spent in hospital. In addition, rhBMP-2 plus ACS has a positive effect on the healing of fresh tibia fractures, thereby avoiding potential future requirements for bone grafts. The effect of rhBMP-2 plus ACS on nonunions in long bones remains to be determined.

Given the results of the clinical trial programme, hospital and payer models need to be developed to assess the economic impact of using rhBMP-2 plus

ACS therapy instead of autogenous iliac crest bone graft. In the USA, economic models for a single level ALIF have been published (1, 54). The findings suggest that a substantial portion of the additional cost of rhBMP-2 plus ACS therapy may be offset by the elimination of complications associated with iliac crest bone graft harvesting, and by reduced surgery, anaesthesia, recovery times, decreased blood loss, shorter in-patient stays, and decreased use of autogenous graft extenders / harvesters and medical / surgical supplies. These models must now be extended to evaluate the comparative effects of rhBMP-2 plus ACS and autogenous bone graft on health-related quality of life and lost productivity in order to estimate the true cost-benefit of rhBMP-2 plus ACS therapy.

REFERENCES

1. Ackerman SJ, Mafilios MS, Polly DW Jr. Economic evaluation of bone morphogenetic protein versus autogenous iliac crest bone graft in single-level anterior lumbar interbody fusion : an evidence-based modeling approach. *Spine* 2002 ; 27 : S94-S99.
2. Akamuru T, Suh D, Boden SD *et al.* Simple carrier matrix modifications can enhance delivery of recombinant human bone morphogenetic protein-2 for posterolateral spine fusion. *Spine* 2003 ; 28 : 429-434.
3. Arrington ED, Smith WJ, Chambers HG *et al.* Complications of iliac crest bone graft harvesting. *Clin Orthop* 1996 ; 329 : 300-309.
4. Banwart JC, Asher MA, Hassanein RS. Iliac crest bone graft harvest donor site morbidity. A statistical evaluation. *Spine* 1995 ; 20 : 1055-1060.
5. Boden SD, Martin GJ, Morone MA *et al.* Posterolateral lumbar intertransverse process spine arthrodesis with recombinant human bone morphogenetic protein 2/hydroxyapatite-tricalcium phosphate after laminectomy in the nonhuman primate. *Spine* 1999 ; 24 : 1179-1185.
6. Boden SD, Kang J, Sandhu H, Heller JG. Use of recombinant human bone morphogenetic protein-2 to achieve posterolateral lumbar spine fusion in humans : a prospective, randomized clinical pilot trial : 2002 Volvo Award in clinical studies. *Spine* 2002 ; 27 : 2662-2673.
7. Boden SD, Martin GJ Jr, Horton WC *et al.* Laparoscopic anterior spinal arthrodesis with rhBMP-2 in a titanium interbody threaded cage. *J Spinal Disord* 1998 ; 11 : 95-101.
8. Boden SD, Zdeblick TA, Sandhu HS, Heim SE. The use of rhBMP-2 in interbody fusion cages. Definitive evidence of osteoinduction in humans : a preliminary report. *Spine* 2000 ; 25 : 376-381.

9. **Boden SD.** The biology of posterolumbar spinal fusion. *Orthop Clin North Am* 1998 ; 29 : 603-619.
10. **Burkus JK, Dorchak JD, Sanders DL.** Radiographic assessment of interbody fusion using recombinant human bone morphogenetic protein type 2. *Spine* 2003 ; 28 : 372-377.
11. **Burkus JK, Gornet MF, Dickman CA, Zdeblick TA.** Anterior lumbar interbody fusion using rhBMP-2 with tapered interbody cages. *J Spinal Disord Tech* 2002 ; 15 : 337-349.
12. **Burkus JK, Heim SE, Gornet MF, Zdeblick TA.** Is INFUSE bone graft superior to autogenous bone graft bone ? An integrated analysis of clinical trials using the LT-CAGE lumbar tapered fusion device. *J Spinal Disord Tech* 2003 ; 16 : 113-122.
13. **Burkus JK, Transfeldt EE, Kitchel SH et al.** Clinical and radiographic outcomes of anterior lumbar interbody fusion using recombinant human bone morphogenetic protein-2. *Spine* 2002 ; 27 : 2396-2408.
14. **Centers for Disease Control and Prevention.** Invasive streptococcus pyogenes after allograft implantation. *MMWR* 2003 ; 52 : 1173-1176.
15. **Cheng H, Jiang W, Phillips FM et al.** Osteogenic activity of the fourteen types of human bone morphogenetic proteins (BMPs). *J Bone Joint Surg* 2003 ; 85-A : 1544-1552.
16. **Cheng SL, Lou J, Wright NM et al.** In vitro and in vivo induction of bone formation using a recombinant adenoviral vector carrying the human BMP-2 gene. *Calcif Tissue Int* 2001 ; 68 : 87-94.
17. **Colterjohn NR, Bednar DA.** Procurement of bone graft from the iliac crest. An operative approach with decreased morbidity. *J Bone Joint Surg* 1997 ; 79-A : 756-759.
18. **Deckers MM, van Bezoijen RT, van der Horst G et al.** Bone morphogenetic proteins stimulate angiogenesis through osteoblast-derived vascular endothelial growth factor A. *Endocrinology* 2002 ; 143 : 1545-1553.
19. **Dijke (ten) P, Fu J, Schaap P, Roelen BA.** Signal transduction of bone morphogenetic proteins in osteoblast differentiation. *J Bone Joint Surg* 2003 ; 85-A (Suppl 3) 34-38.
20. **Fernyhough JC, Schimandle JJ, Weigel MC et al.** Chronic donor site pain complicating bone graft harvesting from the posterior iliac crest for spinal fusion. *Spine* 1992 ; 17 : 1474-1480.
21. **Fritzell P, Hagg O, Wessberg P, Nordwall A ; Swedish Lumbar Spine Study Group.** Lumbar fusion versus non-surgical treatment for chronic low back pain : a multicenter randomized controlled trial from the Swedish Lumbar Spine Study Group. *Spine* 2001 ; 26 : 2521-2532.
22. **Fritzell P, Hagg O, Wessberg P, Nordwall A ; Swedish Lumbar Spine Study Group.** Chronic low back pain and fusion : a comparison of three surgical techniques : a prospective multicenter randomized study from the Swedish lumbar spine study group. *Spine* 2002 ; 27 : 1131-1141.
23. **Gerhart TN, Kirker-Head CA, Kriz MJ et al.** Healing segmental femoral defects in sheep using recombinant human bone morphogenetic protein. *Clin Orthop* 1993 ; 293 : 317-326.
24. **Goulet J, Bray TJ.** Nonunions and malunions of the tibia. In : Chapman MW, (ed) *Operative Orthopaedics*. JB Lippincott, Philadelphia, 1988, pp 581-596.
25. **Goulet JA, Senunas LE, DeSilva GL, Greenfield MLVH.** Autogenous iliac crest bone grafts. Complications and functional assessment. *Clin Orthop* 1997 ; 339 : 76-81.
26. **Govender S, Csimma C, Genant HK et al.** Recombinant human bone morphogenetic protein-2 for treatment of open tibial fractures : a prospective, controlled, randomized study of four hundred and fifty patients. BMP-2 Evaluation in Surgery for Tibial Trauma (BESTT) Study Group. *J Bone Joint Surg* 2002 ; 84-A : 2123-2134.
27. **Haid RW, Branch CL, Alexander JT, Burkus JK.** Posterior lumbar interbody fusion using recombinant human bone morphogenetic protein type 2 with cylindrical interbody cages. *Spine J* 2004 ; 4 : 527-539.
28. **Heary RF, Schlenk RP, Sacchieri TA et al.** Persistent iliac crest donor site pain : independent outcome assessment. *Neurosurgery* 2002 ; 50 : 510-517.
29. **Hecht BP, Fischgrund JS, Herkowitz HN et al.** The use of recombinant human bone morphogenetic protein 2 (rhBMP-2) to promote spinal fusion in a nonhuman primate anterior interbody fusion model. *Spine* 1999 ; 24 : 629-636.
30. **Heppenstall RB, Brighton CT, Esterhai JL Jr, Muller G.** Prognostic factors in nonunion of the tibia : an evaluation of 185 cases treated with constant direct current. *J Trauma* 1984 ; 24 : 790-795.
31. **Jaworski ZFG, Duck B, Sekaly G.** Kinetics of osteoclasts and their nuclei in evolving secondary Haversian systems. *J Anat* 1981 ; 133 : 397-405.
32. **Kamin IEA, Bae H, Zhao L et al.** Inter and intravariability of BMPs in commercially available demineralised bone matrices. Proceedings of the NASS 18th Annual Meeting. *Spine J* 2003 ; 3 : 81S.
33. **Kawabata M, Miyazono K.** Bone morphogenetic proteins. In : Canalis E (ed) *Skeletal Growth Factors*, Lippincott Williams & Wilkins, Philadelphia, 2000, pp 269-290.
34. **Khan SN, Lane JM.** The use of recombinant human bone morphogenetic protein-2 (rhBMP-2) in orthopaedic applications. *Expert Opin Biol Ther* 2004 ; 4 : 741-748.
35. **Kleeman TJ, Ahn UM, Talbot-Kleeman A.** Laparoscopic anterior lumbar interbody fusion with rhBMP-2 : a prospective study of clinical and radiographical outcomes. *Spine* 2001 ; 26 : 2751-2756.
36. **Kokubo S, Fujimoto R, Yokota S et al.** Bone regeneration by recombinant human bone morphogenetic protein-2 and a novel biodegradable carrier in a rabbit ulnar defect model. *Biomaterials* 2003 ; 24 : 1643-1651.

37. **Kuklo TR, Rosner MK, Polly DW jr.** Computerized tomography evaluation of a resorbable implant after transforaminal lumbar interbody fusion. *Neurosurg Focus* 2004 ; 16 : 1-6.
38. **Lanman TH, Hopkins TJ.** Lumbar interbody fusion after treatment with recombinant human bone morphogenetic protein-2 added to poly (L-lactide-co-D, L-lactide) bioresorbable implants. *Neurosurg Focus* 2004 ; 16 : E9.
39. **Liao SS, Guan K, Cui FZ et al.** Lumbar spinal fusion with a mineralized collagen matrix and rhBMP-2 in a rabbit model. *Spine* 2003 ; 28 : 1954-1960.
40. **Linovitz RJ, Peppers TA.** Use of an advanced formulation of beta-tricalcium phosphate as a bone extender in interbody lumbar fusion. *Orthopedics* 2002 ; 25s : 585-589.
41. **Ludwig SC, Boden SD.** Osteoinductive bone graft substitutes for spinal fusion : a basic science summary. *Orthop Clin North Am* 1999 ; 30 : 635-645.
42. **Luque E.** Latest clinical results using demineralised bone materials and rhBMP-2 : the Mexican experience. *Read at Total Spine : Advanced Concepts and Constructs 2002, Cancun, Mexico.*
43. **Martin GJ jr, Boden SD, Morone MA, Moskovitz PA.** Posterolateral intertransverse process spinal arthrodesis with rhBMP-2 in a non-human primate : important lessons learned regarding dose, carrier, and safety. *J Spinal Disord* 1999 ; 12 : 179-186.
44. **Matsuo T, Sugita T, Kubo T et al.** Injectable magnetic liposomes as a novel carrier of recombinant human BMP-2 for bone formation in a rat bone-defect model. *J Biomed Mater Res* 2003 ; 66 : 747-754.
45. **Minamide A, Akamaru A, Ugbo JI, Boden SD.** Use of rhBMP-2 supplemented with allograft bone chips in posterolateral fusions in nonhuman primates. *Annual Meeting of the North American Spine Society.* Seattle, WA, USA (31 October – 3 November 2001).
46. **Miyazono K.** Signal transduction by bone morphogenetic protein receptors : functional roles of Smad proteins. *Bone* 1999 ; 25 : 91-93.
47. **Mori S, Yoshikawa H et al.** Inhibition by anti-angiogenic agent (TNP-470) of ectopic bone formation induced by bone morphogenetic protein-2. *Bone* 1995 ; 17 : 569.
48. **Mori S, Yoshikawa H, Hashimoto J et al.** Antiangiogenic agent (TNP-470) inhibition of ectopic bone formation induced by bone morphogenetic protein-2. *Bone* 1998 ; 22 : 99-105.
49. **Morone MA, Boden SD.** Experimental posterolateral lumbar spinal fusion with a demineralized bone matrix gel. *Spine* 1998 ; 23 : 159-167.
50. **Moutsatsos IK, Turgeman G, Zhou S et al.** Exogenously regulated stem cell-mediated gene therapy for bone regeneration. *Mol Ther* 2001 ; 3 : 449-461.
51. **Mummaneni PV, Haid RW, Rodts GE.** Lumbar interbody fusion : state-of-the-art technical advances. Invited submission from the Joint Section Meeting on Disorders of the Spine and Peripheral Nerves, March 2004. *J Neurosurg Spine* 2004 ; 1 : 24-30.
52. **Mummaneni PV, Pan J, Haid RW, Rodts GE.** Contribution of recombinant human bone morphogenetic protein-2 to the rapid creation of interbody fusion when used in transforaminal lumbar interbody fusion : a preliminary report. Invited submission from the Joint Section Meeting on Disorders of the Spine and Peripheral Nerves, March 2004. *J Neurosurg Spine* 2004 ; 1 : 19-23.
53. **Murakami N, Saito N, Horiuchi H et al.** Repair of segmental defects in rabbit humeri with titanium fiber mesh cylinders containing recombinant human bone morphogenetic protein-2 (rhBMP-2) and a synthetic polymer. *J Biomed Mater Res* 2002 ; 62 : 169-174.
54. **Polly DW Jr, Ackerman SJ, Shaffrey CI et al.** A cost analysis of bone morphogenetic protein versus autogenous iliac crest bone graft in single-level anterior lumbar fusion. *Orthopedics* 2003 ; 26 : 1027-1037.
55. **Prolo DJ, Rodrigo JJ.** Contemporary bone graft physiology and surgery. *Clin Orthop* 1985 ; 200 : 322-342.
56. **Riedel GE, Valentin-Opran A.** Clinical evaluation of rhBMP-2/ACS in orthopedic trauma : a progress report. *Orthopedics* 1999 ; 22 : 663-665.
57. **Riew KD, Wright NM, Cheng S et al.** Induction of bone formation using a recombinant adenoviral vector carrying the human BMP-2 gene in a rabbit spinal fusion model. *Calcif Tissue Int* 1998 ; 63 : 357-360.
58. **Riley EH, Lane JM, Urist MR et al.** Bone morphogenetic protein-2 : biology and applications. *Clin Orthop* 1996 ; 324 : 39-46.
59. **Rodriguez WJ, Coakley MB.** Basic bone biology. Training and development. Medtronic 2002.
60. **Sandhu HS, Kanim LEA, Kabo JM et al.** Effective doses of recombinant human bone morphogenetic protein-2 in experimental spinal fusion. *Spine* 1996 ; 21 : 2115-2122.
61. **Sandhu HS, Khan SN.** Recombinant human bone morphogenetic protein-2 : use in spinal fusion applications. *J Bone Joint Surg* 2003 ; 85-A (Suppl 3) : 89-95.
62. **Sandhu HS, Toth JM, Diwan AD et al.** Histologic evaluation of the efficacy of rhBMP-2 compared with autograft bone in sheep spinal anterior interbody fusion. *Spine* 2002 ; 27 : 567-575.
63. **Sawin PD, Traynelis VC, Menezes AH.** A comparative analysis of fusion rates and donor-site morbidity for autogeneic rib and iliac crest bone grafts in posterior cervical fusions. *J Neurosurg* 1998 ; 88 : 255-265.
64. **Schimandle JH, Boden SD, Hutton WC.** Experimental spinal fusion with recombinant human bone morphogenetic protein-2. *Spine* 1995 ; 20 : 1326-1337.
65. **Sciadini MF, Johnson KD.** Evaluation of recombinant human bone morphogenetic protein-2 as a bone-graft substitute in a canine segmental defect model. *J Orthop Res* 2000 ; 18 : 289-302.
66. **Seeherman H, Li R, Wozney J.** A review of preclinical program development for evaluating injectable carriers for

- osteogenic factors. *J Bone Joint Surg* 2003 ; 85-A (Suppl 3) : 96-108.
67. **Suh DY, Boden SD, Louis-Ugbo J et al.** Delivery of recombinant human bone morphogenetic protein-2 using a compression-resistant matrix in posterolateral spine fusion in the rabbit and in the non-human primate. *Spine* 2002 ; 27 : 353-360.
68. **Suh DY, Boden SD, Ugbo JL.** Use of rhBMP-2 supplemented with allograft bone chips in posterolateral fusions in nonhuman primates. *Annual Meeting of the American Academy of Orthopedic Surgeons*. Dallas, TX, USA (13-17 February 2002).
69. **Summers BN, Eisenstein SM.** Donor site pain from the ilium. A complication of lumbar spine fusion. *J Bone Joint Surg* 1989 ; 71-B : 677-680.
70. **Sun TS, Guan K, Shi SS et al.** Effect of nano-hydroxyapatite/collagen composite and bone morphogenetic protein-2 on lumbar intertransverse fusion in rabbits. *Chin J Traumatol* 2004 ; 7 : 18-24.
71. **Szpalski M, Gunzburg R.** Use of a novel beta-tricalcium phosphate-based bone void filler as a graft extender in spinal fusion surgeries. *Orthopedics* 2002 ; 25 : s591-s595.
72. **Takita H, Kikuchi M, Sato Y, Kuboki Y.** Inhibition of BMP-induced ectopic bone formation by an antiangiogenic agent (epigallocatechin 3-gallate). *Connect Tissue Res* 2002 ; 43 : 520-523.
73. **Termaat MF, Blokhuis TJ, Den Boer FC et al.** The role of bone morphogenetic proteins in bone healing. *Osteo Trauma Care* 2003 ; 11 : 122-125.
74. **Trotter JF.** Transmission of hepatitis C by implantation of a processed bone graft. A case report *J Bone Joint Surg* 2003 ; 85-A : 2215-2217.
75. **Urist MR, Strates BS.** Bone morphogenetic protein. *J Dent Res* 1971 ; 50 : 1392-1406.
76. **Valentin-Opran A, Wozney J, Csimma C et al.** Clinical evaluation of recombinant human bone morphogenetic protein-2. *Clin Orthop* 2002 ; 395 : 110-120.
77. **Welch RD, Jones AL, Bucholz RW et al.** Effect of rhBMP-2 on fracture healing in a goat tibial fracture model. *J Bone Miner Res* 1998 ; 13 : 1483-1490.
78. **Wozney JM, Rosen V.** Bone morphogenetic protein and bone morphogenetic protein gene family in bone formation and repair. *Clin Orthop* 1998 ; 346 : 26-37.
79. **Younger EM, Chapman MW.** Morbidity at bone graft donor sites. *J Orthop Trauma* 1989 ; 3 : 192-195.
80. **Zdeblick TA, Heim SE, Kleeman TI et al.** Laparoscopic approach with tapered metal cages : rhBMP-2 versus autogenous bone graft. *Annual Meeting of the North American Spine Society*. Seattle, WA, USA (31 Oct-3 Nov 2001).