

CASE REPORT

DISSOCIATION OF THE S-ROM* METAL-BACKED POLYETHYLENE ACETABULAR LINER – A CASE REPORT AND LITERATURE REVIEW

H. P. BHINDA, S. P. SARKAR

The authors report a case of early failure of a total hip arthroplasty with dissociation of the polyethylene liner of an S-ROM Oblong Cup*, which presented as a dislocation. Initial closed reduction of the dislocation was not possible. Open exploration of the hip revealed that the modular Poly Dial* polyethylene acetabular liner had become dislodged from the acetabular cup. The liner was revised and a stable reduction of the hip was achieved. To our knowledge, no previous case of dissociation of the polyethylene liner from the S-ROM Oblong acetabular component has been reported. A review of the literature with other relevant cases is presented.

CASE REPORT

A 75-year-old man was admitted with an apparent dislocation of a right total hip arthroplasty. There was no history of trauma or a fall. He had undergone acetabular revision to an S-ROM Oblong Cup nine months previously. He had been asymptomatic during the ensuing period. Clinical examination revealed no shortening or rotation of the limb, but he was unable to weight-bear or move the hip due to pain. Radiographs obtained on admission showed a dislocation with the femoral head in a superolateral position (fig 1). An attempt was made at closed reduction under general anaesthesia. A more concentric position of the femoral head was obtained, but the hip could not be fully reduced (fig 2).

At open exploration the femoral head was found to be concentrically located within the modular Poly Dial polyethylene acetabular liner. The liner

itself had become disengaged from its metal backing within the S-ROM Oblong acetabular cup. Examination of the liner revealed irregularity of the slots around the rim where it had been attached to the cup with peripheral screws (fig 3). The liner was revised and a stable reduction of the hip was achieved. Post-operative recovery was uneventful and the patient subsequently mobilised successfully.

DISCUSSION

The increasingly widespread use of modular implants in total hip arthroplasty has led to the recognition of new modes of implant failure. Concerns have previously been raised in the literature regarding the potential modes of failure associated with two-piece acetabular implants (1). These have included dissociation, fracture and polyethylene wear.

Wilson *et al* (6) first reported a case of disassembly of acetabular components in 1988, which occurred several weeks postoperatively after the patient fell. Ferenz (3), also in 1988, reported dislocation of the polyethylene insert in an Anderson screw-in acetabular cup after the patient fell on the third postoperative day. He suggested that a radiographic marker be constructed into all polyethylene

From the Department of Orthopaedics, Southend Hospital, Prittlewell Chase, Southend on Sea, Essex SS0 0RY, UK.

Correspondence and reprints : Hans P. Bhinda, 16 Cheltenham Court, Dexter Close, St Albans, Herts AL1 5WB, UK.
E-mail : hansbhinda@hotmail.com.

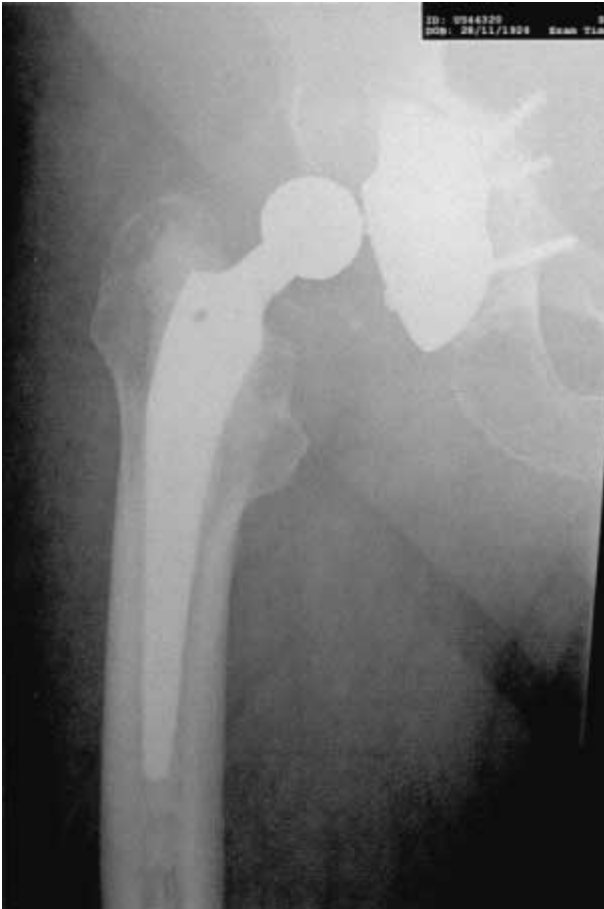

Fig. 1. — Radiograph showing dislocation of the total hip arthroplasty with the femoral head in a superolateral position.

inserts to facilitate easier recognition of this complication in the presence of subtle clinical and radiological signs. Bueche *et al* (2), in 1989, described a case of dissociation of a SPECTRON metal-backed polyethylene acetabulum (Richards Medical, Memphis, TN, USA) which occurred four months postoperatively without trauma. They attributed this to failure of the snap-fit rim of the polyethylene liner, which they believed may have been subjected to failure by cold flow deformation and cyclic loading. The authors acknowledge other cases of failure of that component detailed in personal communications, and that the design of the polyethylene insert had since been altered to prevent its disassembly. A similar case was described

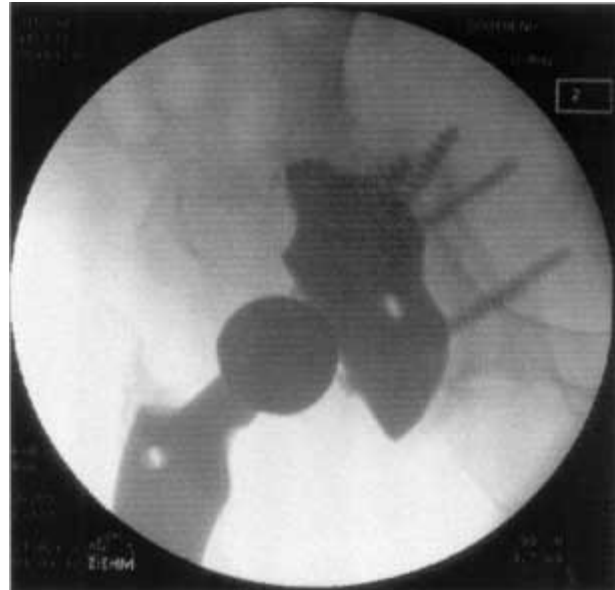


Fig. 2. — Image intensifier film after attempted closed reduction. The femoral head is in a more concentric position, but the hip is not fully reduced.




Fig. 3. — The dissociated polyethylene liner. Examination of the liner revealed irregularity of the slots around the rim where it had been attached to the cup with peripheral screws.

by Kitziger *et al* (4) in 1990, involving a universal porous coated press-fit cup with a snap-fit liner (Biomet, Warsaw, Indiana, USA) and occurring on the twenty-sixth postoperative day.

Most recently, O'Brien and Chess (5) in 1992 reported disassembly of a modular acetabular component (Howmedica, Rutherford, NJ, USA) which occurred six months after surgery. The authors attributed this to fatigue failure of the locking flange on the posterior aspect of the plastic liner, allowing it to subluc out of the metal cup.

These cases highlight the significance of modular acetabular polyethylene insert disassembly as a cause of pain or dislocation after total hip arthroplasty. Early recognition of this phenomenon, in the presence of sometimes subtle clinical and radiological signs, is an important predictor for the need to proceed to open exploration and possibly revision surgery.

To our knowledge this is the first reported case of disassembly with the S-ROM Oblong cup and Poly Dial liner.

The recognition of such component failures is an essential aspect of the surveillance and evaluation of new implants, and serves to highlight potential limitations and areas for improvement in implant design. In the current case, the method of fixation of the liner to the metal cup proved to be an area of concern.

Rigorous biomechanical analysis is needed to assess the mechanisms and forces required to bring about disassembly of these components, with a view to improving their design. Bobyn *et al* (1) have evaluated the mechanical limitations and fretting behaviour of the S-ROM femoral stem, by subjecting it to wet environment high cycle mechanical testing in a worst-case loading scenario. Similar studies could usefully be applied in the assessment of the mechanical properties of the S-ROM acetabular components.

REFERENCES

1. **Bobyn JD, Tanzer M, Krygier JJ, Dujovnie AR, Brooks CE.** Concerns with modularity in total hip arthroplasty. *Clin Orthop* 1994 ; 298 : 27-36
2. **Bueche MJ, Herzenberg JE, Stubbs BT.** Dissociation of a metal-backed polyethylene acetabular component. A case report. *J Arthroplasty* 1989 ; 4 : 39-41
3. **Ferez CC.** Polyethylene insert dislocation in a screw-in acetabular cup. A case report. *J Arthroplasty* 1988 ; 3 : 201-204
4. **Kitziger KJ, DeLee JC, Evans A.** Disassembly of a modular acetabular component of a total hip arthroplasty. A case report. *J Bone Joint Surg* 1990 ; 72 : 621-623
5. **O'Brien RE, Chess D.** Late disassembly of a modular acetabular component. *J Arthroplasty* 1992 ; 7 (suppl.) : 453-455
6. **Wilson AJ, Monsees B, Blair VP.** Acetabular cup dislocations : a new complication of total joint arthroplasty. *Am J Roentgenol* 1988 ; 151 : 133