

CASE REPORT

COMBINED FRACTURE OF THE DISTAL RADIUS AND SCAPHOID IN CHILDREN. REPORT OF 2 CASES

M. SMIDA, K. NIGROU, T. SOOHUN, R. SALLEM, C. JALEL, M. BEN GHACHEM

The authors report 2 cases of concomitant scaphoid and distal radial fractures, a rare combination of lesions in children.

The first case was in a 13-year-old boy who presented a transverse midscaphoid fracture associated with a Salter type II distal radial fracture. The second concerned a 10-year-old boy who presented a bilateral wrist injury. On the left side, a distal forearm fracture with anterior displacement was associated with a transverse midscaphoid fracture. On the right side, there was only a distal forearm fracture.

Scaphoid fracture associated with distal radial fracture seems to have been more frequently reported in the literature during the last decade, probably because it is more frequently recognised. In fact, children with distal forearm injury should be well examined both clinically and radiologically in order to search for an associated scaphoid fracture. Reduction of the radius fracture should be done carefully to avoid possible displacement of the scaphoid fracture.

INTRODUCTION

Scaphoid fractures are rare prior to the age of 15, with a peak incidence between the ages 15 and 30 years. Ossification of the scaphoid begins at 5 to 6 years of age and is not complete until 13 to 15 years of age. Because the scaphoid is largely cartilaginous in children, it is rarely injured (1).

The association of distal radial and scaphoid fractures has been well described in adults (6). In children however, only a few cases have been reported (1, 3, 4, 7, 8).

CASES REPORT

Case 1

Following a road traffic accident, a 13-year-old boy complained of local pain and deformity of the distal end of the right forearm. Clinical examination revealed swelling over the dorsal aspect of the wrist. No other injuries were associated. Antero-posterior and lateral wrist X-rays showed a Salter type II distal radial fracture with dorsal displacement associated with an undisplaced transverse midscaphoid fracture (fig 1).

Immediate reduction of the distal radial fracture was performed and the wrist was immobilised in a long arm thumb cast for 3 months. After a follow-up of 6 months, clinical examination showed a full painless range of motion of the wrist and X-rays showed healing of both fractures.

Case 2

A 10-year-old boy sustained a bilateral wrist injury following a fall from a height of 2 meters. Roentgenograms showed a distal forearm fracture on the right side and, on the left side, a distal forearm fracture with anterior displacement associated

Tunis Children's Hospital, Department of Pediatric Orthopaedics, Tunis, Tunisia.

Correspondence and reprints : Mahmoud Smida, Department of Pediatric Orthopaedics, Tunis Children's Hospital (Hôpital d'Enfants de Tunis), Bab Saadoun 1007 Tunis, Tunisia. E-mail : mahmoud.smida@rns.tn.

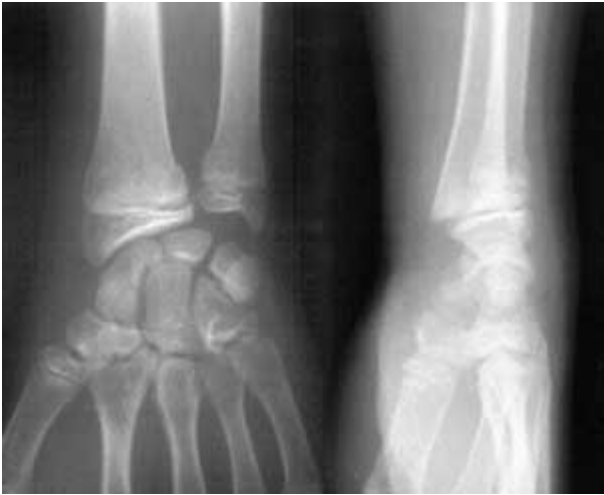

Fig. 1. — Salter type II distal radial fracture associated with a midscaphoid transverse fracture (case 1).

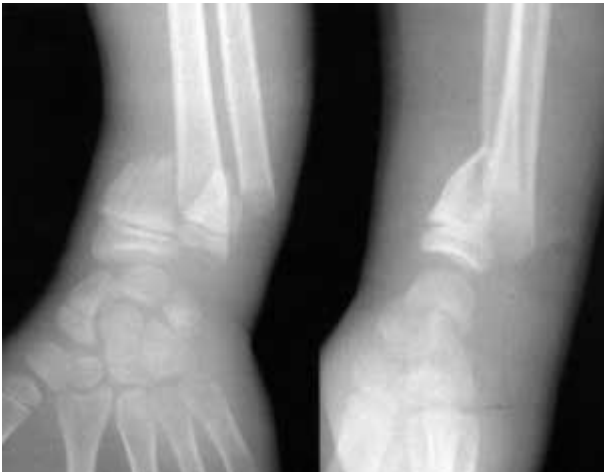


Fig. 2. — Distal forearm fracture with anterior displacement associated with a midscaphoid transverse fracture (case 2).

with an undisplaced midscaphoid transverse fracture (fig 2). Both fractures were reduced under general anaesthesia. The total period of immobilisation was 3 months, using a large arm thumb cast on the left side and a long arm cast on the right side for 45 days. At 6-month follow-up, the result was good with full function of both wrists (fig 3).

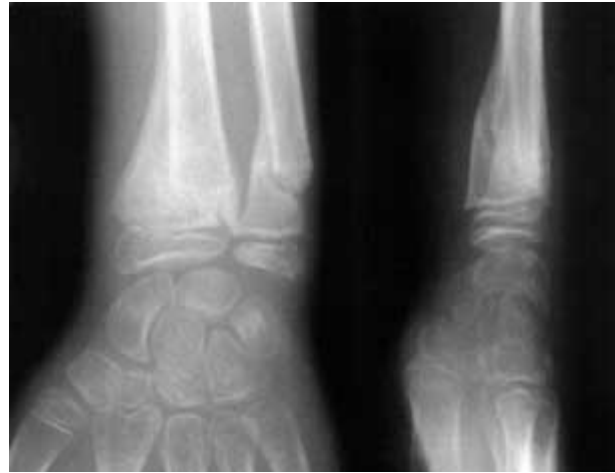


Fig. 3. — At 3 months : healing of fractures with relative malalignment (case 2).

DISCUSSION

Children have a relatively resistant ligamentous and cartilaginous carpus with an area of weakness at the distal radial physis, which is more prone to injury. Therefore, scaphoid fractures in children require a greater causal force.

Until 10 to 15 years ago, few cases of ipsilateral distal radial fracture and scaphoid fracture in children were reported in the literature. In 1984, Green *et al* reviewed 196 distal radial fractures in children between the ages of 4 and 15 years and did not find associated scaphoid fractures (5). In 1986, Christodoulou and Cotton reviewed 77 children below 15 years of age with scaphoid fractures and found no case of associated ipsilateral distal radial fracture (2). In a series of 108 carpal scaphoid fractures in children published in 1980, Vahvanen and Westerlund reported only 3 cases of associated distal radial fracture (8). In 1982, Ganble and Simmons reported the case of an 8 year-old-boy with a bilateral scaphoid fracture associated with a radial epiphyseal fracture (4). In our department of Pediatric Orthopaedics, we have only observed these 2 reported cases during 10 years. This confirms the extreme rarity of these associated injuries in children. This type of combined fracture seems to have been more frequently reported in the last

decade, probably because it is more frequently recognised (1, 7).

Other carpal bone fractures may be associated. Compson reported 3 cases of transcarpal injuries associated with distal radial fractures in children : two cases involved simultaneous fractures of the scaphoid and capitatum, while the third one involved the scaphoid and triquetrum (3).

The occurrence of scaphoid fractures associated with distal radial fractures is possible because of a similar injury mechanism, which is often hyperextension of the wrist. Frequently, a fall on the palm of the outstretched hand causes a distal radial fracture with posterior displacement associated or not with a scaphoid fracture. However, in our second case, we observed an anteriorly displaced distal forearm fracture. This is probably due to a vertical axial compression mechanism with hyperextension of the wrist. To our knowledge, there are no reports in the literature of such associated fractures with anterior displacement of the distal radial extremity.

Associated scaphoid fractures should therefore be suspected with all types of distal forearm injuries in children. All authors stressed the fact that such association of fractures should be recognised, in order to be more careful during the initial management (1). Careless reduction techniques may indeed cause displacement of the scaphoid fracture (1, 7). Immobilisation in a long-arm thumb cast for 3 months is necessary for the treatment of such injuries, allowing uncomplicated healing of the fractures.

CONCLUSION

Combined fractures of the scaphoid and distal radius are rare in children, but are more and more frequently recognised nowadays.

Because the mechanism of injury is similar for both fractures, it is important to have a high index of suspicion for their association.

Reduction manoeuvres for distal radial fractures should be done carefully to avoid displacement of the scaphoid fracture.

REFERENCES

1. **Albert MC, Barre PS.** A scaphoid fracture associated with a displaced distal radial fracture in a child. *Clin Orthop* 1989 ; 240 : 232-235
2. **Christodoulou AG, Cotton CL.** Scaphoid fractures in children. *J Pediatr Orthop* 1986 ; 6 : 37-39
3. **Compson JP.** Trans-carpal injuries associated with distal radial fractures in children : a series of three cases. *J Hand Surg* 1992 ; 17-B : 311-314
4. **Ganble JG, Simmons SC.** Bilateral scaphoid fractures in a child. *Clin Orthop* 1982 ; 162 : 125-128
5. **Greene MH, Hadied AM, LaMont RL.** Scaphoid fractures in children. *J Hand Surg* 1984 ; 9-A : 536-541
6. **Stofter IG.** A report of three cases of simultaneous Colles' and scaphoid fractures. *Injury* 1976 ; 7 : 185-188
7. **Tawil HJ, Dumas L, Zercly B, Jacob P, Heissler P.** Fracture du scaphoïde associée à une fracture de l'extrémité inférieure du radius chez l'enfant. A propos d'un cas. *Rev Chir Orthop* 1995 ; 81 : 741-744
8. **Vahvanen V, Westerlund M.** Fracture of the carpal scaphoid in children. A clinical and roentgenological study of 108 cases. *Acta Orthop Scand* 1980 ; 51 : 909-913