



The Ilizarov Technique in joint contractures and dislocations

Yehuda ULLMANN, Lucian FODOR, Michael SOUDRY, Alexander LERNER

From the Rambam Medical Center & Bruce Rapaport Faculty of Medicine, Haifa, Israel

This study was designed to evaluate the results of treatment of joint contractures (6 patients) and dislocations (2 cases) with an Ilizarov device.

Six patients with restricting joint contractures were successfully treated and after gradual scar expansion they achieved a significant improvement in their range of motion. One patient with elbow instability after closed dislocation achieved 5° to 130° of motion, while one patient with an open dislocation achieved a range of motion from 15° to 100°.

These results suggest that a hinged Ilizarov external fixation frame can be a useful tool to restore function in such complex problems.

Keywords : joint contracture ; joint instability ; Ilizarov.

INTRODUCTION

The Ilizarov technique has been well accepted by the western medical community as an efficient method to deal with fractures, particularly those with bone defects. This technique enables closed reduction and stable three-dimensional fixation of displaced bone fragments in fractures, with minimal operative trauma to the skin and surrounding soft tissue. Functional rehabilitation and almost unlimited functional loading of the involved limbs – including full weight bearing in patients with lower limb injuries – can start early in the post-operative period and continue during the whole recovery period.

However, little has been written in the past about the application of this method to solve other than bony problems. In the following report we describe

our experience with the Ilizarov method in the treatment of joint contractures and functional stabilisation of joints.

PATIENTS AND METHODS

Joint contractures (6 cases)

– A 26-year-old man presented with a posttraumatic flexion contracture of the right elbow which had developed over the previous 6 weeks, following a blast injury to his right upper limb which had resulted in an open comminuted Gustilo type 3B fracture of the humerus, ulna and radius. The elbow contracture was treated in a trans-articular circular external fixation frame and was gradually corrected. The construct included medial and lateral hinges that connected the proximal humeral and the distal ulnar external fixation frames. An anteriorly placed long threaded rod with nuts was used to gradual-

■ Yehuda Ullmann, MD, Acting Head of Department.

■ Lucian Fodor, MD, Senior Surgeon.

Department of Plastic and Reconstructive Surgery, Rambam Medical Center & Bruce Rapaport Faculty of Medicine, Haifa, Israel.

■ Michael Soudry, MD, Head of Department.

■ Alexander Lerner, MD, Senior Surgeon.

Department of Orthopaedic Surgery A, Rambam Medical Center & Bruce Rapaport Faculty of Medicine, Haifa, Israel.

Correspondence : Yehuda Ullmann, MD, Department of Plastic Surgery, Rambam Medical Center, Ha'Aliya St. 8, Haifa 31096, Israel.

E-mail : y_ullmann@rambam.health.gov.il

© 2007, Acta Orthopædica Belgica.

Table I. — The characteristics of patients with joint contractures

No	Age, Sex	Area	Aetiology	Pre-OP ROM	Duration of correction (days)	Post-OP ROM	Ext fix time after correction (days)
1	26, M	Elbow	Post-traumatic	40/80	10 d	20/105	60 d
2	10, M	Knee Knee	Post-burn Post-burn	95/130 95/130	21 d 21 d	0/130 0/130	90 d 90 d
3	37, M	Knee	Post-traumatic SG & scarring	40/120	14 d	0/120	30 d
4	23, M	Ankle	Post-traumatic 8 cm tibial elongation SG	70/75	5 d Achillotenotomy	80/100	45 d
5	65, F	Ankle	Post-traumatic avulsion	70/70	7 d Achillotenotomy	75/100	60 d
6	41, M	Ankle	Post-ischemic (compartment syndrome)	65/65	7d Achillotenotomy	85/90	45 d

M – male ; F – female ; SG – skin graft ; Pre OP – preoperative ; Post Op – postoperative.

ly gain passive extension of the joint. The radius was not included in the external frame, which allowed for free pronation and supination of the forearm (table I). A daily correction of 2° was performed.

– A 10-year-old child presented with a 12-month-old post burn flexion contracture of both knees. Trans-articular Ilizarov external fixation frames were built around his knees, and were fixed to the femur and tibia, perpendicular to the diaphyseal axis. Medial and lateral hinges interconnected the circular femoral and the tibial frames. Threaded rods were placed over the posterior aspect of the knees and gradually distracted the scars.

– A 37-year-old adult developed a 40° knee flexion deformity during the four-month period of external fixation of an open (Gustilo type 3A) mid-shaft tibial fracture with laceration in the popliteal area. A standard four-ring Ilizarov external frame was used for closed reduction and external fixation of the tibial fracture. The existing tibial fixation apparatus was extended beyond the knee joint, including an additional ring around the thigh, hinges on the medial and lateral aspect of the knee and a posterior hinge with a long threaded rod used as pusher to gradually extend the contracted scarred knee (table I).

The Ilizarov technique was also used in three patients to correct an equinus deformity of the ankle.

– A 23-year-old male had developed a severe equinus deformity of the ankle during a proximal tibial elongation of 8 cm for bone and soft tissue defects after a gunshot injury (fig 1a, b).

– A 65-year-old woman underwent skin grafting to cover a circumferential skin avulsion from her left leg ;

within a few months, she developed a 70° equinus deformity of the ankle associated with extensive scarring of the leg and the ankle.

– A 41-year-old male patient sustained an open Gustilo type 3B fracture which was complicated by a compartment syndrome of the calf ; he subsequently developed an equinus deformity of the ankle.

These patients were treated by extending the Ilizarov external frame distally with an additional ring around the foot connected by thin wires to the calcaneus and to the metatarsal bones. Rods were placed anteriorly and posteriorly to achieve gradual correction. The ankle joint served as a natural hinge. Gradual correction of the equinus deformity was started immediately after an intraoperative 5 mm ankle distraction. The rate of correction was 1.5° per day. Subcutaneous tenotomy of the Achilles tendon was also needed for these patients due to the severity and duration of the equinus contractures. After achieving the desired correction, the ankle was kept in 90° of flexion for an additional 6 weeks and then the patients were advised to use orthopaedic shoes for one year (table I). An extensive and aggressive excision of the scar tissue was avoided in these three patients suffering from severe ankle contractures.

Joint instability (2 patients)

A 37-year-old woman sustained an open elbow dislocation after a car accident with severe soft tissue contusion and a large skin defect involving the forearm and the arm. During surgical debridement and exploration, a

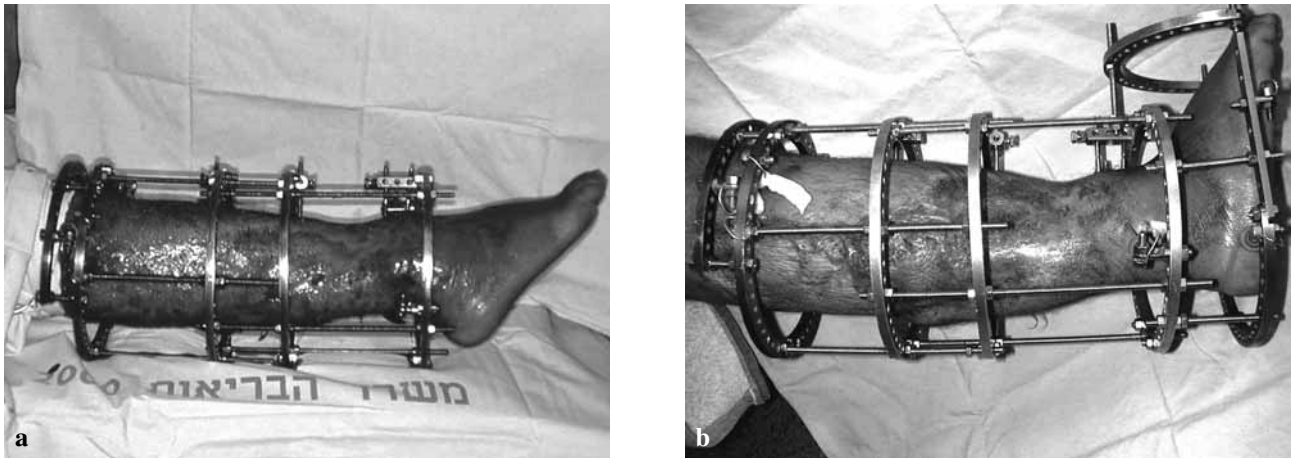


Fig. 1. — a) Clinical aspect on the day of Ilizarov application ; b) Clinical aspect on the day of Ilizarov removal

partial transection of the radial nerve was also noticed. Primary nerve repair was performed and a skin graft was placed on the avulsed area. After reduction a unilateral tubular external frame was used for primary trans-articular fixation. It was exchanged two weeks later to a hinged humero-ulnar unilateral external fixation construct. Flexion, extension, pronation and supination were all preserved after this trans-articular stabilisation and active and assisted passive motions were initiated on the second day after conversion of the rigid external fixation device to the hinged frame.

– After two attempts at closed reduction and cast fixation of a closed postero-lateral elbow dislocation in a 34-year-old man, radiographs showed that the elbow was still subluxed (fig 2a-e). We decided to use an Ilizarov frame to deal with the problem of this post-traumatic elbow instability. The proximal humeral and distal ulnar rings of the fixation frame were interconnected by medial and lateral hinges that were kept in place for 4 weeks. Exercises were started immediately after surgery and at one week after surgery the range of active motion was 15° to 115° with a full range of pronation and supination. After a 1-year follow-up the dislocation remained reduced and a final range of motion (ROM) of 5° - 130° was obtained.

RESULTS

The Ilizarov technique was successfully applied in these eight patients for unconventional indications. The expected goals of the treatment were entirely achieved in all the patients in this series.

Patients with restricting joint contractures were successfully treated and after gradual scar expansion, they achieved a significant improvement in their range of motion (table I). The patient with a severe elbow instability after closed dislocation ended up with a reasonable -5° to 130° range of motion and a full preservation of pronation and supination. A patient with an open dislocation of the elbow achieved 15° to 100° of ROM after one year of follow-up.

No neurovascular complications related with the use of Ilizarov external fixation were recorded. There were no subluxations or dislocations after removing the external fixation frames. Superficial pin tract infections recorded in 4 patients were successfully treated with oral antibiotics and local application of a chlorhexidine solution.

DISCUSSION

The Ilizarov apparatus was originally developed to stabilise fractures, or to correct leg-length discrepancy, bony deformations and bone infections (7, 8). It has been proven useful in the regeneration and growth of tissues (8, 9). Over time, its application was extended also to the treatment of soft tissue problems and joint deformations. The reported deformities that were treated included non traumatic conditions such as melorheostosis (2), haemophilia (6), post-burn contractures (1, 10) and

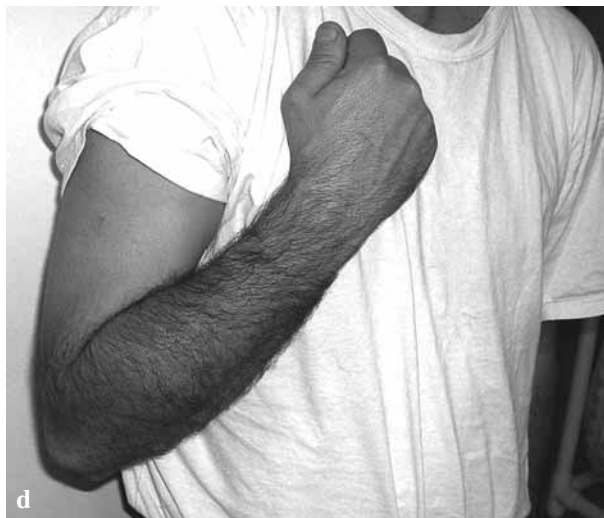
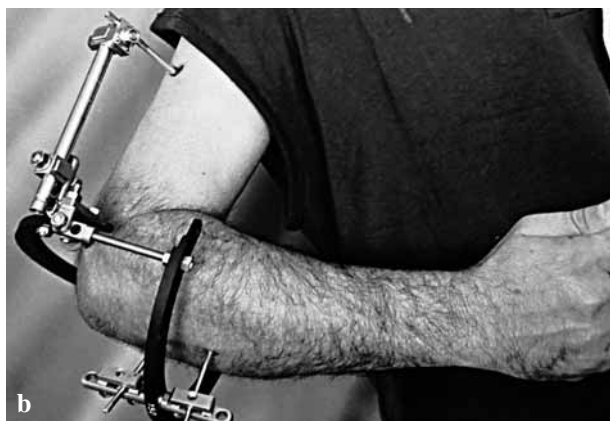
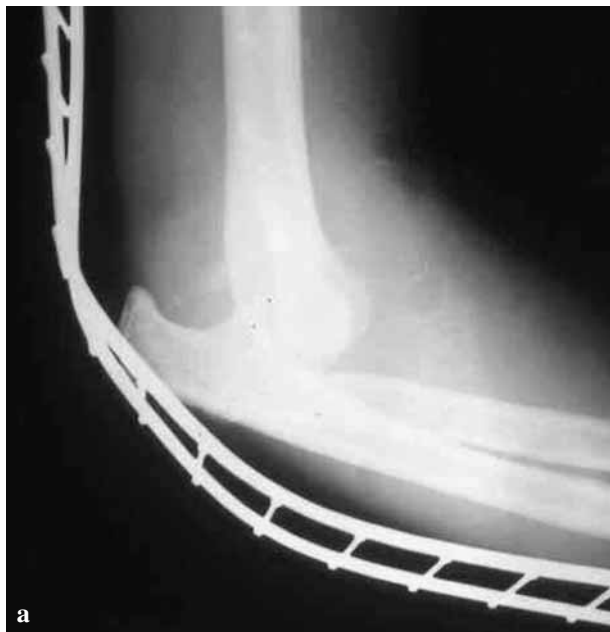Fig. 2. — a) Radiograph of a 34-year-old man with unstable elbow joint after posterolateral closed dislocation : Preoperative view ; b) The same patient with the fixation device on the 5th postoperative day : Active flexion position ; c) The same patient : Active extension position on the 5th postoperative day ; d) The same patient three years after the treatment - Active flexion position ; e) The same patient three years after the treatment - Active extension position.

contractures caused by posttraumatic ischaemia (6). Generally, the management of joint contractures presents a great challenge both for the orthopaedic and the plastic surgeons. Aggressive physiotherapy, manipulation, splinting and various surgical methods (including soft tissue, skin and tendon release and osteotomies) have been described for the treatment of joint contractures.

We have applied the Ilizarov method for the treatment of severe post-traumatic, post-burn, and post-ischaemia contractures of the elbow, knee and ankle joints. The correction of ankle deformities using the Ilizarov apparatus is principally based on the distraction histogenesis mechanism and has already been discussed by Ilizarov (9). A contracture can be characterized by a vector with direction, magnitude and location. Equinus correction is possible by differential lengthening with more distraction on the concave side. The placement of the hinges is very important and subluxation can be the consequence of an inappropriate fixation (6). During the correction process, progressive stretching of the extra-articular and intraarticular connective tissues allows correction of the deformity. Concomitantly, there is a progressive lengthening of all soft tissues including vessels and nerves. It should be remembered that in patients with only one supplying blood vessel, elongation might endanger the blood supply (4). When no osteotomies are performed, overcorrection is recommended to reduce the recurrence rate, as described by Grant *et al* (5).

The closed technique has been well described for the treatment of large joint deformities especially contractures (1, 2, 5). Roermund *et al* (12) successfully applied the Ilizarov apparatus to interphalangeal joint contracture, with good results maintained through 3 years of follow-up. Severe flexion deformity may need tenotomies in order to improve the result (3). We performed subcutaneous Achilles tenotomy for patients with ankle deformity. Huang (6) reported a high recurrence rate of contracture after using the Ilizarov method, but he had better results in patients with posttraumatic contractures.

Although Madhuri and Dhanraj (10) successfully improved the sequelae of a severe post burn defor-

mity of the wrist existing since 43 years, we preferred in all our cases to start correction of the deformity as early as possible. It is well known that a scar may take up to 2 years to mature and that the result is better the sooner the stretching begins (11). We had no relapses to pre-treatment condition in our patients after a mean follow-up of 42 months (range 30-84 months). In children the Ilizarov device may be considered as a salvage procedure due to their low compliance with physiotherapy. The advantage of using the Ilizarov technique for reduction of foot deformities is attributed to the possibility of three-dimensional correction, the possibility to stretch skin, soft tissues, bones and scars with a minimal additional trauma and the possibility of full weight bearing during the distraction procedure.

It is known that the ideal way to avoid joint stiffness or contracture is by using complementary treatments such as physiotherapy and splinting. External fixation frames with hinges were successfully applied by us in two patients for joint stabilization in severe joint instability caused by massive peri-articular soft tissue damage after dislocation.

In our present series of eight patients, we have successfully used the Ilizarov method for treating joint contractures and instability and we think that it should be added to the armamentarium of surgeons dealing with joints and soft tissue problems, and should not be reserved for bony problems only.

REFERENCES

1. Calhoun JH, Evans EB, Herndon DN. Techniques for the management of burn contractures with the Ilizarov fixator. *Clin Orthop* 1992 ; 280 : 117-123.
2. Choi IH, Kim JI, Yoo WJ *et al*. Ilizarov treatment for equinoplanovalgus foot deformity caused by melorheostosis. *Clin Orthop* 2003 ; 414 : 238-241.
3. Damsin JP, Ghanem I. Treatment of severe flexion deformity of the knee in children and adolescents using the Ilizarov technique. *J Bone Joint Surg* 1996 ; 78-B : 140-144.
4. Edelson JG, Hussein N. The pulseless club-foot. *J Bone Joint Surg* 1984 ; 66-B : 700-702.
5. Grant A, Atar D, Lehman WB. The Ilizarov technique in correction of complex foot deformities. *Clin Orthop* 1992 ; 280 : 94-103.

6. **Huang SC.** Soft tissue contractures of the knee or ankle treated by the Ilizarov technique. High recurrence rate in 26 patients followed for 3-6 years. *Acta Orthop Scand* 1996 ; 67 : 443-449.
7. **Ilizarov GA, Deviatov AA.** Surgical elongation of the leg. *Ortop Traumatol Protez* 1971 ; 32 : 20-25.
8. **Ilizarov GA.** Clinical application of tension-stress effect for limb lengthening. *Clin Orthop* 1990 ; 250 : 8-26.
9. **Ilizarov GA.** The tension-stress effect on the genesis and growth of tissues. Part I. The influence of stability of fixation and soft tissue preservation. *Clin Orthop* 1989 ; 238 : 249-281.
10. **Madhuri V, Dhanraj P.** Correction of post burns contracture of wrist with Ilizarov method. *Burns* 1998 ; 24 : 576-578.
11. **Mustoe TA, Cooter RD, Gold MH et al.** International clinical recommendations on scar management. *Plast Reconstr Surg* 2002 ; 110 : 560-571.
12. **Roermund PMV, Valburg AAV, Duivemann E et al.** Function of stiff joints may be restored by Ilizarov joint distraction. *Clin Orthop* 1998 ; 348 : 220-227.