



Treatment of deep wound infections after spinal fusion with a vacuum-assisted device in patients with spinal cord injury

Carlos VICARIO, JESUS DE JUAN, Ana ESCLARIN, Monica ALCOBENDAS

*From the Hospital Nuestra Señora del Prado, Talavera de la Reina, Toledo, Spain
and the Hospital Nacional de Parapléjicos, Toledo, Spain*

Postoperative wound infection is a severe complication after spinal instrumentation, especially in a patient with spinal injury.

We used vacuum-assisted wound closure (VAC) in two patients with spinal cord injury, who presented deep wound infection after spinal instrumentation and were treated with an aggressive irrigation and debridement procedure.

Three and four weeks after VAC application, the hardware was completely covered by granulation tissue and a secondary closure was undertaken. No significant complications were observed. Six months after secondary closure, the wounds remained healed, no signs of instrumentation loosening, halving or lysis around the instrumentation were observed, and patients had completed their rehabilitation program and were discharged from hospital. Vacuum assisted wound closure appears as an excellent option in the treatment of deep wound infections after spinal instrumentation in patients with spinal cord injury.

Keywords : spinal instrumentation ; infection ; vacuum-assisted wound closure ; spinal cord injury.

INTRODUCTION

Postoperative wound infection is a severe complication after spinal instrumentation. Reported rates of deep wound infection after spine fusion range from 1.9% to 20% (10, 16). No specific data on deep infection following spine instrumentation

in patients with spinal cord injury are available. Treatment includes aggressive debridement and irrigation, primary or delayed closure, antibiotic therapy, and in some instances closure with myocutaneous or fasciocutaneous flaps or even removal of internal fixation (7, 10, 13, 14, 16, 17). These techniques allow eradication of infection with maintenance of the instrumentation in many instances. However, these aggressive surgical procedures go together with a high rate of morbidity for the patient and a significant delay in rehabilitation, which is very important in patients with spinal cord injury (15).

Good results have recently been reported in the management of postoperative spinal infections

■ Carlos Vicario, MD, PhD, Attending Surgeon.

Orthopaedic Surgery Department, Hospital Nuestra Señora del Prado, Talavera de la Reina, Toledo, Spain.

■ Jesus de Juan, MD, Attending Surgeon.

Orthopaedic Surgery Department, Hospital Nacional de Parapléjicos, Toledo, Spain.

■ Ana Esclarin, MD, Attending Physician.

Rehabilitation Department, Hospital Nacional de Parapléjicos, Toledo, Spain.

Correspondence : Carlos Vicario, Servicio de Traumatología y Cirugía Ortopédica, Hospital Nuestra Señora del Prado, Ctra Madrid 114, Talavera de la Reina, Toledo 45071, Spain.

E-mail : cvicario@iespana.es.

© 2007, Acta Orthopædica Belgica.

with negative pressure dressings (12, 18). Negative pressure dressings or VAC therapy are non-invasive systems that promote wound healing, as the negative pressure over the wound decreases the wound volume, removes oedema fluid, stimulates reparative granulation tissue and reduces bacterial colonisation (3, 9). These systems have been successfully employed in a variety of conditions such as open wounds in extremities (4), open sternal wounds (8), pressure sores (5), etc. As far as we know there have been no reports about their use in patients with spinal cord injury.

We report here our experience with VAC therapy in the management of postoperative spinal infection with exposure of hardware in two patients with spinal cord injury.

CASE REPORTS

Case 1

An 18-year-old male suffered a quad accident and was diagnosed with a fracture dislocation of T3/T4 and a burst fracture of T9. He had a level T4 A American Spinal Injury Association (ASIA) (1) spinal cord injury. He underwent a posterior fusion from T1 to L1 in his referring hospital (fig 1A) and was then transferred to our center, 3 weeks after surgery. Dehiscence and purulent drainage of the wound were found, with positive culture for *Staphylococcus aureus* and *Escherichia coli* (fig 1C). An aggressive irrigation and debridement was undertaken with wide exposure of the hardware (fig 1D) and a VAC device was applied, followed by intravenous antibiotic therapy. Disposable sponges were changed 3 times per week in the patient's room.

Case 2

A 24-year-old male incurred a motorcycle accident and was diagnosed with a level T10 ASIA A (1) spinal cord injury following a burst fracture of T11. He underwent a posterior fusion from T8 to L2 in his referring hospital (fig 2A). When he was admitted at our center, 5 weeks after surgery, he presented with wound dehiscence and purulent

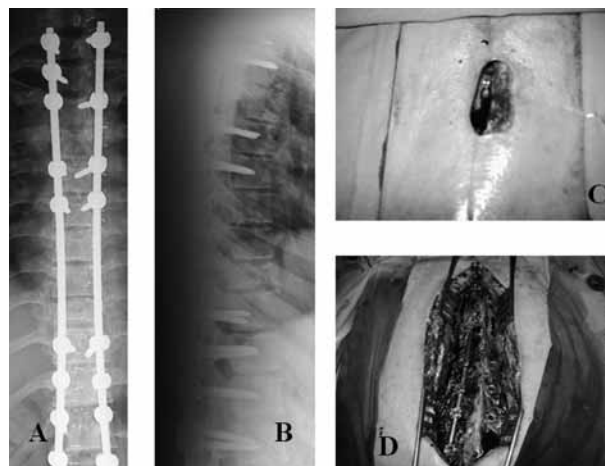


Fig. 1. — Case 1 : 1A and 1B : Posterior fusion from T1 to L1 ; 1C : Initial aspect of the infected wound ; 1D : Aspect of the wound after irrigation and debridement.

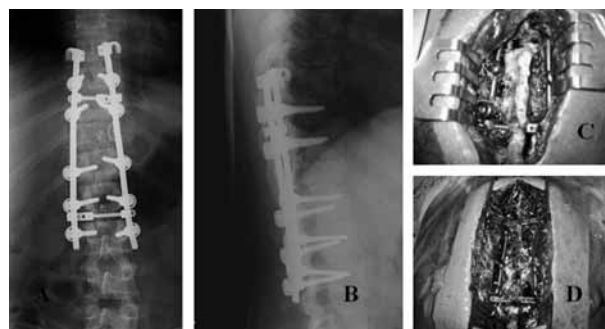


Fig. 2. — Case 2 : 2A and 2B : Fusion from T8 to L2 ; 2C : Aspect of the wound before irrigation and debridement ; 2D : Aspect of the wound after irrigation and debridement.

drainage, exposure of hardware and a positive culture for *S. aureus* (fig 2C). An aggressive irrigation and debridement was undertaken with wide exposition of hardware (fig 2D), a VAC device was applied, and intravenous antibiotic therapy was administered. Disposable sponges were changed 3 times per week in the patient's room.

In both cases proliferation of reparative granulation tissue was observed and complete coverage of the hardware was achieved in two and three weeks respectively. This made it possible to perform secondary closure in both cases, three and four weeks

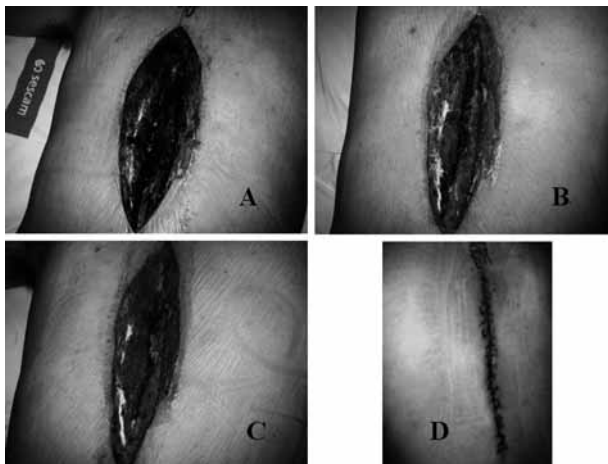


Fig. 3. — Case 1 : Clinical aspect of the wound after application of the VAC device. Note progressive wound closure (pictures were taken weekly 3A to 3C) until secondary closure was performed (3D).

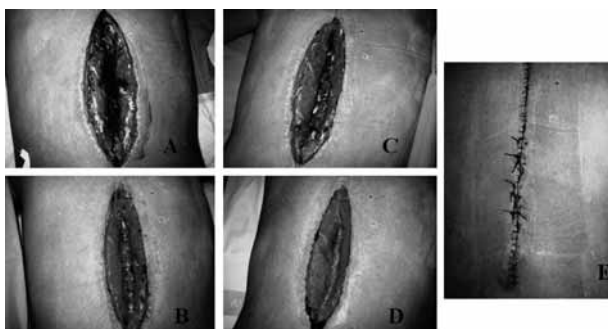


Fig. 4. — Case 2 : Clinical aspect of the wound after application of VAC device. Note progressive wound closure (pictures were taken weekly 4A to 4D) until secondary closure was performed (4E).

respectively after initial irrigation and debridement. The weekly evolution of both cases can be seen in figures 3 & 4.

Patients were confined to bed rest with postural changes to prevent pressure sores during VAC application. The only secondary effect was a sensation of tingling around the wound during treatment in both cases.

After secondary closure, the patients stayed in bed for another week, following which their rehabilitation program was initialised. Both wounds healed without problems and sutures were removed

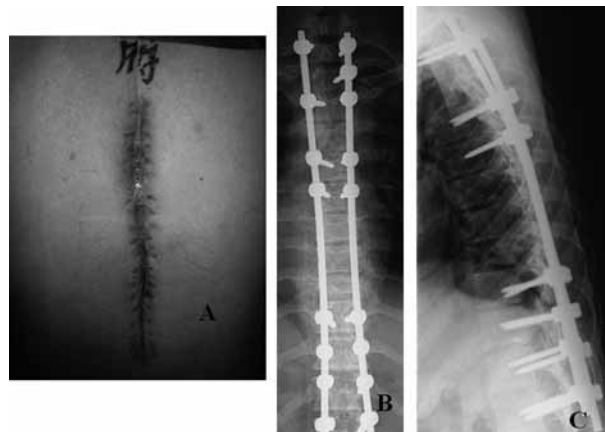

Fig. 5. — Case 1 : Clinical aspect and radiograph 6 months after application of VAC device.

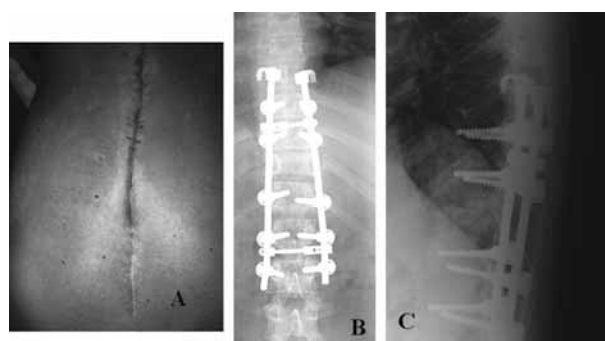


Fig. 6. — Case 2 : Clinical aspect and radiograph 6 months after application of VAC device.

12 and 14 days later. Intravenous antibiotics were maintained for two weeks after secondary closure.

Six months after secondary closure, patients had satisfactorily completed their rehabilitation program, including obtaining a driver's license, and were discharged from our center. Their wounds were completely healed and no secondary changes suggestive of late infection such as instrumentation loosening or lysis around the hardware could be observed (figs 5 & 6).

DISCUSSION

In patients with spinal cord injury, deep wound infections after spinal instrumentation are

especially severe, because of the need for an early rehabilitation (15) and the high incidence of complications that are associated with a delay in mobilisation (11).

Current treatment of deep spinal wound infections includes a protocol of aggressive irrigation and debridement, primary or secondary closure, and several coverage techniques like muscle, myocutaneous or fasciocutaneous flaps (7, 10, 13, 14, 16, 17). These techniques will allow eradication of infection with maintenance of the instrumentation in many instances. However these successful surgical procedures include a high rate of morbidity for the patient, multiple surgical sessions, and a significant delay in the beginning of physical therapy. The literature reports between 2.7 to 4.7 surgical sessions to achieve wound closure following deep wound spinal infections (7, 13).

The VAC device has been successfully employed in a variety of pathologies like open wounds in extremities (4), open sternal wounds (8), and pressure sores (5). One of the main advantages reported is a decrease in the number of surgical sessions (4-6, 8, 12). It is of importance in the spinal injured patient, because if treatment of the wound infection is very long, severe complications are likely to occur, such as pressure sores, pulmonary complications, and deep venous thrombosis (2, 11, 15). Recent reports have described successful results when treating spinal infections with the VAC device. Yuan-Innes *et al* (18) reported 2 cases in a 10-year-old and a 17-year-old patients with deep infection following spine instrumentation. Both healed successfully after 6 and 10 weeks of treatment with the VAC device (the first one was closed with a split thickness skin graft) and were stable 10 months after closure. Mehbod *et al* (12), reported 20 consecutive cases of deep wound infection after spinal fusion treated with VAC therapy : all patients achieved a clean closed wound without removal of instrumentation at a minimum follow-up of 6 months. They needed an average of 2.2 surgical procedures including secondary closure of the wound, which was closed on average 7 days after placement of the VAC device.

In our experience, VAC offers several advantages :

1. All cases of deep spinal wound infection treated with the VAC device have successfully healed without significant complications, and hardware has not been removed in any case.
2. Most of the time, only one initial adequate debridement suffices prior to the application of the VAC device, and secondary closure can be undertaken once coverage of the instrumentation with granulation tissue has been achieved.
3. The duration of application was highly variable in the literature. We have found that application during seven days as in the cases reported by Mehbod *et al* (12) may not be long enough for the reparative granulation tissue to cover the hardware and to proceed to a safe secondary closure.
4. Most authors have recommended removal of instrumentation six months following closure of the wound. We have not found this necessary in our patients since no late infection signs have been observed, and secondary hardware removal would interfere with the rehabilitation progress.

In conclusion, VAC therapy appears to us as an excellent option in treatment of deep wound infections after spinal instrumentation in spinal cord injured patients because an accurate wound closure without removal of instrumentation can be achieved in a short period of time without significant complications.

REFERENCES

1. **American Spinal Injury Association/IMSoP.** *International Standards for Neurologic and Functional Classification of Spinal Cord Injury.* Atlanta, American Spinal Injury Association. 1992.
2. **Aito S, Pieri A, D'Andrea M et al.** Primary prevention of deep venous thrombosis and pulmonary embolism in acute spinal cord injured patients. *Spinal Cord* 2002 ; 40 : 300-303.
3. **Argenta LC, Morykwas MJ.** A new method for wound control and treatment : Animal studies and basic foundation. *Ann Plast Surg* 1997 ; 38 : 563-576.
4. **DeFranzo AJ, Argenta LC, Marks MW et al.** The use of vacuum-assisted closure therapy for the treatment of lower-extremity wounds with exposed bone. *Plast Reconstr Surg* 2001 ; 108 : 1184-1191.

5. Deva AK, Siu C, Nettle WJ. Vacuum-assisted closure of a sacral pressure sore. *J Wound Care* 2001 ; 6 : 311-312.
6. Erdmann D, Drye C, Heller L *et al.* Abdominal wall defect and enterocutaneous fistula treatment with the Vacuum-Assisted Closure (V.A.C.) system. *Plast Reconstr Surg* 2001 ; 108 : 2066-2068.
7. Glassman SD, Dimar JR, Puno RM, Johnson JR. Salvage of instrumental lumbar fusions complicated by surgical wound infection. *Spine* 1996 ; 21 : 2163-2169.
8. Gustafsson R, Johnsson P, Algotsson L *et al.* Vacuum-assisted closure therapy guided by C-reactive protein level in patients with deep sternal wound infection. *J Thorac Cardiovasc Surg* 2002 ; 123 : 895-900.
9. Joseph E, Hamori CA, Bergman S *et al.* Prospective randomized trial of vacuum-assisted closure versus standard therapy of chronic non-healing wounds. *Wounds* 2000 ; 12 : 60-67.
10. Klink BK, Thurman RT, Wittpenn GP *et al.* Muscle flap closure for salvage of complex back wounds. *Spine* 1994 ; 19 : 1467-1470.
11. McKinley W, Meade MA, Kirshblum S, Barnard B. Outcomes of early surgical management versus late or no surgical intervention after acute spinal cord injury. *Arch Phys Med Rehabil* 2004 ; 85 : 1818-1825.
12. Mehbod AA, Ogilvie JW, Pinto MR *et al.* Postoperative wound infections in adults after spinal fusion. Management with Vacuum Assisted wound closure. *J Spinal Disord Tech* 2005 ; 18 : 14-17.
13. Picada R, Winter RB, Lonstein JE *et al.* Postoperative deep wound infection in adults after posterior lumbosacral spine fusion with instrumentation : incidence and management. *J Spinal Disord* 2000 ; 13 : 42-45.
14. Stambough JL, Beringer D. Postoperative wound infections complicating adult spine surgery. *J Spinal Disord* 1992 ; 5 : 277-285.
15. Sumida M, Fujimoto M, Tokuhiko A *et al.* Early rehabilitation effect for traumatic spinal cord injury. *Arch Phys Med Rehabil* 2001 ; 82 : 391-395.
16. Weinstein MA, McCabe JP, Cammisa FP Jr. Postoperative spinal wound infection : a review of 2,391 consecutive index procedures. *J Spinal Disord* 2000 ; 13 : 422-426.
17. Wimmer C, Gluch H. Management of postoperative wound infection in posterior spinal fusion with instrumentation. *J Spinal Disord* 1996 ; 9 : 505-508.
18. Yuan-Innes MJ, Temple CL, Lacey MS. Vacuum-Assisted wound closure : A new approach to spinal wounds with exposed hardware. *Spine* 2001 ; 26, E-30-E-33.