



## Interobserver reliability in evaluation of pedicle screw positions inserted with a modified technique

Ozguir OZER, Cagatay OZTURK, Burak AKESEN, Ufuk AYDINLI

*From the Department of Orthopaedic Surgery, Faculty of Medicine, University of Uludağ, Bursa, Turkey  
and the Florence Nightingale Hospital, Istanbul, Turkey*

The aim of this study was to evaluate a new technique for insertion of pedicle screws. The position of the screws was assessed on postoperative plain radiographs and computed tomography (CT) scans, and the interobserver reliability in evaluation of the pedicle screw positions was studied.

The technique was applied to insert 201 pedicle screws in 27 patients with various spine conditions. The positions of the screws were evaluated blindly by two independent orthopaedic surgeons and two independent radiologists. Interobserver reliability was evaluated separately for analysis of plain radiographs and CT scans, as well as for the different spinal segments and for the different spine conditions treated. The rate of malpositioned screws was between 6.5% and 32.8% in plain radiographs and between 3.5% and 6.5% in CT scans according to the different observers. In plain radiographs, the rates of malpositioned screws in the upper thoracic, lower thoracic and lumbosacral spine segments were between 3.8%-39.6%, 10.0%-36.3%, 4.4%-23.5%, respectively. In CT scans, the rates of malpositioned screws in the upper thoracic, lower thoracic and lumbosacral spine segments were between 3.8%-13.2%, 2.5%-8.8%, and 0%, respectively. Interobserver reliability was found to be poor in radiographs and fair in CT scans. The technique used for insertion of pedicle screws was found to be simple and reproducible. Assessment of the screw positions with only plain radiographs was not found reliable. A detailed and standard classification system should be developed in order to improve interobserver reliability in assessing the positions of the screws.

**Keywords :** pedicle screw ; insertion technique ; interobserver reliability.

### INTRODUCTION

Pedicle screws represent a unique part of spinal instrumentation (3). They provide stable immediate fixation, together with the possibility to achieve improved reduction in comparison with hooks. Pedicle screws are inherently stable and resist loads in all planes, thus offering a potential advantage in comparison with hooks (2, 14, 35).

Pedicle screws are being used in a variety of pathological conditions of the spine including

- Ozgur Ozer, MD, Registrar.
- Burak Akesen, MD, Registrar.
- Ufuk Aydinli, MD, Professor.

*University of Uludağ, Faculty of Medicine, Department of Orthopaedic Surgery, Bursa, Turkey.*

■ Cagatay Ozturk, MD, Consultant.  
*Department of Orthopedic Surgery, Florence Nightingale Hospital, Istanbul, Turkey.*

Correspondence : Cagatay Ozturk, MD, Florence Nighingale Hospital, Department of Orthopaedic Surgery, Istanbul, Turkey. E-mail : rezocagatay@hotmail.com.

© 2007, Acta Orthopædica Belgica.

trauma, degenerative disease, tumours, and deformity (11, 12, 21, 23, 26, 35). Accurate pedicle screw insertion may present problems. Spinal surgeons are well aware of the complications associated with malposition of the screws, such as loss of fixation, neurological injury, and vascular injury (10, 32, 34, 35). It is therefore of paramount importance to use the appropriate technique in placing the screws, and to verify their position in the pedicles.

Pedicle screws are inserted in a partially blind manner using well-defined anatomic landmarks, the surgeon's three-dimensional mental image of the spine, and his or her tactile sense. Screw position is then confirmed with intra-operative posterior-anterior (PA) and lateral roentgenograms.

In order to gain better knowledge of the spinal pedicle anatomy and to develop safe techniques to insert pedicle screws, numerous cadaveric and radiological studies have been made (19, 21, 22, 25, 28).

Plain radiographs (XR), fluoroscopy and computer-assisted systems (CT) are the most popular equipments used to find a safe way for pedicle screw insertion and to evaluate the screw positions (1, 4, 6, 9, 13, 15, 17, 19-21). In most cases however, the position of the pedicle screws has been assessed only with plain radiographs and by the surgeon himself.

The purpose of this study was to present a modified technique for pedicle screw insertion with minimal need for adjunct methods, and to assess the inter-observer reliability in determining the pedicle screw position with either plain radiographs or CT scans.

## MATERIALS AND METHOD

In this study, a modified technique described below was used in 27 patients with various pathologies. Mean age of the patients was 33 years (range : 3 to 63 ; mean  $\pm$  SD, 32.9  $\pm$  19.5 years). The male to female ratio was 10 to 17. The preoperative diagnosis was degenerative spine disease in 7 (26%) patients, fracture in 3 (11%), Scheurmann's disease in 5 (18.5%), metastatic spine tumours in 4 (15%), adolescent idiopathic scoliosis in 3 (11%), congenital scoliosis in 2 (7.5%), posttraumatic kyphosis in 2 (7.5%) and spondylolisthesis in one (3.5%) patient. A spinal deformity was present in 12

(44.5%) patients : coronal plane deformity in 5 and sagittal plane deformity in 7 patients.

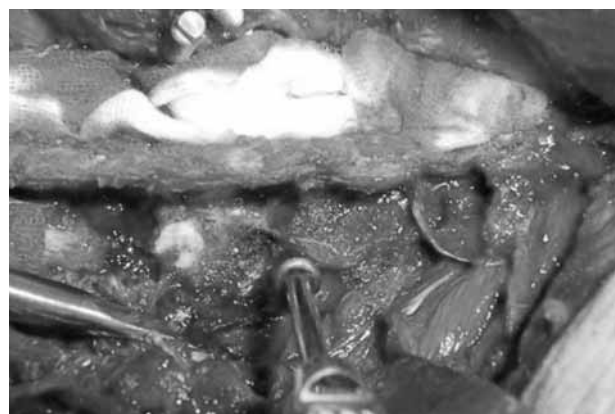
A total of 201 pedicle screws were inserted. One hundred and ten screws (54.7%) were used in patients with deformity. Fifty-three (26.4%) of the pedicle screws were inserted between T1-T6, 68 (33.8%) between T7-T12 and 80 (39.8%) between L1-S1. Patients' demographic characteristics and number of screws used are summarised in table I. Preoperative computed tomography (CT) was not used routinely.

## Surgical technique

A posterior approach was used in all cases, with the patient lying prone under general anaesthesia. After mid-line incision, the soft tissues over the posterior surface of the pedicles that were determined to be implanted in preoperative plans were dissected and retracted laterally.

An entry point 0.5 cm in diameter was made with an awl by violating only the posterior pedicle cortex after determining the vertebra in which pedicle screws will be inserted (fig 1). After preparation of the entry holes, drawing pins with 6 mm spike and head with 5 mm radius were inserted into the entry holes (fig 2). Drawing pins were controlled with anterior - posterior (AP) fluoroscopy views (fig 3). Entry holes were changed if the heads of the drawing pins did not fit in the body of the pedicles in AP views.

A 1.2 mm semi-flexible K-wire with 1.6 mm ball at the end (fig 4a, b) was tapped into the trabecular bone of the pedicle in order to find the pedicle channel and when the correct angle was reached, the K-wire was easily



**Fig. 1.** — An entry point 0.5 cm in diameter is made with an awl by violating only the posterior pedicle cortex, after determining the vertebra into which the pedicle screw will be inserted.

Table I. — Demographic data of the patients and number of screws for each patient

n	GENDER	AGE	DIAGNOSIS	NUMBER of SCREWS
1	Female	55	Degenerative spine	10
2	Female	19	Fracture	8
3	Male	17	Scheuermann kyphosis	7
4	Female	52	Degenerative spine	4
5	Female	36	Fracture	8
6	Male	28	Fracture	6
7	Male	63	Metastatic disease	4
8	Female	37	Metastatic disease	4
9	Female	16	Scoliosis	11
10	Female	52	Degenerative spine	6
11	Female	29	Posttraumatic kyphosis	6
12	Female	4	Congenital scoliosis	3
13	Male	9	Scoliosis	8
14	Female	55	Metastatic disease	8
15	Female	15	Scheuermann kyphosis	11
16	Female	22	Scoliosis	13
17	Male	16	Scheuermann disease	13
18	Male	15	Scheuermann disease	10
19	Male	42	Posttraumatic kyphosis	8
20	Female	59	Degenerative spine	6
21	Male	15	Scheuermann kyphosis	16
22	Male	42	Degenerative spine	4
23	Female	59	Metastatic disease	8
24	Female	3	Congenital scoliosis	4
25	Male	17	Spondylolisthesis	2
26	Female	57	Degenerative spine	7
27	Female	55	Degenerative spine	6

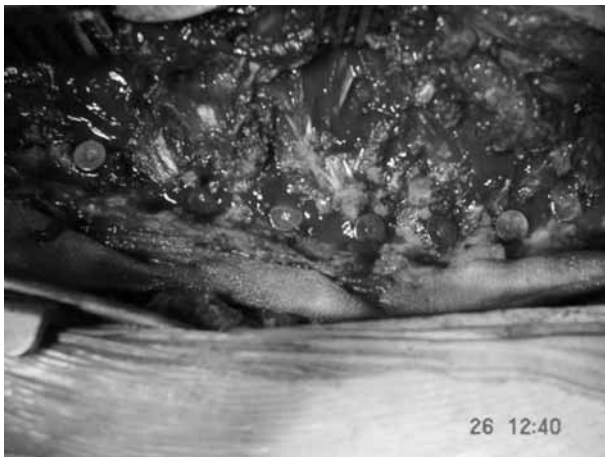


Fig. 2. — Drawing pins inserted.

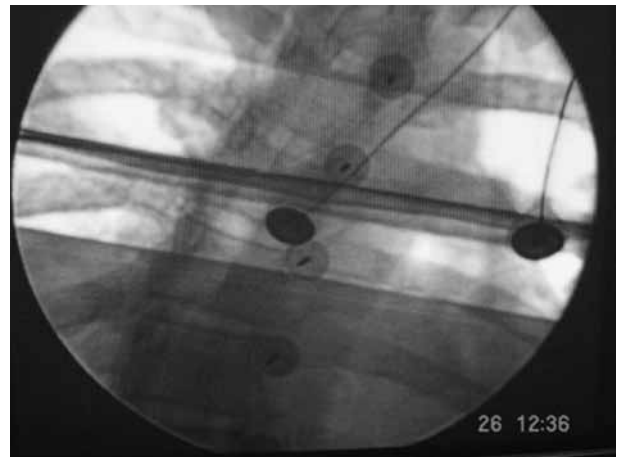
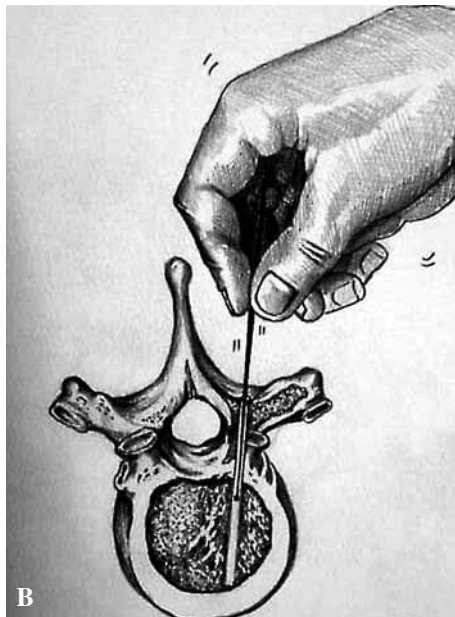



Fig. 3. — Drawing pins controlled with AP fluoroscopy. The heads of the pins fit with the borders of the pedicles.



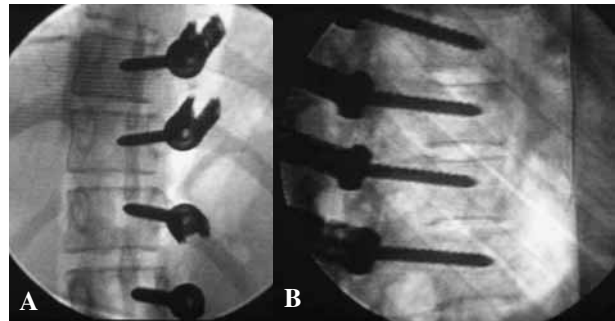
**Fig. 4A, B.** — A 1.2 mm semi-flexible K-wire with a 1.6 mm ball at the end is tapped into the trabecular bone of the pedicle. If the correct angle of the pedicle was reached the surgeon can feel the anterior cortex of the vertebra.

passed through the pedicle channel and the surgeon made sure he felt the anterior inner cortex of the vertebral body. Leaving the K-wire in place, a canulated taper was used to prepare the pedicle screw pathway (fig 5). Care was taken to make sure that the medial, lateral, anterior and posterior walls of the pedicle channel as well as the anterior cortex of the vertebral body had not been penetrated by the K-wire.

The length of the pedicle screw was measured with a depth gauge and the width was determined according to the spine level (thoracic, lumbar, sacral). Keeping in mind the angle of the K-wire, the pedicle screw was inserted gently. The surgeon will feel that the screw passes through the pedicle channel easily if it is inserted



**Fig. 5.** — A canulated taper is used to prepare the pedicle screw pathway with the K-wire left in its place.



**Fig. 6.** — Screw positions are controlled with AP (A) and lateral fluoroscopy (B).

in the direction of the K-wire, which is tapped into the trabecular bone previously. After insertion of all screws, anterior and posterior fluoroscopy control was used to assess the screw positions by the senior surgeon (fig 6a, b).

Post-operatively, radiographs and CT scans were used to assess the positions of all screws. 3-D CT models were reconstructed from axial scans and an extended CT scale (40,000 Hounsfield units) was used in order to assess the screw positions and reduce metal artefacts.

All radiographs and CT scans were reviewed by two independent radiologists and by two independent orthopaedic surgeons blinded to the patient's history. Screws that were considered, by at least two observers according to CT scans, to penetrate the pedicle wall more than 2 mm in any direction were accepted as malpositioned. Aetiological factors were divided into two groups; deformity and non-deformity and the ratio of malpositioned screws were determined for each group with both radiographs and CT. Screws were also assessed according to upper thoracic (T1-T6), lower

thoracic (T7-T12) and lumbosacral (L1-S1) segments of spine. Inter-observer agreement was evaluated using kappa statistics on plain radiographs and CT scans separately.

**Statistical analysis**

In the statistical analysis, kappa statistics was used. The maximum value of kappa is 1, which represents perfect agreement, and value of kappa zero is for agreement of chance. SPSS for Windows version 10.0 was used to make statistical analysis and the p-value of 0.05 was accepted as statistical significance in two-tailed limits.

**RESULTS**

The proportion of malpositioned screws was rated between 6.5% and 32.8% (mean : 18.9%) in plain radiographs and between 3.5% and 6.5% (mean : 5.1%) in CT scans (table II) by the individual observers. In plain radiographs, the proportions of malpositioned screws in the upper thoracic, thoracic and lumbosacral spine segments were between 3.8%-39.6% (mean : 24%), 10.0%-36.3% (22.5%) and 4.4%-23.5% (mean : 10.6%) respectively (table III). In CT scans, the proportions of malpositioned screws in the upper thoracic, thoracic and lumbosacral spine segments were

between 3.8%-13.2% (mean : 10.3), 2.5%-8.8% (mean : 5.9%) and 0% respectively (table IV).

Analysis related with the various spine conditions treated showed that the proportion of malpositioned screws of patients without any spine deformity was on average 13.2% (range : 4.4% to 28.5%) in plain radiographs and 3% (range : 2.2% to 5.5%) in CT scans. The proportion of malpositioned screws in cases with coronal plane deformities averaged 23.6% (range : 7.9% to 36.8%) in plain radiographs and 7.8% (range : 2.6% to 13.1%) in CT scans. The corresponding proportion in cases with sagittal plane deformities was 23.5% (range : 8.3% to 36.1%) for plain radiographs and 6.2% (range : 2.7% to 8.3%) for CT scans (tables V, VI).

The overall penetration rate of the pedicle screws was 4.5% (9 screws). There were medial wall violations with 3 (1.5%) screws, of the lateral wall with 5 (2.5%) and of the anterior cortex with one screw (0.5%). There were 7 screws penetrating the pedicle wall between T1 and T6, 2 screws penetrating the pedicle wall between T7 and T12 and no pedicle wall penetration was detected at the L1 and S1 levels. There were no neurological or vascular complications due to screw malposition.

Interobserver reliability was poor in radiographs and was just fair in CT scans (table VII, VIII).

Table II. — Rates of malpositioned screws in plain radiographs (XR) and CT scans (CT) according to each observer

	1. ORTHOPAEDIST	2. ORTHOPAEDIST	1. RADIOLOGIST	2. RADIOLOGIST
XR	15.4% (31)	32.8% (66)	6.5% (13)	20.9% (42)
CT	3.5% (7)	6% (12)	6.5% (13)	4.5% (9)

Table III. — Distribution of malpositioned screws according to each independent observer in analysis of plain radiographs

LEVELS	1. ORTHOPAEDIST	2. ORTHOPAEDIST	1. RADIOLOGIST	2. RADIOLOGIST
T <sub>1</sub> -T <sub>6</sub>	26.3% (14)	39.6% (21)	3.8% (2)	26.4% (14)
T <sub>7</sub> -T <sub>12</sub>	17.5% (14)	36.3% (29)	10.0% (8)	26.3% (21)
L <sub>1</sub> -S <sub>1</sub>	4.4% (3)	23.5% (16)	4.4% (3)	10.3% (7)

Table IV. — Distribution of malpositioned screws according to each independent observer in analysis of CT scans

LEVELS	1. ORTHOPAEDIST	2. ORTHOPAEDIST	1. RADIOLOGIST	2. RADIOLOGIST
T <sub>1</sub> -T <sub>6</sub>	3.8% (2)	13.2% (7)	11.3% (6)	13.2% (7)
T <sub>7</sub> -T <sub>12</sub>	6.3% (5)	6.3% (5)	8.8% (7)	2.5% (2)
L <sub>1</sub> -S <sub>1</sub>	0% (0)	0% (0)	0% (0)	0% (0)

Table V. — Distribution of malpositioned screws according to presence or absence of spinal deformity, for each independent observer in plain radiographs

ETIOLOGY	1. ORTHOPAEDIST	2. ORTHOPAEDIST	1. RADIOLOGIST	2. RADIOLOGIST
Coronal plane deformity	21.0% (8)	36.8% (14)	7.9% (3)	28.9% (11)
Sagittal plane deformity	22.2% (16)	36.1% (26)	8.3% (6)	27.7% (20)
Without any deformity	7.7% (7)	28.5% (26)	4.4% (4)	12.1% (11)

Table VI. — Distribution of malpositioned screws according to presence of deformity by each independent observer in plain radiographs

DEFORMITY	1. ORTHOPAEDIST	2. ORTHOPAEDIST	1. RADIOLOGIST	2. RADIOLOGIST
Coronal plane deformity	7.9% (3)	7.9% (3)	13.1% (5)	2.6% (1)
Sagittal plane deformity	2.7% (2)	5.5% (4)	8.3% (6)	8.3% (6)
Without any deformity	2.2% (2)	5.5% (5)	2.2% (2)	2.2% (2)

Table VII. — Inter-observer reliability between each observer at T<sub>1</sub>-S<sub>1</sub> levels according to plain radiographs

Observers	Kappa	p
1.ort-2.ort	0.201	0.001
1.ort-1.rad	0.267	0.000
1.ort-2.rad	0.242	0.000
2.ort-1.rad	-0.007	0.870
2.ort-2.rad	0.293	0.000
1.rad-2.rad	0.095	0.107

Table VIII. — Inter-observer reliability between each observer at T<sub>1</sub>-S<sub>1</sub> levels according to CT scans

Observers	Kappa	p
1.ort-2.ort	0.370	0.000
1.ort-1.rad	0.349	0.002
1.ort-2.rad	0.447	0.000
2.ort-1.rad	0.445	0.000
2.ort-2.rad	0.448	0.000
1.rad-2.rad	0.328	0.000

Table IX. — Inter-observer reliability between each observer at T<sub>1</sub>-S<sub>1</sub> levels according to plain radiographs and CT scans of patients without any deformity

Observers	X-rays		CT	
	KAPPA	p	KAPPA	p
1. ort – 2. ort	0.207	0.009	0.263	0.005
1. ort – 1. rad	0.326	0.001	0.489	0.000
1. ort – 2. rad	0.019	0.853	0.489	0.000
2. ort – 1. rad	-0.010	0.872	0.558	0.000
2. ort – 2. rad	0.121	0.186	0.558	0.000
1. rad – 2. rad	-0.069	0.448	0.489	0.000

Kappa scores ranged from -0.069 to 0.326 for plain radiographs and from 0.263 to 0.558 for CT scans of patient without deformity (table IX). The kappa scores for coronal plane deformities were between -0.014 and 0.467 in radiographs and between 0.109 and 0.479 in CT scans (table X). For sagittal plane deformities, they were between 0.006 and 0.325 in

plain radiographs and between 0.217 and 0.786 in CT scans (table XI).

## DISCUSSION

The main concern about pedicle screw placement in spinal surgery is misplacement. Various

Table X. — Inter-observer reliability between each observer at T<sub>1</sub>-S<sub>1</sub> levels according to plain radiographs and CT scans of patients with coronal plane deformities

Observers	X-rays		CT	
	KAPPA	p	KAPPA	p
1. ort – 2. ort	0.131	0.385	-0.086	0.597
1. ort – 1. rad	0.281	0.043	-0.109	0.482
1. ort – 2. rad	0.374	0.019	-0.041	0.767
2. ort – 1. rad	-0.014	0.896	-0.109	0.482
2. ort – 2. rad	0.467	0.003	0.479	0.001
1. rad – 2. rad	0.021	0.861	-0.046	0.693

Table XI. — Inter-observer reliability between each observer at T<sub>1</sub>-S<sub>1</sub> levels according to plain radiographs and CT scans of patients with sagittal plane deformities

Observers	X-rays		CT	
	KAPPA	p	KAPPA	p
1. ort – 2. ort	0.230	0.040	0.308	0.005
1. ort – 1. rad	0.172	0.087	0.478	0.000
1. ort – 2. rad	0.262	0.024	0.217	0.031
2. ort – 1. rad	0.006	0.941	0.786	0.000
2. ort – 2. rad	0.325	0.005	0.357	0.002
1. rad – 2. rad	0.206	0.026	0.455	0.000

methods and instruments are being used to find the pedicle pathway include pedicle finder (27), awl (5, 18), curettes, K-wire insertion with hammer or drilling (30, 31). These methods have a definite potential for violation of the pedicle wall.

In this study, an awl was used just to open the posterior cortex of the pedicle. A 1.2 mm semi-flexible K-wire with a 1.6 mm ball at its end was advanced manually through the pedicle channel while feeling the penetration into the trabecular bone. If the ball contacted cortical bone in the pedicle channel, it would not damage the pedicle wall.

Liljenquist *et al* (17) treated 32 idiopathic scoliosis cases with pedicle screws, 120 of which were inserted in the thoracic spine. In their study, they used the method of Suk *et al* (29) to determine the entrance point in the thoracic spine and the method of Weinstein *et al* (33) in the lumbar spine. They reported pedicle wall penetration in 25% of cases after all screws had been reviewed by three observers.

Complications due to pedicle screw misplacement forced some authors to develop techniques to assist and assess correct placement of pedicle screws (1, 8, 19, 21, 22, 25, 28). Verification of the pedicle screw positions by radiographs (anterior-posterior and lateral), fluoroscopy and CT is popular and is used in numerous studies (1, 19, 21, 22, 25). Weinstein *et al* (33) claimed that posterioranterior and lateral radiographs are not reliable to assess screw location. In contrast, Myles *et al* (21) stated in their study, in which beaded Kirshner wires were used, that radiographic verification of pedicle screw holes can be used safely. Acikbas and Tuncer (1) described a method which relies on plain intra-operative radiographs to determine correct screw position and found a percentage of 24% screw misplacement. In this study, the mean rate of malpositioned screws in plain radiographs is 18.9% (between 6.5% and 32.8%). The mean proportion of malpositioned screws in CT scans was 5.1% (range, 3.5% to 6.5%). On the other hand, when the screws

that were found, by at least two observers in CT scans, to penetrate the pedicle wall more than 2 mm in any direction are considered as malpositioned, the rate of malpositioning was 4.5%. Some of the malpositioned screws, in our study had a larger diameter than the pedicle diameter. Also, if the safe zone for medial and lateral wall penetration are accepted as 4 mm and 6 mm respectively (7, 17), the overall penetration rate would be 2%.

Although fluoroscopically assisted pedicle screw insertion is now commonly used, the reported rate of screw misplacement ranges from 28 to 40% in the studies using fluoroscopy for assessment of screws (16, 24, 28, 31). In a recent study of Carbone *et al* (5) 41 patients (252 screws) with cervico-thoracic, thoracic, thoraco-lumbar burst fractures and fracture-dislocations treated with pedicle screw via multiplanar fluoroscopy and after two independent investigators have reviewed the postoperative CT scans of 126 screws, they reported a rate of 12.7% malposition. In our study, fluoroscopy was used to determine whether the drawing pins were fit with the pedicle eyes in posteroanterior views and to assess the pedicle screw positions after insertion in lateral views.

CT scans and CT guided systems are also used intra-operatively and postoperatively to find out the accuracy of pedicle screw placement (1, 19, 21, 25). Leine *et al* (16) reported a misplacement rate of 4.3% in their study in which a CT-guided system was used to perform correct screw insertion. Merloz *et al* (20), in their study, stated that computer-guided screw insertion is more reliable and they reported a malposition rate of 8%. However, CT scans which were used preoperatively and intraoperatively have the disadvantage of radiation exposure. Also these systems require costly equipments that cannot be available in every center.

Sapkas *et al* (27) compared the reliability of both plain radiographs and CT scans and evaluated 220 pedicle screws by three independent investigators. They reported no statistically significant difference between plain radiographs and CT scans in order to evaluate the position of pedicle screws. However, they did not classify the screws according to the spinal segments. In this study, fifty-three (26.4%) of the pedicle screws were inserted

between T1-T6, 68 (33.8%) of the screws were inserted between T7-T12 and 80 (39.8%) of the screws were used between L1-S1 and after reviewing the screws with plain radiographs and CT scans, it can be seen that screw malposition is higher in the thoracic spine than the lumbar spine. Although CT scans show pedicle screw malposition more accurately than radiographs, the screw malposition rate according to CT scans decreased in the present study, after four observers reviewed them.

Suk *et al* (30), in their study in which 1.5% screw malposition was reported, used only postoperative plain radiographs to assess screw positions and further checked with CT scans in the case of any suspicious screw position. In the current study, all the screws were reviewed blindly by four independent investigators. Inter-observer reliability in X-ray reviews is poor (table VII) and is relatively more acceptable in CT scan reviews (table VIII).

We believe that the modified technique used for insertion of pedicle screws in this study is simple and suitable for the spine surgeons. This study shows that assessing the pedicle screws only with plain radiographs is not reliable and even through the CT scans show the pedicle screw position more accurately, it is difficult to estimate the correct position of pedicle screws. As in this study, inter-observer agreement is just fair in CT scans, screw positions must be evaluated via a universally accepted and detailed classifying system to assess pedicle screw position more accurately. We believe that this technique is simple and reliable, but also that evaluating the screw positions only with plain radiographs is not reliable. In order to improve interobserver reliability in evaluation of the positions of the screws, a detailed and standard classification system has to be developed.

## REFERENCES

1. Açıkbaz SC, Tuncer MR. New method for intraoperative determination of proper screw insertion or screw malposition. *J Neurosurg* 2000 ; 93 (Suppl 1) : 40-44.
2. Barr SJ, Schuette AM, Emans JB. Lumbar pedicle screws versus hooks. Results in double major curves in adolescent idiopathic scoliosis. *Spine* 1997 ; 22 : 1369-1379.
3. Boos N, Webb JK. Pedicle screw fixation in spinal disorders : a European view. *Eur Spine J* 1997 ; 6 : 12-18.



4. **Calancie B, Madsen P, Lebwohl N.** Stimulus-evoked EMG monitoring during transpedicular lumbosacral spine instrumentation : Initial clinical results. *Spine* 1994 ; 19 : 2780-2786.
5. **Carbone JJ, Tortolani JP, Quartararo GL.** Fluoroscopically assisted pedicle screw fixation for thoracic and thoracolumbar injuries : Technique and short-term complication. *Spine* 2003 ; 28 : 91-97.
6. **Carl AL, Khanuja H, Sachs B.** In vitro simulation : Early results of stereotaxy for pedicle screw placement. *Spine* 1997 ; 22 : 1160-1164.
7. **Castro WH, Halm H, Jerosch J.** Accuracy of pedicle screw placement in lumbar vertebrae. *Spine* 1996 ; 21 : 1320-1324.
8. **Cinotti G, Gumina S, Ripani M.** Pedicle instrumentation in the thoracic spine. *Spine* 1999 ; 24 : 114-119.
9. **Clements DH, Morledge DE, Martin WH.** Evoked and spontaneous electromyography to evaluate lumbosacral pedicle screw placement. *Spine* 1996 ; 21 : 600-604.
10. **Ebraheim N, Jabaly G, Xu R.** Anatomic relations of the thoracic pedicle to the adjacent neural structure. *Spine* 1997 ; 22 : 2338-2341.
11. **Ferrick MR, Kowalski JM, Simmons ED.** Reliability of roentgenograms in the evaluation of pedicle screw position. *Spine* 1997 ; 22 : 1249-1252.
12. **Gaines RW.** The use of pedicle screw internal fixation for the operative treatment of spinal disorders. *J Bone Joint Surg* 2000 ; 82-A : 1458-1475.
13. **Glassman SD, Dimar JR, Puno RM.** A prospective analysis of intraoperative electromyographic monitoring of pedicle screw placement with computed tomographic information. *Spine* 1995 ; 20 : 1375-1379.
14. **Hamill CL, Lenke LG, Bridwell KH.** The use of pedicle screw fixation to improve correction in the lumbar spine of patients with idiopathic scoliosis. Is it warranted? *Spine* 1996 ; 21 : 1241-1249.
15. **Kothe R, Panjabi MM, Liu W.** Multidirectional instability of the thoracic spine due to iatrogenic pedicle injuries during pedicle screw insertion. *Spine* 1997 ; 22 : 1836-1842.
16. **Leine T, Schlenzka D, Makitalo K.** Improved accuracy of pedicle screw insertion with computer-assisted surgery : A prospective clinical trial of 30 patients. *Spine* 1997 ; 22 : 1254-1258.
17. **Liljenqvist RF, Halm HFH, Link MT.** Pedicle screw instrumentation of the thoracic spine in idiopathic scoliosis. *Spine* 1997 ; 22 : 2239-2245.
18. **Liljenqvist RF, Link MT, Halm HFH.** Morphometric analysis of thoracic and lumbar vertebrae in idiopathic scoliosis. *Spine* 2000 ; 25 : 1247-1253.
19. **Maguire J, Wallace S, Madiga R.** Evaluation of intrapedicular screw position using intraoperative evoked electromyography. *Spine* 1995 ; 20 : 1068-1074.
20. **Merloz P, Tonetti J, Eid A.** Computer assisted spine surgery. *Clin Orthop* 1997 ; 337 : 86-96.
21. **Myles RT, Fong B, Esses SI.** Radiographic verification of pedicle screw pilot hole placement using Kirshner wires versus beaded wires. *Spine* 1999 ; 24 : 476-480.
22. **Ohlin A, Karlsson M, D ppe H.** Complications after transpedicular stabilization of the spine. A survivorship analysis 163 cases. *Spine* 1994 ; 19 : 2774-2779.
23. **Olsewski JM, Simmons EH, Kallen FC.** Morphometry of the lumbar spine : Anatomical perspectives related to transpedicular fixation. *J Bone Joint Surg* 1990 ; 72-A : 541-548.
24. **Rao G, Brodke SD, Rondina M.** Comparison of computerized tomography and direct visualization in thoracic pedicle screw placement. *J Neurosurg* 2002 ; 97 (Suppl 2) : 223-226.
25. **Robertson AP, Stewart RN.** The radiological anatomy of the lumbar and thoracic pedicles. *Spine* 2000 ; 25 : 709-715.
26. **Roy-Camille R, Saillant G, Mazel C.** Internal fixation of the lumbar spine with pedicle screw plating. *Clin Orthop* 1986 ; 203 : 7-17.
27. **Sapkas GS, Papadakis SA, Stathakoupolos DA.** Evaluation of pedicle screw position in thoracic and lumbar spine fixation using plain radiographs and computed tomography. A prospective study of 35 patients. *Spine* 1999 ; 24 : 1266-1269.
28. **Sjostrom L, Jacobsson O, Karlstrom G.** CT analysis of pedicle and screw tracts after implant removal in thoracolumbar fractures. *J Spinal Disord* 1993 ; 6 : 225-231.
29. **Suk SI, Lee CK, Min HJ.** Comparison of Cotrel-Dubousset pedicle screws and hooks in the treatment of idiopathic scoliosis. *Int Orthop* 1994 ; 18 : 341-346.
30. **Suk SI, Kim WJ, Lee SM.** Thoracic pedicle screw fixation in spinal deformities. Are they really safe? *Spine* 2001 ; 26 : 2049-2057.
31. **Talu U, Tifkaya K, G g s A.** A new, simple, safe and reliable method of thoracic pedicle screw insertion : Cannulated drill over K-wire. 8<sup>th</sup> International Meeting on Advanced Spine Techniques July 12-14, 2001, Bahamas ; paper abstract #21, 2001.
32. **Vaccaro AR, Rizzolo SJ, Balderston RA.** Placement of pedicle screws in the thoracic spine. Part II : An anatomical and radiographic assessment. *J Bone Joint Surg* 1995 ; 77-A : 1200-1206.
33. **Weinstein JN, Spratt KF, Splenger D.** Spinal pedicle fixation : reliability and validity of roentgenogram-based assessment and surgical factors on successful screw placement. *Spine* 1988 ; 13 : 1012-1018.
34. **Weinstein JN, Rydevik BL, Rausching W.** Anatomic and technical consideration of pedicle screw fixation. *Clin Orthop* 1992 ; 284 : 34-46.
35. **Zindrick M, Wiltse L, Widell EH.** A biomechanical study of intrapedicular screw fixation in the lumbosacral spine. *Clin Orthop* 1986 ; 203 : 99-112.