



Management of distal clavicle fractures

Ilias BISBINAS, Petros MIKALEF, Ioannis GIGIS, Theodoros BESLIKAS, Nikolaos PANOU, Ioannis CHRISTOFORIDIS

From Aristotle University of Thessaloniki, Greece

Management of type II distal clavicle fractures has always been a challenge. Non-operative treatment has a high risk of complications and should be considered only for elderly and frail patients. For younger and active patients there is a wide variety of operative options, each with advantages and disadvantages. According to our unit's experience the first choice could be hook plate fixation, with very good and reproducible results. Another option could be Kirschner-wire fixation with or without tension band wiring ; however, because of potential wire complications or difficulties in rehabilitation, the method should be reserved for reliable patients and used with a meticulous technique.

Keywords : distal clavicle fractures ; management.

INTRODUCTION

The management of fractures of the distal clavicle has been a matter of debate in literature. Neer in 1968 suggested a new classification and proposed general treatment guidelines (14). Type I and type III fractures are generally treated non-operatively. For type II fractures, although surgical management is the treatment of choice, some authors suggest conservative treatment owing to the high rate of complications in particular circumstances.

Classification

Neer in 1968 classified distal clavicle fractures according to their location in relation to the coraco-

clavicular ligaments (14). Type I fractures are stable fractures located lateral to the coracoclavicular ligament complex. Type II fractures are complex unstable fracture-dislocations which leave the distal end of the clavicle and the acromioclavicular (AC) joint untouched, separating the clavicle from the underlying coracoclavicular ligament complex through a vertical or oblique fracture line (fig 1). Type III fractures are intra-articular fractures into the AC joint causing late posttraumatic arthritis and pain (14).

Rockwood, in 1982, subclassified type II fractures in type IIa and IIb fractures. In type IIa fractures, the fracture line is located medial to the coracoclavicular ligaments and both trapezoid and conoid ligaments remain connected to the distal fragment. In type IIb fractures, the fracture line is located between the coracoclavicular ligaments : the trapezoid ligament remains intact whereas the conoid ligament is ruptured (19,22).

-
- Ilias Bisbinas, MD, Orthopaedic Consultant.
 - Petros Mikalef, MD, Orthopaedic Consultant.
 - Ioannis Gigis, MD, Lecturer in Orthopaedics.
 - Theodoros Beslikas, MD, Assistant Professor.
 - Nikolaos Panou, MD, Orthopaedic Consultant.
 - Ioannis Christoforidis, MD, Professor and Director.
- 2nd Orthopaedic Department, Aristotle University of Thessaloniki, "G. Gemmatas" General Hospital, Ethnikis Aminis, Thessaloniki, Greece.*

Correspondence : Ioannis GIGIS, Profiti Ilia 13, Pylea, 55535, Thessaloniki, Greece. E-mail : jgigis@otenet.gr
© 2010, Acta Orthopædica Belgica.

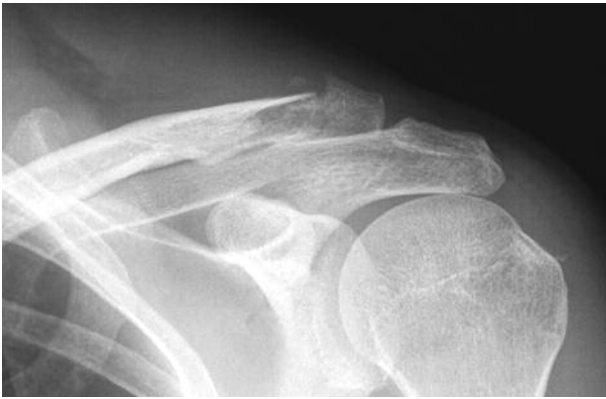

Fig. 1. — Fracture of distal clavicle (classified as Neer type II)

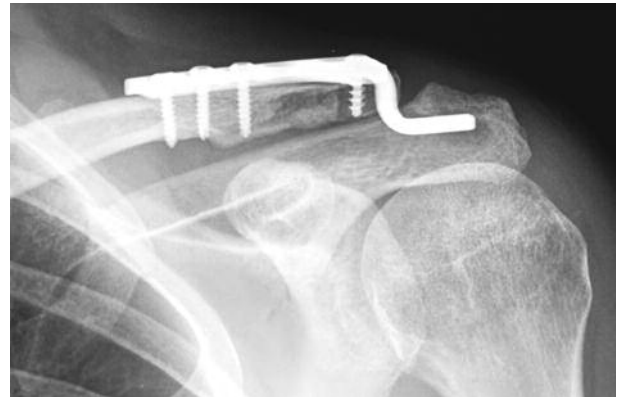


Fig. 2. — Fracture of distal clavicle which was treated using hook plate fixation (O.R.I.F.).

Robinson in 1998 suggested a further classification combining the above mentioned principles ; it has not been widely accepted (20).

Treatment

Treatment of type I and type III fractures does not appear to be debated : most authors suggest conservative treatment with a period of immobilization in a sling followed by physiotherapy (3). A potential late complication of intra-articular type III fractures is post-traumatic AC joint arthritis ; when this is symptomatic, excision of the lateral end of the clavicle is suggested (19).

There is a wide variety of treatment options for Neer type II fractures, all of them based on the particular deformity and lack of stability. Bone fragments are displaced due to forces that act in opposite directions. The weight of the upper extremity, pull of the latissimus dorsi, pectoralis major and minor muscles, as well as rotation of the scapula displace the distal clavicular fragment downwards and medially, while upon moving the upper extremity, the distal fragment rotates and tilts even further. The trapezius muscle pulls the proximal fragment upwards and backward. As a result of the displacement of proximal and distal bone fragments, malunion is commonly seen after non-operative treatment (10,21,23). Most authors consider that the high risk of complications observed after conservative

management makes operative treatment the most prudent choice.

Operative treatment consists of open reduction and internal fixation (ORIF) of the fracture. Several methods of fixation have been suggested, but none of them has been considered the «gold standard» (19,22,24). Transacromial fixation using Kirschner wires, cerclage wiring of the fragments, tension band wiring, plate fixation, osteosynthesis using a hook plate (fig 2), stabilization of the medial fragment with either a coracoclavicular screw or coracoclavicular slings have been mentioned in literature (5,19,22,24). The fixation hardware is usually removed 8 weeks postoperatively as soon as radiological consolidation of the fracture is observed. All those operative methods have their own advantages and disadvantages.

In transacromial fixation, Kirschner wires or Knowles pins are introduced through the lateral side of the acromion after open reduction of the fracture (4,5,6). Disadvantage of the method is that the stabilization of the fracture is poor, and early mobilization of the arm is therefore not suggested (9). The reported infection and non-union rates are high, up to 23% (6). Injury to the AC joint may be followed by arthritis, with a rate of 10%. The incidence of pin migration is reportedly high (1,5,13). Lyons and Rockwood in 1990 reviewed all reports about pin migration in the AC joint surgery in literature (13). They found

37 reports with pin migration into the thorax, subclavian artery, ascending aorta, cervicothoracic junction of the spine and spinal canal. In some cases, pins caused complications (pneumothorax or false aneurysm of the ascending aorta) while in other cases, pins were discovered incidentally (13).

Using an extra-articular tension band, injury to the AC joint is avoided, however pins may migrate, they may cause skin problems and they may need to be removed under general anaesthesia (5).

Stabilization of the proximal fragment using a coracoclavicular screw seems to have several advantages, as it provides good stabilization through a very small incision with minimal tissue dissection, without violating the AC joint. The fracture is reduced and held in place using a threaded screw with a washer under direct vision, connecting the clavicle and the coracoid process. Postoperatively the upper extremity is placed in a sling and instructions are given to the patient to avoid abduction and forward flexion of the arm beyond 90°. After radiological consolidation of the fracture the screw is removed under local anaesthesia. Complications of the method include backing of the screw, mainly in patients who do not follow the postoperative instructions, and, since the screw allows a substantial degree of rotational movements of the clavicle, the screw may fracture. Advantages of the method include the low cost of the procedure (5).

Stable osteosynthesis with open reduction and internal fixation using plate and screws is technically difficult because of the small size of the distal bone fragment. As a result early mobilisation is not suggested (9). Osteosynthesis using a 3.5 mm LCDC plate (Balser plate), followed by suturing of the coracoclavicular ligament has been described (7). There is high risk of devascularising the clavicle, as well as a risk of stress shielding and re-fracture of the clavicle during implant removal (1,5).

Clinical outcome after ORIF of distal clavicular fractures using a hook plate first appeared in literature in 1983 (24). Several plates have been described in the literature including the Balser plate, the Wolter plate, the AO clavicular hook plate, with common features regarding their design and tech-

nique of surgical application (24). After fracture reduction the hook of the plate is introduced under the acromion either through a hole drilled in it or without bone drilling through the posterior part of it, and stabilization of the fracture is then performed. The upper arm is held in a sling for 2 weeks and pendulum exercises and physiotherapy are then started. Patients are instructed to avoid forward flexion, abduction over 90° and internal rotation of the shoulder until the implant is removed so that there is not too much pressure between the plate and the acromion, and fracture of the implant is avoided (9,11). The plate is removed when radiological consolidation of the fracture is observed, followed by full range of motion exercises (11).

Biomechanically the hook plate seems not to limit rotational movements of the clavicle during flexion and abduction of the humerus. It seems that stability of the fracture is preserved without disturbing the biomechanics of the AC joint (9). Complications of the method include fracture of the plate's hook, cut-out, enlargement of the hook's hole in the acromion, which was observed just before removing the implant causing no functional complaints, upward migration of the hook in the subacromial space, tear of the rotator cuff and cut out of the screws (2,11). Reviewing patients about 3 years postoperatively, authors reported that they have high incidence of rotator cuff tears, as well as extra-articular ossification around the AC joint (8,9). One of the major disadvantages of the method is that the patient needs general anaesthesia for plate removal. The AO plate is reported to have an advantage over other hook plates because its hook is eccentric and is placed at the posterior part of the acromion without the need to drill a hole (2,11).

Flinkkilä in 2002 compared the clinical results of 22 patients treated with the use of K-wires combined with tension bands in 16 of them, and 17 patients treated with a hook plate. Although functional results were similar, the complication rate in the K-wires group was high, approaching the complication rate of conservative treatment. Non-union was diagnosed in four of those patients, but only one of them had to be re-operated due to persistent symptoms. Additionally, subjective results

were better in patients treated with the hook plate (6).

In order to substitute the coracoclavicular ligaments, coracoclavicular slings of PDS, Dacron suture, synthetic Mersilene tape or Dacron arterial graft have been used. The sling is passed around the medial bone fragment of the clavicle and the base of the coracoid process (25). Disadvantages include the need for a relatively more extensive exposure to the coracoid process and potential complications such as fracture of the coracoid process (5).

Hessman *et al* in 1997 suggested that, if the distal fragment is big enough so that at least 3 screws can be placed, osteosynthesis with a plate should be used. If the distal fragment is too small, it should be "stitched" to the proximal part of the clavicle using a PDS suture, which should be followed by suturing of the ligaments (10).

Neviaser in 1995 presented a technique in which the fracture is fixed with cerclage wiring through a small vertical incision between the fracture site and the AC joint. Usually three loops are used perpendicular to the fracture line. To use this technique the fracture line must be oblique, as fractures usually are in this region. If the fracture is transverse it is suggested that it should be treated with transacromial K-wires (16).

Levy in 2003 presented another minimally invasive technique. Through very small skin incisions it is possible to drill both bone fragments antero-posteriorly close to the edges, passing a double PDS suture loop and forming a figure of eight to hold/fix the fracture. Levy reported good results with no specific complications using that method. Advantages include the fact that it is simple and minimally invasive for the surrounding soft tissues, which encourages quick consolidation of the fracture and fast return to full activities. Additionally, there is no need for a second operation for implant removal, biomechanics and movements of the clavicle are preserved and there is good cosmetic result (12).

Nourissat *et al* in 2007 reported an endoscopically assisted method for Neer fixation of type II fractures and reconstruction of the coracoclavicular ligaments. It reportedly allows early mobilization and return to sports by the 9th postoperative week (18).

It should be mentioned that quite a few authors suggest non-operative treatment of these fractures. Robinson and Cairns in 2004 reported acceptable clinical results after treating 101 patients and suggest that non-operative treatment is a safe and effective alternative to treat the majority of closed displaced fractures of the distal end of the clavicle (21). According to strict indications, the authors treated operatively only compound fractures or fractures with skin tension and the rest of the patients were treated non-operatively, in a sling for two weeks followed by physiotherapy. The patients who developed non-union and symptomatic AC arthritis that affected their everyday living activities were operated in a second stage. In 101 patients presented by the authors, only 14 had to be operated at a second stage, leaving 87 patients for whom surgery was not needed. They report that those fractures usually occur in older low-demand patients, which may be why the majority of those patients had a very good clinical outcome after conservative management and patients that needed a second stage operation generally had a younger age (21).

Nordqvist *et al* in 1993 reported that in 23 patients with Neer type II fractures who were treated non-operatively 10 had radiological non-union, from which 8 had no symptoms and 2 had only mild symptoms not severe enough to require a second stage operation (17). Deafenbaugh in 1990 also reported clinical results of non-operative treatment for those fractures suggesting it is an effective alternative (3).

In our unit with special interest in shoulder surgery, we had 43 patients with type II distal clavicle fractures during the last six years. We performed K-wire fixation in 26 patients, either combined with or without tension band wiring, Bosworth screw «fixation» in 3 patients and hook plate fixation in 14 patients ; the latter was our preferred treatment during the last period of time. Although we never had major complications from K-wire fixation, most of them had pin tract infection which needed close follow-up and patient's reassurance, and mainly difficulties in rehabilitation, which is much slower in that case. From our experience, we believe that the hook plate option is preferable to the other methods of fixation because it is reproducible and

safe, independent of the patient's reliability. The hook plate should be applied with due respect to adjacent soft tissues. Patients should be informed that the skin scar in this area is sometimes hypertrophic. However, with early shoulder mobilisation, which is the cornerstone of shoulder rehabilitation, the patient can achieve full range of movement and a high functional outcome.

REFERENCES

- Ballmer FT, Gerber C.** Coracoclavicular screw fixation for unstable fractures of the distal clavicle. A report of five cases. *J Bone Joint Surg* 1991 ; 73-B : 291-294.
- Charity RM, Haidar SG, Ghosh S, Tillu AB.** Fixation failure of the clavicular hook plate : a report of three cases. *J Orthop Surg (Hong Kong)* 2006 ; 14 : 333-335.
- Deafenbaugh MK, Dugdale TW, Staeheli JW, Nielsen R.** Nonoperative treatment of Neer type II distal clavicle fractures : a prospective study. *Contemp Orthop* 1990 ; 20 : 405-413.
- Fann CY, Chiu FY, Chuang TY, Chen CM, Chen TH.** Transacromial Knowles pin in the treatment of Neer type 2 distal clavicle fractures. A prospective evaluation of 32 cases. *J Trauma* 2004 ; 56 : 1102-1105.
- Fazal MA, Saksena J, Haddad FS.** Temporary coracoclavicular screw fixation for displaced distal clavicle fractures. *J Orthop Surg (Hong Kong)* 2007 ; 15 : 9-11.
- Flinkkilä T, Ristiniemi J, Hyvönen P, Hämäläinen M.** Surgical treatment of unstable fractures of the distal clavicle : a comparative study of Kirschner wire and clavicular hook plate fixation. *Acta Orthop Scand* 2002 ; 73 : 50-53.
- Fuchs M, Losch A, Stürmer KM.** [Surgical treatment of fractures of the clavicle – Indication, surgical technique and results.] (in German). *Zentralbl Chir* 2002 ; 127 : 479-484
- Hackenberger J, Schmidt J, Altmann T.** [The effects of hook plates on the subacromial space – a clinical and MRT study.] (in German). *Z Orthop Ihre Grenzgeb* 2004 ; 142 : 603-610.
- Haidar SG, Krishnan KM, Deshmukh SC.** Hook plate fixation for type II fractures of the lateral end of the clavicle. *J Shoulder Elbow Surg* 2006 ; 15 : 419-423.
- Hessmann M, Gotzen L, Kirchner R, Gehling H.** [Therapy and outcome of lateral clavicular fractures.] (in German). *Unfallchirurg* 1997 ; 100 : 17-23.
- Kashii M, Inui H, Yamamoto K.** Surgical treatment of distal clavicle fractures using the clavicular hook plate. *Clin Orthop Relat Res* 2006 ; 447 : 158-164.
- Levy O.** Simple, minimally invasive surgical technique for treatment of type 2 fractures of the distal clavicle. *J Shoulder Elbow Surg* 2003 ; 12 : 24-28.
- Lyons FA, Rockwood CA Jr.** Migration of pins used in operations on the shoulder. *J Bone Joint Surg* 1990 ; 72-A : 1262-1267.
- Neer CS.** Fractures of the distal clavicle. *Clin Orthop Relat Res* 1968 ; 58 : 43-50.
- Neer CS.** Fracture of the distal clavicle with detachment of the coracoclavicular ligaments in adults. *J Trauma* 1963 ; 3 : 99-110.
- Thompson RC, Craig EV.** *The Shoulder.* Master Techniques in Orthopaedic Surgery. Raven Press, New York, 1995, pp 199-212.
- Nordqvist A, Petersson C, Redlund-Johnell I.** The natural course of lateral clavicle fracture. 15 (11-21) year follow-up of 110 cases. *Acta Orthop Scand* 1993 ; 64 : 87-91.
- Nourissat G, Kakuda C, Dumontier C, Sautet A, Doursounian L.** Arthroscopic stabilization of Neer type 2 fracture of the distal part of the clavicle. *Arthroscopy* 2007 ; 23 : 674.e1-4. Epub.
- Nuber GW, Bowen MK.** Acromioclavicular joint injuries and distal clavicle fractures. *J Am Acad Orthop Surg* 1997 ; 5 : 11-18.
- Robinson CM.** Fractures of the clavicle in the adult. Epidemiology and classification. *J Bone Joint Surg* 1998 ; 80-B : 476-484.
- Robinson CM, Cairns DA.** Primary non-operative treatment of displaced lateral fractures of the clavicle. *J Bone Joint Surg* 2004 ; 86-A : 778-782.
- Rockwood CA Jr.** Fractures of the outer clavicle in children and adults. *J Bone Joint Surg* 1982 ; 64-B : 642.
- Rokito AS, Zuckerman JD, Shaari JM, et al.** A Comparison of non-operative and operative treatment of type II distal clavicle fractures. *Bull Hosp Jt Dis* 2002-2003 ; 61 : 32-39.
- Schmittinger K, Sikorski A.** [Experiences with the Balsler plate in dislocations of the acromioclavicular joint and lateral fractures of the clavicle.] (in German). *Aktuelle Traumatol* 1983 ; 13 : 190-193
- Webber MC, Haines JF.** The treatment of lateral clavicle fractures. *Injury* 2000 ; 31 : 175-179.