



Treatment of solitary bone cysts with allogenic bone graft and platelet-rich plasma. A preliminary report

Piotr PĘDZISZ, Marcin ZGODA, Hanna KOCON, Grzegorz BENKE, Andrzej GÓRECKI

From the Medical University of Warsaw, Poland

The treatment of solitary bone cysts remains controversial. The high recurrence rate after operative treatment calls for the search of new effective treatment methods.

The aim of this study was to evaluate the outcomes of treatment of solitary bone cysts with platelet-rich plasma (PRP) and allogenic bone grafts.

The study group consisted of 9 patients (4 males and 5 females) with the diagnosis of solitary bone cyst. Their mean age was 12 years and 2 months (range : 6 to 17 years). All patients were symptomatic in routine daily activities. There was a coexisting fracture within the cyst wall in three patients.

The operative procedure included removal of the cyst wall soft-tissue lining and filling of the cavity with deep frozen, gamma irradiated morselized allogenic bone grafts mixed with PRP. The PRP was prepared preoperatively with the GPS System (Gravitational Platelet Separation System, Biomet Merck®). In six patients with an existing or impending fracture in particularly large cysts, fixation was used. For the cysts located close to the epiphysis (2 femurs, 1 humerus) we used an IM nail or DHS. For three cysts located in the diaphyseal region of the humerus we used an Ilizarov fixator. Three cysts with lower risk of impending fracture were left without fixation. The mean follow-up period was 19.5 months (range : 12 to 30).

We noted no procedure-related complications and no refracture during the observation period. Bleeding from the wound was minimal, possibly as a result of PPP use. The wounds healed without swelling or excessive scar formation. After 12 months all the cysts were completely filled with new bone and were staged

as Neer stage I. All the patients were asymptomatic. The use of PRP with allogenic bone grafts appears as a promising method for the treatment of solitary bone cysts. Further studies on larger patients series with longer follow-up will be necessary to answer the question whether this method will provide a lower recurrence rate compared to other forms of treatment.

Keywords : platelet-rich plasma (PRP) ; solitary bone cyst ; growth factors.

INTRODUCTION

Solitary bone cyst, also known as unicameral or simple bone cyst is a benign, radiolucent, fluid filled tumour-like lesion of child age. It is observed

-
- Piotr Pędzisz, Orthopaedic Surgeon.
 - Marcin Zgoda, MD, Orthopaedic Surgeon.
 - Hanna Kocon, Orthopaedic Surgeon.
 - Grzegorz Benke, MD, Orthopaedic Surgeon.
 - Andrzej Górecki, MD, PhD, Professor of Orthopaedic Surgery.

Department of Orthopaedics and Traumatology of the Locomotor System, Medical University of Warsaw, Poland.

Correspondence : Piotr Pędzisz, Department of Orthopaedics and Traumatology of the Locomotor System, The Medical University of Warsaw, 4 Lindley St. 02-005, Warsaw, Poland.

E-mail : piotrek.pedzisz@yahoo.com

© 2010, Acta Orthopædica Belgica.

most frequently in children between ages 5 and 15. Solitary bone cysts account for 3% of all bone tumours and tumour-like conditions and may coexist with other benign tumours (14,21). The most common localizations are the proximal humerus and proximal femur ; however, every bone in the human skeleton can be affected. The aetiology is still unknown. There are several theories concerning cyst formation (9,11,13). The cyst is often asymptomatic and for this reason the initial diagnosis is often made after a radiological examination performed for other reasons. Pain in the affected region may be present, but frequently the first and only symptom may be a pathological fracture following a trivial trauma (6).

The treatment of solitary bone cysts remains controversial (4). The decision whether to operate or not depends on the individual case and is based on numerous factors. Still, the attempts to use objective scales like the cyst index for prediction of a pathological fracture risk seem to be reasonable (17). A surgical procedure is indicated for active cysts with an increased fracture risk and for those in weight bearing parts of the skeleton. The therapeutic options include corticosteroid injections into the cyst, autologous bone marrow injections, drilling of the cyst walls (3,6,18,20). Another method is removal of the cyst wall lining and filling with autologous/allogenic bone or bone substitutes like demineralized bone matrix (DBM), calcium phosphate ceramic or high-porosity hydroxyapatite (1,16). The high rate of cyst recurrence after operative treatment calls for the search of new, successful treatment methods. At present, growth factors (GFs) and bone morphogenetic proteins (BMPs) with their bone healing stimulating properties bring hope to improve the treatment results in patients with bone defects, either posttraumatic or secondary to bone resorption, such as solitary bone cysts (15). The cost of recombinant GFs and BMPs however restricts their use in clinical practice to a limited number of academic and reference centers. The cost-effective, alternative method to expensive treatment with GFs and BMPs may be the use of autologous growth factors in the form of platelet-rich plasma (PRP) (5,19). The positive effect of PRP with allogenic bone grafts on healing of bone

defects has been demonstrated by *in vitro* and *in vivo* studies (23,26,29). The aim of this study was to evaluate the results of solitary bone cysts treatment with allogenic bone grafts combined with PRP in children.

MATERIAL AND METHODS

The study group consisted of 9 consecutive children (4 males and 5 females) admitted to our hospital with a diagnosis of solitary bone cyst. Their mean age was 12 years and 2 months (range : 6 to 17 years). All the patients were symptomatic in routine daily activities. There was a fracture within the cyst wall in three patients. Exclusion criteria included malignant tumours, bone marrow and blood disease, chemotherapy or chronic steroid use. The study was approved by the institutional review board.

The operative procedure included removal of the cyst wall tissue and filling of the cyst with morselized allogenic bone grafts soaked with PRP. The PRP was prepared preoperatively with the GPS System (Gravitational Platelet Separation System ; Biomet Merck®). The system enables the 3 to 8 fold concentration of platelets, resulting in higher levels of growth factors, compared to the peripheral blood, which are subsequently released from the alpha granules. The local action of concentrated growth factors initiates the „jump start” of the early stages of the bone healing cascade, resulting in enhanced new bone formation and remodeling.

PRP preparation and surgical procedure

On the day of surgery 54 ml of blood was drawn on 6 ml of anticoagulant. Another 8 ml was drawn with no anticoagulant and left to clot. The system used was the GPS System (Gravitational Platelet Separation System, Biomet Merck®). The blood was centrifuged for 15 minutes at 3200 rpm. Every procedure yielded 8 to 10 ml of PRP and about 30 ml of platelet-poor plasma (PPP). The clot was then centrifuged for 2.5 minutes with the same speed, and the procedure resulted in 2 ml of autologous thrombin. Intraoperatively the PRP was mixed with thrombin and calcium chloride and the allogenic bone grafts were then added. The fibrous lining of the cavity was meticulously removed, and the specimens were sent for histopathology. The bone-PRP mixture was then packed into the cavity. During closure of the wound, platelet-poor plasma (PPP) with thrombin and calcium chloride was sprayed on the exposed soft tissues in order

Table I. — Cyst location and methods of treatment

Patient	Cyst location	Fracture	Treatment
1	Proximal femur	-	Curettage, allogenic bone, PRP, internal fixation (DHS)
2	Proximal femur	+	Curettage, allogenic bone, PRP, internal fixation (Gamma nail)
3	Proximal humerus	-	Curettage, allogenic bone, PRP, internal fixation (IM nail)
4	Midshaft humerus	+	Curettage, allogenic bone, PRP, external fixation (Ilizarov)
5	Proximal humerus	-	Curettage, allogenic bone, PRP
6	Midshaft humerus	+	Curettage, allogenic bone, PRP, external fixation (Ilizarov)
7	Proximal tibia	-	Curettage, allogenic bone, PRP
8	Midshaft humerus	-	Curettage, allogenic bone, PRP, external fixation (Ilizarov)
9	Proximal femur	-	Curettage, allogenic bone, PRP

Table II. — Neer's classification system for radiographic evaluation of cyst healing

Neer's Classification System	
Stage I	100% cyst filling with new bone
Stage II	Partial cyst filling, increased cortical thickness
Stage III	Recurrence, cortical thinning, osteolytic areas > 3 cm
Stage IV	No response to treatment

to decrease bleeding. In three cases with a coexisting fracture within the cyst wall, we routinely used fixation. Fixation was also used in three additional cases without coexisting fracture, but with an increased fracture risk due to particularly large cyst diameter and very thin wall. Internal fixation (IM nail or DHS) was used in three cysts located close to the epiphysis (2 femurs, 1 humerus). An Ilizarov Fixator was used for three cysts located in the diaphyseal region of the humerus (table I). Three cysts were left without fixation. No drains were left in the wound. Radiographs were taken at 3, 6 and 12 months postoperatively. The Neer classification system (24,25) was used for evaluation of the radiographs (table II).

RESULTS

We observed no complications related to the procedure and no refracture during the observation period. Bleeding from the wound was minimal, which may be related to the haemostatic action of PPP. The average hospital stay was 3 days. The wounds healed quickly without swelling or excessive scar formation. The mean follow-up period was 19.5 months (range: 12 to 30 months). After 12 months all the cysts were completely filled with

new bone and were evaluated radiologically as Neer stage I. All the patients were asymptomatic. The range of motion of the adjacent joints was comparable to the contralateral side. The internal fixation hardware, if any, was removed 12 months postoperatively (fig 1-3).

DISCUSSION

The choice of treatment of solitary bone cysts, especially those without a coexisting fracture, is still controversial. Treatment options include curettage with bone grafting, injection of steroids, bone marrow, demineralized bone matrix or calcium sulphate, perforation of the cyst wall and decompression (32).

For many years steroid injection was considered a standard treatment for solitary bone cysts, with reported success rates of about 90%. This led some authors to completely discontinue operative treatment with curettage and bone grafting (8,27,28). The initial studies by Lokiec *et al* (21) showed 100% cyst healing rate after percutaneous injection of bone marrow, making it the treatment of choice for many surgeons. However, subsequent studies on bone marrow injection showed significantly lower healing rates, about 67 to 76% (12,34). A recent randomized trial by Wright *et al* (33) demonstrated even lower effectiveness of bone marrow (23% of healed cysts), compared to steroid injection (42% of healed cysts). These discrepancies may arise from various protocols being used for marrow preparation and dissimilarity of the cellular content of the marrow aspirate. Still, the new methods of bone marrow concentration by centrifugation may result in high-

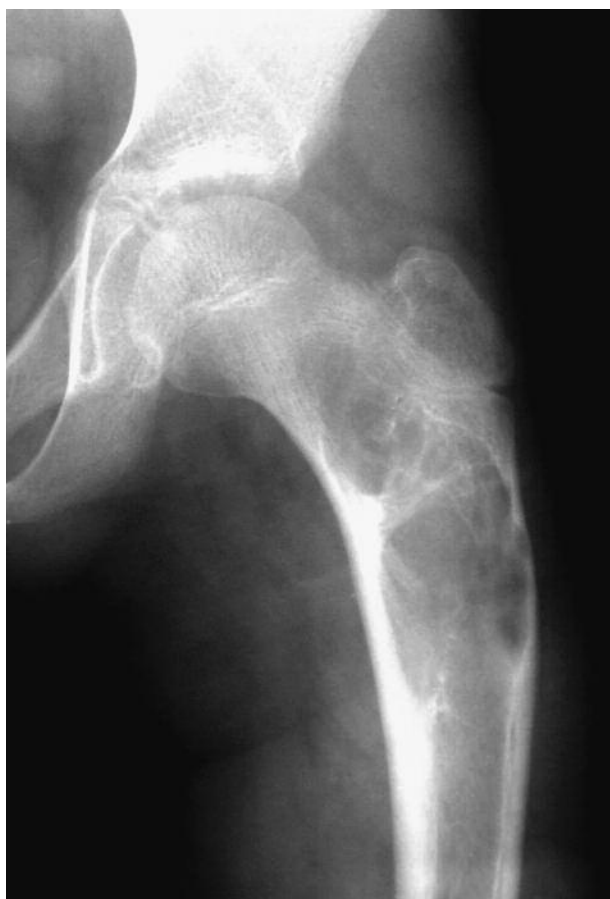

Fig. 1. — A solitary bone cyst of the proximal part of the left femur in a 13-year-old boy.

er, homogenous cellular yields and subsequently higher healing rate. So far, no studies using concentrated bone marrow have been published. However, the results of repeated injections appear more optimistic. The comparative study by Cho *et al* showed a 23.3% success rate after a first steroid injection and 52% after a first bone marrow injection. With the second injection the healing rates rose to 63.3% and 80% respectively. The authors achieved final success rates of 86.7% with an average of 2.19 steroid injections, and 92% with 1.57 bone marrow injections (10). A recent study by Thavrani *et al* showed the effectiveness of apatitic calcium phosphate (alpha-BSM) in healing of recurrent simple bone cysts. Most of their 13 patients had a previous history of pathologic fracture and unsuccessful surgical treatment. Despite the fact that only five cysts

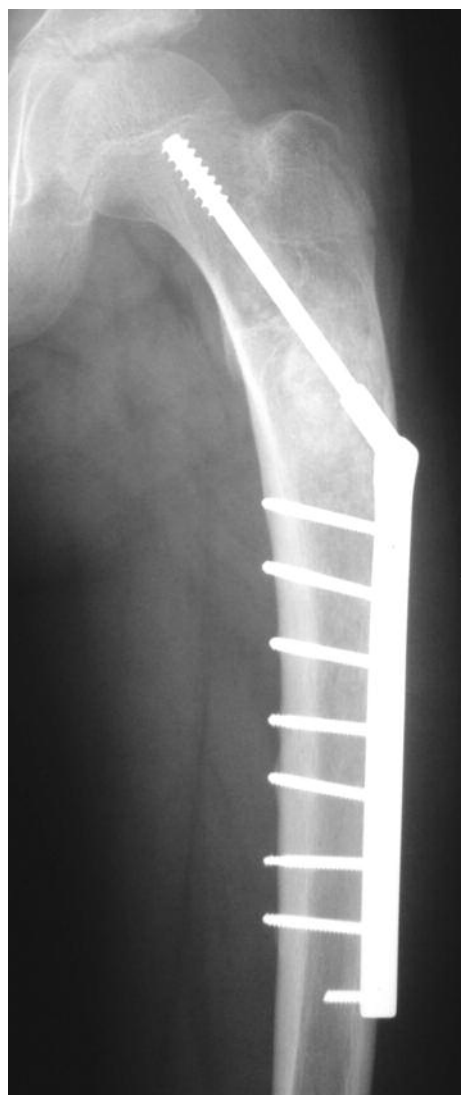

Fig. 2. — Radiograph 3 months after surgery

were grade I, six grade II and two grade III, the average decrease in cyst area in 11 cases was 85.7% (31).

Despite the numerous studies of bone marrow in the treatment of solitary bone cysts, we were not able to find any studies concerning the application of PRP. The alpha granules of the blood platelets contain such growth factors as platelet-derived growth factor (PDGF), transforming growth factor beta (TGF beta), vascular endothelial growth factor (VEGF), insulin-like growth factor (IGF) and many

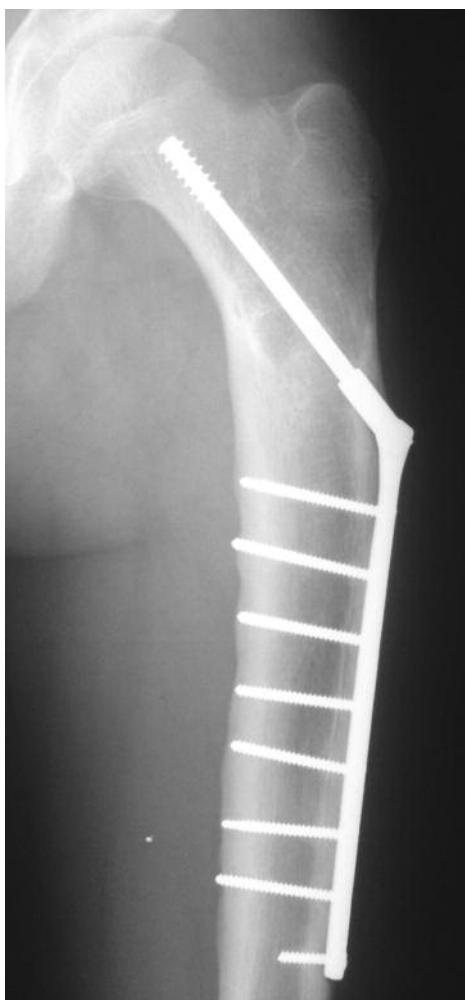


Fig. 3. — Radiograph of the same patient 12 months after surgery. The cavity is filled with new bone.

others. These factors play an important role in the early phase of fracture healing and may thus encourage healing of the cyst and decrease the recurrence rate. The use of platelet concentrate harvested from the patient's own blood has been showed to be effective in the treatment of bone defects (23), in distraction osteogenesis (26) and lumbar spine fusion (5,22). Our previous studies suggest that soaking of allogeneic bone grafts with PRP may lead to faster graft incorporation (2).

Both radiographic and clinical results of this study suggest that bone grafting with PRP is a safe and effective method for the treatment of solitary

bone cysts. However, due to the relatively short observation period, the question whether this particular method provides lower recurrence rates compared to other forms of treatment cannot be answered. Also bearing in mind that curettage and grafting is already a treatment with an appreciable success rate (7,30), and opening of the medullary canal with internal fixation also decreases the recurrence rate, we are not able to estimate the specific effect of PRP.

It is also not entirely clear whether bone grafting and PRP is more cost effective compared to other treatment methods. We were not able to find any studies directly concerning the cost effectiveness of solitary bone cyst treatments. This issue definitely needs further research. A single steroid or bone marrow injection appears less expensive than PRP, which needs a separation kit costing about 400\$ and a centrifuge. However, it is the recurrence rate that will establish the real cost effectiveness of these procedures.

The whole issue needs further observation and a larger group of patients. However, the authors find the above described method of solitary bone cysts treatment promising especially for the cysts with accompanying fracture, or in cases with a high risk of fracture.

REFERENCES

1. **Altermatt S, Schwobel M, Pochon JP.** Operative treatment of solitary bone cysts with tricalcium phosphate ceramic. A 1 to 7 year follow-up. *Eur J Pediatr Surg* 1992 ; 2 : 180-182.
2. **Ambroziak M, Pędzisz P, Górecki A et al.** Rehabilitation programme for patients after primary reconstruction of ACL with allogenic BTB patellar or Achilles tendon graft. *Arthrosc Joint Surg* 2006 ; 2 : 30-36.
3. **Arazi M, Senaran H, Memik R et al.** Minimally invasive treatment of simple bone cysts with percutaneous autogenous bone marrow injection. *Orthopedics* 2005 ; 28 : 108-112.
4. **Bensahel H, Jehanno P, Desgrippes Y, Pennecot GF.** Solitary bone cyst : controversies and treatment. *J Pediatr Orthop* 1998 ; 7-B : 257-261.
5. **Bose B, Balzarini MA.** Bone graft gel : autologous growth factors used with autograft bone for lumbar spine fusions. *Adv Ther* 2002 ; 19 : 170-175.
6. **Bovill DE, Skinner HB.** Unicameral bone cysts. A comparison of treatment options. *Orthop Rev* 1989 ; 18 : 420-427.

7. **Bumci I, Vlahovi T.** Significance of opening the medullary canal in surgical treatment of simple bone cyst. *J Pediatr Orthop* 2002 ; 22 : 12512-9.
8. **Campanacci M, Capanna R, Picci P.** Unicameral and aneurysmal bone cysts. *Clin Orthop Relat Res* 1986 ; 204 : 25-36.
9. **Chigira M, Maehara S, Arita S, Udagawa E.** The aetiology and treatment of simple bone cysts. *J Bone Joint Surg* 1983 ; 65-B : 633-637.
10. **Cho HS, Oh JH, Kim HS, Kang HG, Lee SH.** Unicameral bone cysts : a comparison of injection of steroid and grafting with autologous bone marrow. *J Bone Joint Surg* 2007 ; 89-B : 222-6.
11. **Cohen J.** Simple bone cysts. Studies of cyst fluid in six cases with a theory of pathogenesis. *J Bone Joint Surg* 1960 ; 42-A : 609-616.
12. **Docquier PL, Delloye C.** Treatment of simple bone cysts with aspiration and a single bone marrow injection. *J Pediatr Orthop* 2003 ; 23 : 766-773.
13. **Gebhart M, Blaimont P.** Contribution to the vascular origin of the unicameral bone cyst. *Acta Orthop Belg* 1996 ; 62 : 137-143.
14. **Godette GA, Rooney RJ.** Two different non-neoplastic lesions in the same long bone. *Contemp Orthop* 1995 ; 30 : 395-398.
15. **Górecki A.** [Growth factors and bone tissue.] (in Polish). Oficyna Wydawnicza ASPRA-JR, Warszawa, 2004, pp 37-95.
16. **Inoue O, Ibaraki K, Shimabukuro H et al.** Packing with high-porosity hydroxyapatite cubes alone for the treatment of simple bone cyst. *Clin Orthop Relat Res* 1993 ; 293 : 287-292.
17. **Kaelin AJ, MacEwen GD.** Unicameral bone cysts. Natural history and the risk of fracture. *Int Orthop* 1989 ; 13 : 275-282.
18. **Kanellopoulos AD, Yiannakopoulos CK, Soucacos PN.** Percutaneous reaming of simple bone cysts in children followed by injection of demineralized bone matrix and autologous bone marrow. *J Pediatr Orthop* 2005 ; 25 : 671-675.
19. **Kassolis JD, Rosen PS, Reynolds MA.** Alveolar ridge and sinus augmentation utilizing platelet-rich plasma in combination with freeze-dried bone allograft : case series. *J Periodonto* 2000 ; 71 : 1654-1661.
20. **Komiya S, Minamitani K, Sasaguri Y et al.** Simple bone cyst. Treatment by trepanation and studies on bone resorptive factors in cyst fluid with a theory of its pathogenesis. *Clin Orthop Relat Res* 1993 ; 297 : 204-211.
21. **Lokiec F, Ezra E, Khermosh O, Wientroub S.** Simple bone cysts treated by percutaneous autologous marrow grafting. A preliminary report. *J Bone Joint Surg* 1996 ; 78-B : 934-937.
22. **Lowery GL, Kulkarni S, Pennisi AE.** Use of autologous growth factors in lumbar spinal fusion. *Bone* 1999 ; 25 (2 Suppl) : 47S-50S.
23. **Marx RE, Carlson ER, Eichstaedt RM et al.** Platelet-rich plasma : Growth factor enhancement for bone grafts. *Oral Surg Oral Med Oral Pathol Oral Radiol Endod.* 1998 ; 85 : 638-646.
24. **Neer CS, Francis KC, Johnston AD et al.** Current concepts on the treatment of solitary unicameral bone cyst. *Clin Orthop Relat Res* 1973 ; 97 : 40-51.
25. **Neer CS, Francis KC, Marcove RC et al.** Treatment of unicameral bone cyst. *J Bone Joint Surg* 1966 ; 48-A : 731-745.
26. **Robiony M, Polini F, Costa F et al.** Osteogenesis distraction and platelet-rich plasma for bone restoration of the severely atrophic mandible : preliminary results. *J Oral Maxillofac Surg* 2002 ; 60 : 630-635.
27. **Scaglietti O, Marchetti PG, Bartolozzi P.** The effects of methylprednisolone acetate in the treatment of bone cysts. Results of three years follow-up. *J Bone Joint Surg* 1979 ; 61-B : 200-204.
28. **Scaglietti O, Marchetti PG, Bartolozzi P.** Final results obtained in the treatment of bone cysts with methylprednisolone acetate (depo-medrol) and a discussion of results achieved in other bone lesions. *Clin Orthop Relat Res* 1982 ; 165 : 33-42.
29. **Slater M, Patava J, Kingham K et al.** Involvement of platelets in stimulating osteogenic activity. *J Orthop Research* 1995 ; 13 : 655-663.
30. **Spence KF Jr, Bright RW, Fitzgerald SP, Sell KW.** Solitary unicameral bone cyst : treatment with freeze-dried crushed cortical-bone allograft. A review of one hundred and forty-four cases. *J Bone Joint Surg* 1976 ; 58-A : 636-641.
31. **Thawrani D, Thai CC, Welch RD, Copley L, Johnston CE.** Successful treatment of unicameral bone cyst by single percutaneous injection of alpha-BSM. *J Pediatr Orthop* 2009 ; 29 : 511-517.
32. **Wilkins RM.** Unicameral bone cysts. *J Am Acad Orthop Surg* 2000 ; 8 : 217-224.
33. **Wright JG, Yandow S, Donaldson S et al.** A randomized clinical trial comparing intralesional bone marrow and steroid injections for simple bone cysts. *J Bone Joint Surg* 2008 ; 90-A : 722-730.
34. **Yandow SM, Lundeen GA.** Autogenic bone marrow injections as a treatment for simple bone cyst. *J Pediatr Orthop* 1998 ; 18 : 616-620.