



## Non-traumatic avulsion of the greater trochanter : A case report

Mohamed EL HACHMI, Damien DESMETTE, Jean-Paul FORTHOMME

*From the Centre Hospitalier Régional de Mons, Mons, Belgium*

**Apophyseal fracture affecting the greater trochanter is a rare injury in children. We report a case of non traumatic avulsion of the greater trochanter in a 13-year-old boy who presented with a history of pain about his right hip over the past few months. Hip radiographs, radioisotope bone scan and CT scan confirmed the diagnosis of avulsion of the greater trochanter with minimal displacement. The symptoms resolved after percutaneous *in situ* lag screw fixation. Radiographs 18 months after treatment showed fusion of the trochanteric physis.**

**Keywords :** greater trochanter avulsion ; children ; avascular necrosis ; non-traumatic.

### INTRODUCTION

Avulsion fracture of the greater trochanter is a rarity in children. When reported in literature, it is often caused by a traumatic event (7). We present a case of non traumatic origin which was treated surgically. Among the possible aetiologic factors, infection should be excluded and risk factors for slipped capital femoral epiphysis should be kept in mind. A regular follow-up is indicated to detect early signs of avascular necrosis of the femoral head.

### CASE REPORT

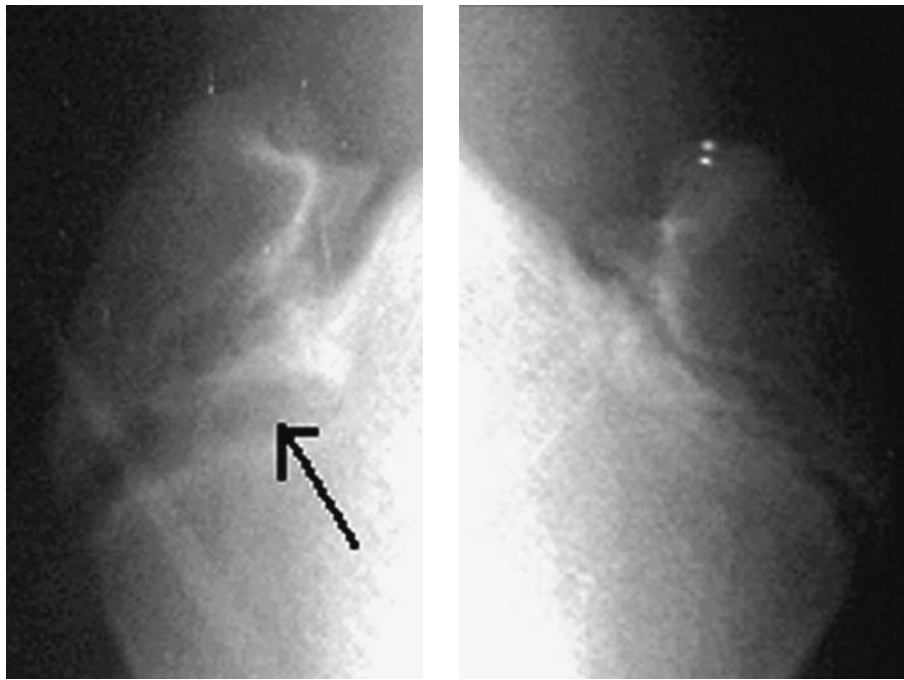
A 13-year-old boy presented with progressive right hip pain over the past few months, without any

trauma history. The pain was essentially mechanical. On examination, palpation of the greater trochanter was painful. The range of motion of the hip was limited by pain.

A plain radiograph showed partial separation of the greater trochanter (fig 1). A radioisotope bone scan showed an asymmetric hot spot in the area of the right greater trochanter (fig 2). CT-scan excluded associated hip lesions and confirmed the diagnosis of trochanteric avulsion fracture, which was a type I lesion with minimal displacement.

Despite a conservative treatment, well conducted during four weeks using a hip abduction brace, the pain did not resolve. Surgical treatment was therefore undertaken. The greater trochanter was approached by a lateral incision with fluoroscopy imaging, on the patient in prone position. Based on the CT-scan images, no reduction maneuver was needed. This enabled a percutaneous technique to

- 
- Mohamed El Hachmi, MD, Resident in Orthopaedic surgery.
  - Damien Desmette, MD, Orthopaedic surgeon.
  - Jean-Paul Forthomme, MD, Orthopaedic surgeon, Head of department.
- Centre Hospitalier Régional de Mons, Mons, Belgium.*  
Correspondence : Mohamed El Hachmi, 50, rue de la Poudrière, B-1000 Bruxelles, Belgium.  
E-mail : dr\_elhachmi@hotmail.com  
© 2010, Acta Orthopædica Belgica.
-



**Fig. 1.** — Plain AP radiographs showing the trochanteric region of both hips : avulsion fracture of the greater trochanter (arrow) on the right side

be used ; the apophysis was re-fixed with one AO 7.3 mm partially threaded lag screw, intended to achieve fusion of the physis. The reposition was assessed by fluoroscopy.

After surgery, the patient was mobilised with partial weight bearing. Pain relief was immediately achieved. Full weight bearing was allowed after six weeks, after radiographic check (fig 3). The patient made an uneventful recovery, and radiographs 18 months after surgery showed fusion of the trochanteric physis (fig 4).

### DISCUSSION

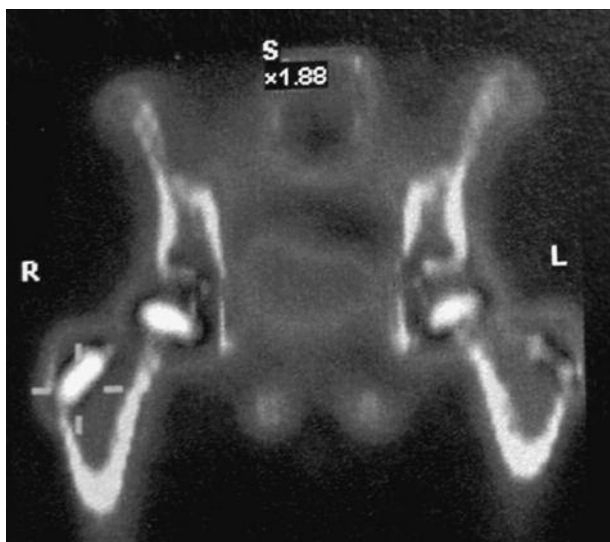
In the pelvis, the most common site of avulsion injuries is the ischial tuberosity (6,13).

The greater trochanter is the attachment site for the hip rotators, including the gluteus medius and minimus, obturator internus, gemelli and piriformis muscles. Avulsion of the greater trochanter generally occurs in association with a traumatic event (8).

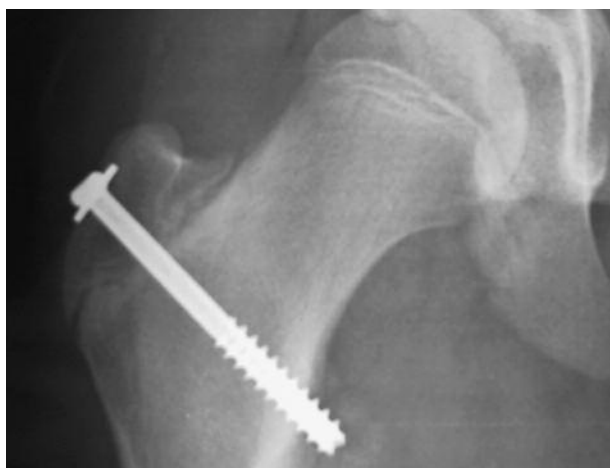In children, traumatic avulsion fractures of the greater trochanter are very rare ; they have been classified according to the mechanism causing the fracture (3,5). Chotel *et al* described three types of lesions. Type 1 lesions are avulsion fractures of the greater trochanter secondary to acute contraction of the gluteus muscles ; this type is rarely associated with femoral head necrosis. Type 2 avulsion fractures are associated with fracture of the femoral neck with a subsequent risk of femoral head necrosis. Type 3 combines hip dislocation with apophyseal avulsion ; according to the literature, there is an inevitable progression to femoral head necrosis (3).

To our knowledge, there is only one case reported in literature of a greater trochanter avulsion fracture of non-traumatic origin. Bloome reported one such case in a patient who presented risk factors for slipped capital femoral epiphysis (1).

Several papers recently published raised the possibility of a relation between fracture avulsion of the greater trochanter and slipped capital femoral



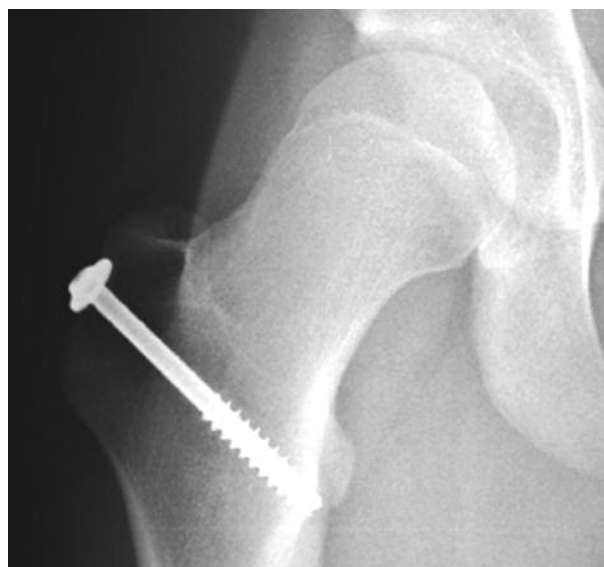**Fig. 2.** — Radioisotope bone scan showing asymmetric hyperfixation on the right greater trochanter.



**Fig. 3.** — Plain radiograph of the hip 6 weeks after surgery

epiphysis (1,2,5,7), in obese male teenagers. We cannot therefore exclude an inherent weakness in the growth plate of the greater trochanter, although our patient presented no risk factors for slipped capital femoral epiphysis.

It is important to differentiate a real avulsion fracture, which is very rare, from a widening of the physis of the greater trochanter which may be a radiological sign of osteomyelitis in children (9).



**Fig. 4.** — Radiograph 18 months after refixation of the greater trochanter shows fusion of the trochanteric physis.

Excluding a traumatic event, a slipped capital femoral epiphysis and an infection, we could not find a specific aetiology causing this injury in our patient. Whatever the aetiology, the prognosis is reserved because of the risk of avascular necrosis of the femoral head due to the proximity of the blood supply to both anatomic sites (11,12), well described by Trueta (10). In their attempt to classify the lesions, Chotel *et al* reported two cases which led to femoral head necrosis (2). Other authors reported cases of osteonecrosis after trochanteric avulsion in children, confirming the guarded prognosis of these lesions (5,7). None of these reports could relate the necrosis to the trauma or to the surgical manipulation.

There is no published data about conservative treatment for avulsion of the greater trochanter. The surgical treatment, preferred by all authors, consists in reduction of the avulsion (12). Considering the risk of iatrogenic avascular necrosis, we preferred to treat this lesion with careful minimal open reduction to avoid further devascularisation of the immature proximal femur.

## REFERENCES

1. **Bloome DM, Thompson JD.** Apophyseal fracture of the greater trochanter. *South Med J* 2000 ; 93 : 832-823.
2. **Ceroni D, De Coulon G, De Rosa V, Kaelin A.** Apophyseal avulsion fracture of the greater trochanter after slipped capital femoral epiphysis : a case report. *Acta Orthop Belg* 2004 ; 70 : 619-622.
3. **Chotel F, Durand JM, Sales de Gauzy J et al.** [Avulsion fractures of the greater trochanter in children : two cases, review of the literature and proposition for a classification.] (in French). *Rev Chir Orthop Réparat Appar Mot* 2004 ; 90 : 274-279.
4. **Kaweblum M, Lehman WB, Grant AD, Strongwater A.** Avascular necrosis of the femoral head as sequela of fracture of the greater trochanter. A case report and review of the literature. *Clin Orthop Relat Res* 1993 ; 294 : 193-195.
5. **Mbubaegbu CE, O'Doherty D, Shenolikar A.** Traumatic apophyseal avulsion of the greater trochanter : case report and review of the literature. *Injury* 1998 ; 29 : 647-649.
6. **McMaster PE.** Tendon and muscle ruptures. *J Bone Joint Surg* 1993 ; 15-A : 702-722.
7. **O'Rourke MR, Weinstein SL.** Osteonecrosis following isolated avulsion fracture of the greater trochanter in children. A report of two cases. *J Bone Joint Surg* 2003 ; 85-A : 2000-2005.
8. **Rockwood CA, Green DP, Bucholz RW.** *Fractures in Adults*. 3rd ed. Lippincott, Philadelphia, 1991, pp 1560-1562.
9. **Studler U, Ledermann HP, Furlano RI et al.** Widening of the greater trochanteric physis in the immature skeleton : a radiographic sign of femoral osteomyelitis. *Europ Radiology* 2003 ; 13 : 2238-2240.
10. **Trueta J, Harrison MHM.** The normal vascular anatomy of the femoral head in adult man. *J Bone Joint Surg* 1953 ; 35-B : 442-461.
11. **Wenger D.** The guarded prognosis for greater trochanter fractures in adolescence. *J Bone Joint Surg* 2003 ; 85-B, Suppl. III, 259.
12. **Wood JJ, Rajput R, Ward AJ.** Avulsion fracture of the greater trochanter of the femur : recommendations for closed reduction of the apophyseal injury *Injury Extra* 2005 ; 36 : 255-258.
13. **Wootton JR, Cross MJ, Holt KWG.** Avulsion of the ischial apophysis. *J Bone Joint Surg* 1990 ; 72-B : 625-627.