

## Delayed migration of a metal suture anchor into the glenohumeral joint

Sofie GOEMINNE, Philippe DEBEER

*From the University Hospital Pellenberg, Leuven, Belgium*

**Intra-articular migration is a known complication of poorly placed metallic suture anchors in rotator cuff repair and labral reconstruction.**

**We report a case of intra-articular migration of a metallic suture anchor seven years after open labral reconstruction. Despite the fact that the patient remained asymptomatic for seven years, presence of an extra-osseous anchor was already noted postoperatively.**

**In an era where the use of suture anchors has become common practice, surgeons should always be aware of possible anchor migration, especially when patients complain of sudden sharp pain, persistent pain, a catching sensation and loss of mobility.**

**Keywords :** suture anchor ; migration ; metallic ; complications ; shoulder.

### INTRODUCTION

Metal suture anchors are frequently used in shoulder stabilisation procedures. Despite their advantages, complications can occur. We report a case of intra-articular migration of a metal suture anchor, causing significant cartilage damage.

### CASE REPORT

A 29-year-old male was seen in our clinic after a sudden onset of left shoulder pain when waking up two months earlier. He reported no history of

trauma. Seven years before, an antero-inferior labral lesion was repaired with an open labral reconstruction and capsular plication in another institution. The recovery after this procedure was uneventful and the patient was able to resume his normal professional and sporting activities.

On examination passive mobilisation of the shoulder was very painful. Active abduction was 140°, anterior elevation 150°, external rotation 45° and internal rotation was possible till the level of L3. Crepitus was noted in abduction, forward elevation and rotation. Impingement tests were positive and there was diminished strength in the rotator cuff muscles. There was no evidence of instability. The acromioclavicular joint was not tender on palpation. There was no atrophy of the musculature around the shoulder and no neurological deficit was noted.

Plain radiographs of the shoulder demonstrated the presence of three metallic suture anchors on the

- 
- Sofie Goeminne, Medical Student.
  - Philippe Debeer, MD, PhD, Professor, Orthopaedic Surgeon.

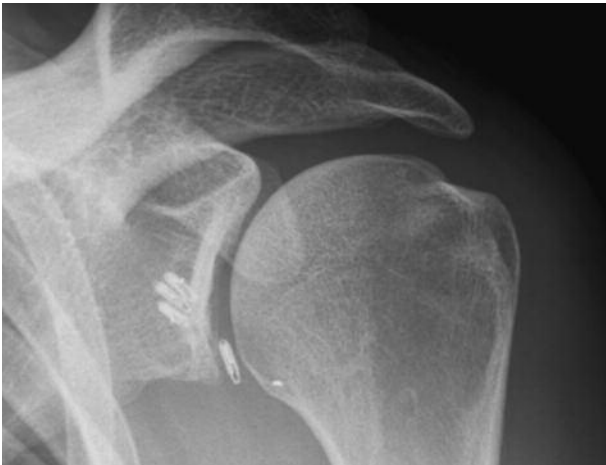*Division of Orthopaedics, Department of Musculoskeletal Science, University Hospital Pellenberg, Leuven, Belgium.*

Correspondence : Philippe Debeer, Division of Orthopaedics, Department of Musculoskeletal Science, University Hospital Pellenberg, Weligerveld 1, B-3212 Pellenberg, Belgium.

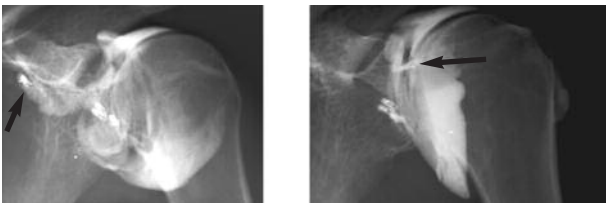
E-mail : philippe.debeer@uzleuven.be

© 2010, Acta Orthopædica Belgica.

---



**Fig. 1.** — Antero-posterior radiograph of the left shoulder demonstrating one extra-osseous metal suture anchor.

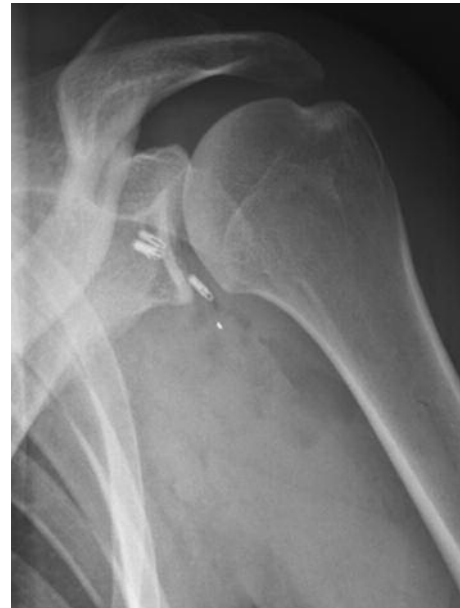

**Fig. 2.** — Arthrography of the left shoulder (prior to arthro-MRI scan) showing migration of the extra-osseous anchor (arrow) into the glenohumeral joint.

glenoid rim. A fourth metallic anchor was visible in the glenohumeral joint and was clearly in an extra-osseous position (fig 1). Arthro-MRI revealed an intact rotator cuff and multiple artefacts caused by the presence of the metallic suture anchors. On the arthrography however, migration of the extra-osseous anchor was seen towards the subscapular recess (fig 2).

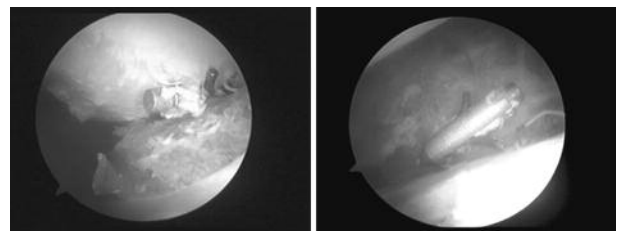
We were able to obtain a radiograph of the left shoulder taken two days after the open stabilization procedure (fig 3). On this radiograph the presence of the extra-osseous anchor at that stage was already noted. The presence of this loose metal anchor and the possibility of cartilage damage prompted us to perform an arthroscopy of the left shoulder to remove this loose anchor.

The arthroscopy was performed under general anaesthesia, with the patient in the lateral decubitus



**Fig. 3.** — Antero-posterior radiograph of the left shoulder taken two days after the index surgery in 2002. One metal suture anchor is not within the glenoid bone.

position. Examination under anaesthesia showed a normal range of motion and no evidence of recurrent instability. During the arthroscopy, the metal anchor was immediately seen in the axillary recess. There was cartilage damage on the glenoid surface and on the humeral head (fig 4). The labrum had healed to the anterior glenoid neck and the rotator cuff was intact. The surrounding capsule was fibrillated and the synovium was inflamed. The anchor could be removed without any problems and a debridement of the cartilage lesions and the synovitis was performed. Examination of the subacromial space was normal.



**Fig. 4.** — The metal suture anchor is loose in the glenohumeral joint. Synovitis and cartilage damage on humeral and glenoid is visible

Immediate postoperative mobilisation was started. At 6 months follow-up the patient was pain free and had a normal range of motion with good strength in the rotator cuff muscles. Further follow-up is required to determine whether the cartilage lesions will become symptomatic.

## DISCUSSION

The introduction of suture anchors in shoulder surgery has greatly facilitated open and arthroscopic rotator cuff repairs and labral reconstructions. Despite the great advantages of these anchors, complications have been described by several authors (4,5,6,9,10,11). The major problem seems to be malpositioning of the anchor, resulting in persistent pain, cartilage damage, and failure of the repair. In labral repairs the ideal position of the anchor is slightly over the glenoid rim under an angle of 45°. When the anchor is positioned in osteoporotic bone, tunnel failure with loosening and subsequent migration of the hardware can occur. Malpositioning of the anchor too lateral to the glenoid rim will also result in suboptimal grip of the anchor into the glenoid bone or even in an extra-osseous positioning. Failure to diagnose a loose or malpositioned metal anchor in the glenohumeral joint can have catastrophic consequences. Rhee *et al* (10) presented five cases of iatrogenic glenohumeral arthropathy after arthroscopic labral reconstruction using metal anchors. In all cases the malpositioned anchors caused chondral lesions on the humeral head. Rhee *et al* (9) reported a patient with recurrent glenohumeral instability combined with anchor-induced arthropathy. Jeong *et al* (4) presented six patients with an anchor protruding on the glenoid surface. Before metal suture anchors were available, Matthews *et al* (7) reported a series of arthroscopic capsular repairs using staples and detected in 1 of 25 shoulders severe cartilage damage on the humeral head. Similarly, Ekelund *et al* (3) described 4 cases of important articular damage caused by loose metallic fixation material.

In the present case the malpositioning of the anchor was already present at the index surgery as shown on the immediate postoperative radiographs. The patient, however, remained asymptomatic for

the seven following years. The fact that the extra-osseous anchor did not cause immediate problems is not unusual (5). Migration of the anchor, however, can always occur and therefore serial radiological follow-up seems to be indicated.

Because of the possible complications with metal suture anchors, bio-absorbable implants have been developed. These absorbable suture anchors offer similar pullout strength as metal suture anchors, they produce a minimal artefact signal on MRI scan and they are eventually resorbed and replaced by bone. Despite these advantages, complications with the use of bio-absorbable suture anchors have been described as well. Clavert *et al* (2) found synovitis and a foreign-body reaction possibly related to the suture in 1 of 116 collected cases. Three cases of anchor hole enlargement detected by MRI 3 months after arthroscopic Bankart repair with absorbable suture anchors were reported by Takubo *et al* (12). Boden *et al* (1) reported 3 cases of chondrolysis after an arthroscopic SLAP lesion repair with bio-knotless anchors. In 2 of these 3 cases, reactive synovitis was noted. Nho *et al* (8) collected in a review article, several case series and case reports about complications with bio-absorbable suture anchors. Complications included failure of the anchor itself, osteolysis and arthropathy, loose bodies and reactive synovitis. Clinically, these patients may present with complaints of pain, progressive stiffness and a grinding sensation.

It thus appears that when a patient complains of persistent pain, sudden sharp pain, a catching sensation and loss of mobility after a shoulder stabilization procedure, special attention is warranted. In these cases a standard radiograph of the shoulder after use of metal anchors or an MRI scan after use of bio-absorbable anchors is necessary to investigate these complaints. Even after a symptom-free period, an extra-osseous anchor can cause problems.

## REFERENCES

1. Boden RA, Burgess E, Enion D, Srinivasan MS. Use of bioabsorbable bioknotless suture anchors and associated accelerated shoulder arthropathy. *Am J Sports Med* 2009 ; 37 : 1429-1433.

2. **Clavert P, Warner JP.** Panacryl synovitis : fact or fiction? *Arthroscopy* 2005 ; 21 : 200-203.
3. **Ekelund A.** Cartilage injuries in the shoulder joint caused by migration of suture anchors or mini screw. *J Shoulder Elbow Surg* 1998 ; 7 : 537-539.
4. **Jeong JH, Shin SJ.** Arthroscopic removal of proud metallic suture anchors after Bankart repair. *Arch Orthop Trauma Surg* 2009 ; 129 : 1109-1115.
5. **Kaar TK, Schenck RC Jr, Wirth MA, Rockwood CA Jr.** Complications of metallic suture anchors in shoulder surgery : A report of 8 cases. *Arthroscopy* 2001 ; 17 : 31-37.
6. **Lorbach O, Wimes P, Brogard P, Seil R.** [Complications related to implants in arthroscopic shoulder surgery.] (in German). *Orthopäde* 2008 ; 37 : 1073-1079.
7. **Matthews LS, Vetter WL, Oweida SJ, Spearman J, Helfet DL.** Arthroscopic staple capsulorrhaphy for recurrent anterior shoulder instability. *Arthroscopy* 1988 ; 4 : 106-111.
8. **Nho JS, Provencher MT, Seroyer ST, Romeo AA.** Bioabsorbable anchors in glenohumeral shoulder surgery. *Arthroscopy* 2009 ; 25 : 788-793.
9. **Rhee KJ, Kim KC, Shin HD, Kim YM.** Revision using modified transglenoid reconstruction in recurred glenohumeral instability combined with anchor-induced arthropathy. *Knee Surg Sports Traumatol Arthrosc* 2007 ; 15 : 1494-1498.
10. **Rhee YG, Lee DH, Chun IH, Bae SC.** Glenohumeral arthropathy after arthroscopic anterior shoulder stabilization. *Arthroscopy* 2004 ; 20 : 402-406.
11. **Silver MD, Daigneault JP.** Symptomatic interarticular migration of glenoid suture anchors. *Arthroscopy* 2000 ; 16 : 102-105.
12. **Takubo Y, Morihara T, Namura T et al.** Anchor hole enlargement after arthroscopic Bankart repair using absorbable suture anchors : a report of three cases. *J Shoulder Elbow Surg* 2008 ; 17 : 16-18.