



Radical cure of vertebral hydatidosis. A case report

Slaheddine KARRAY, Maher KARRAY, Mongi ZLITNI, Mongi DOUIK

The authors present a rare case of univertebral hydatidosis, and report encouraging results 12 years after radical resection of the involved vertebra. They stress the importance of computed tomography and especially magnetic resonance for monitoring early recurrence. A two-staged anterior and posterior approach, although difficult, seems to offer a very good prognosis in case of univertebral localisation.

CASE REPORT

A 50-year-old woman of rural origin was seen for low back pain and right cruralgia which had been evolving over one year. There was local tenderness in the lumbar area. Neurological examination was normal. Plain radiographs showed a radiolucent area in the body of L2, and a hazy appearance of the pedicles (fig 1). The CT scan confirmed destruction of the body and posterior arch of L2 with presence of paravertebral and intraspinal soft tissue masses (fig 2). Hydatid serology (ELISA) was positive and the diagnosis of vertebral hydatidosis was then strongly suspected. Exploration via a posterior approach revealed a paravertebral hydatid abscess, filled with hydatid cysts, destroying the posterior arch of L2. The posterior arch was completely resected; two screwed plates and posterolateral bone grafts were used for stabilisation. One month later, corporectomy of L2 was performed; three peroneal stut grafts were inserted. The lumbar pain and the cruralgia regressed. Six months later the patient went back to her regular rural activities. Seven years later she complained of some discomfort, probably related to the hardware. Radiographical examination showed bony union

and absence of recurrence (fig 3). It was decided to remove the two plates. At surgery bony union and absence of recurrence were confirmed; histopathological examination was negative. Ten years after the first operation plain radiographs, CT scan and magnetic resonance showed bony union anteriorly and posteriorly, without signs of recurrence. A further CT scan 12 years after the first operation was also negative.

DISCUSSION

The *Echinococcus* worm inhabits the small intestine of the dog. Dogs' excreta infect cattle and man orally (15). The skeleton is affected in only one or two percent of the cases, and half of these concern the spine (15). Vertebral hydatidosis is a silent, slowly progressive disease, and pain is an important presenting symptom. Neurological disorders occur after a latent period of several years (3, 10).

From the Kassab Institute of Orthopaedic Surgery, Manouba, Tunisia and the Charles Nicolle Hospital, Tunis, Tunisia.

Slaheddine Karray, Professor.

Mongi Douik, Professor and Chairman.

Kassab Institute of Orthopaedic Surgery, Ksar Said, Manouba, Tunisia.

Maher Karray, Associate Professor.

Mongi Zlitni, Professor and Chairman.

Department of Orthopaedic Surgery, Charles Nicolle Hospital, Tunis, Tunisia.

Correspondence : Maher Karray, Service d'Orthopédie et de Traumatologie, Hôpital Charles Nicolle, Boulevard 9 Avril, 1006 Tunis, Tunisie. E-mail : karray_maher@yahoo.fr.

© 2004, Acta Orthopædica Belgica.

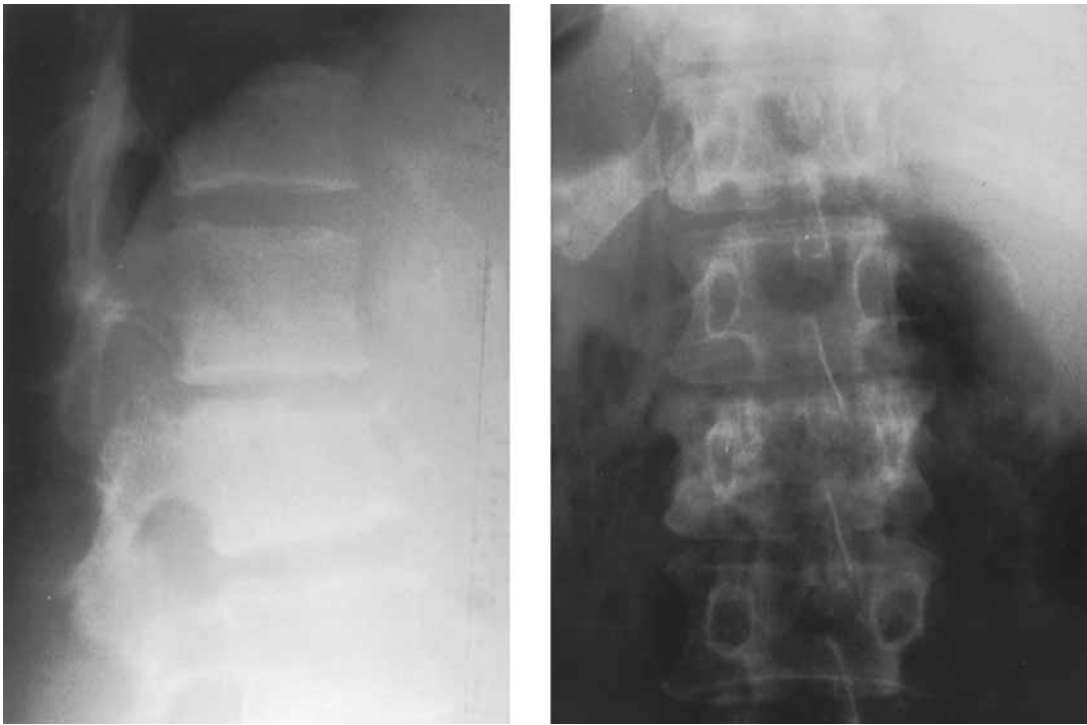


Fig. 1. — Lateral and AP radiographs showing an osteolytic lesion of the body of L2 with a hazy appearance of both pedicles. Involvement of the superior end plate of L2, and narrowing of the L1-L2 disc space.

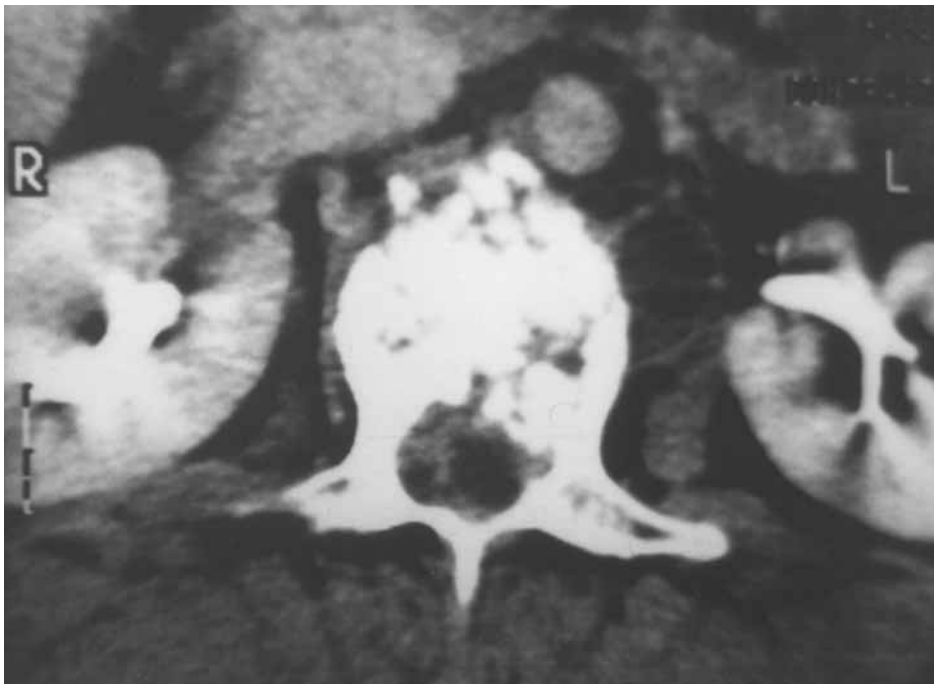


Fig. 2. — Axial CT scan showing rupture of the anterior cortex of L2, with moth-eaten aspect of the body of L2. Soft tissue masses can be seen within the spinal canal and in the right prevertebral area.

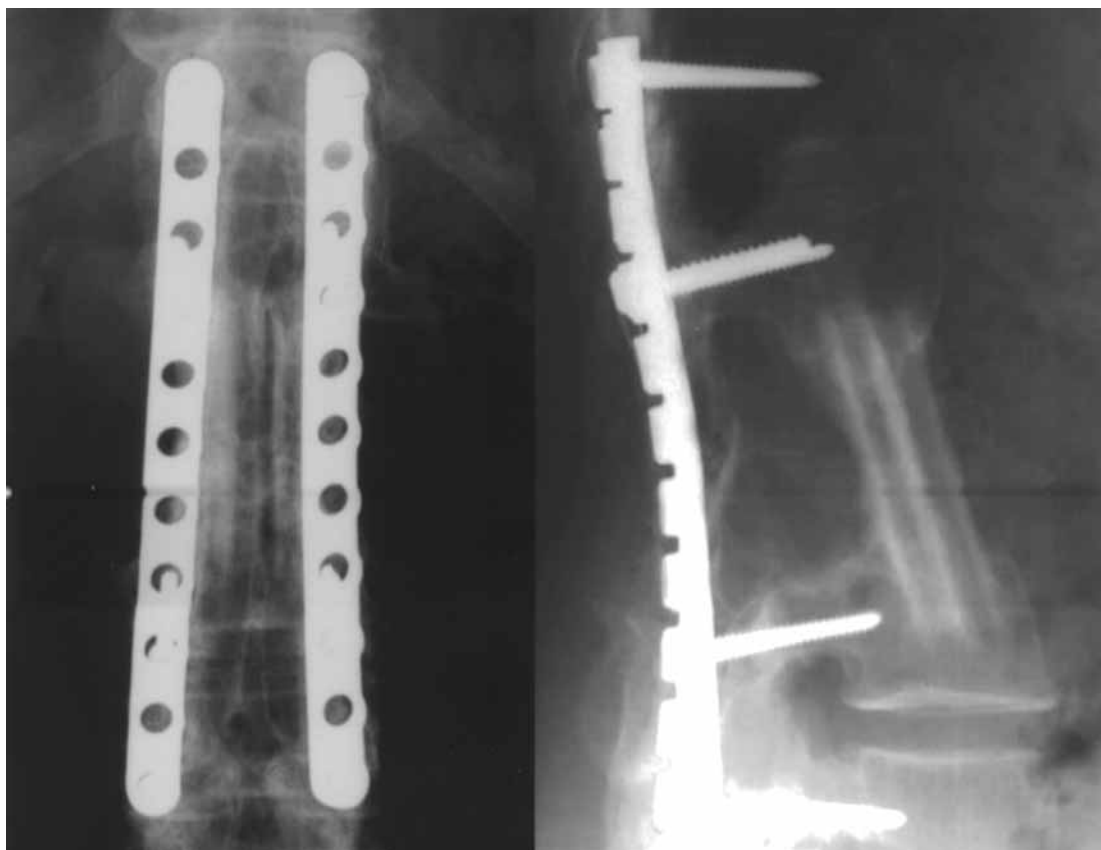


Fig. 3. — Radiographs taken seven years after surgery showing instrumentation and union of bone grafts without signs of recurrence.

When the diagnosis of vertebral hydatidosis is finally established, the lesions have already reached an advanced stage with bipolar and multi-level involvement. In these circumstances resection is incomplete and prognosis is poor, being characterised by recurrences and neurological complications (1, 2, 13, 14). In fact, Dévé (3) does not believe in healing of spinal hydatidosis and regards this disease as a “white cancer” with local malignancy.

In an earlier study including 13 cases of vertebral hydatidosis (6) we noted a significant extension of the remission period after a combined anterior and posterior approach, an assumption which was confirmed by the present case. Govender *et al* (5) came to similar findings. Moreover, a univertebral localisation allows radical excision of the lesions (7), so that definitive cure might become possible.

Magnetic resonance imaging facilitates early diagnosis and later follow-up (4, 8, 9, 11, 12). Early

diagnosis often means univertebral involvement, which permits radical surgery.

REFERENCES

1. Acquaviva R, Tamic PM. L'échinococcose vertébro-médullaire : à propos de 14 observations. *Neurochirurgie* 1964 ; 6 : 649-650.
2. Carta F, Perria C, Davini V. Vertebral echinococcosis. *J Neurosurg Sci* 1974 ; 18 : 228-232.
3. Dévé F. *L'Échinococcose Osseuse*. Masson, Paris, 1948, p 236.
4. Diedrich O, Craft CN, Zhou H *et al*. Orthopedic aspects of osseous echinococcosis-radiologic diagnosis, current surgery and drug therapy aspects. *Z Orthop Ihre Grenzgeb* 2001 ; 139 : 261-266.
5. Govender TS, Aslam M, Parbhoo A, Corr P. Hydatid disease of the spine. A long-term follow-up after surgical treatment. *Clin Orthop* 2000 ; 378 : 143-147.
6. Karray S, Zlitni M, Fowles JV *et al*. Vertebral hydatidosis and paraplegia. *J Bone Joint Surg* 1990 ; 72-B : 84-88.

7. **Louis R, Casanova J, Baffert M.** Techniques chirurgicales des tumeurs du rachis. *Rev Chir Orthop* 1976 ; 62 : 57-70.
8. **Merkle EM, Schulte M, Vogel J et al.** Musculoskeletal involvement in cystic echinococcosis : report of eight cases and review of the literature. *Am J Roentgenol* 1997 ; 168 : 1531-1534.
9. **Mikhael MA, Ciric IS, Tarkington JA.** MR imaging in spinal echinococcosis. *J Comput Assist Tomogr* 1985 ; 9 : 398-400.
10. **Mills TJ.** Paraplegia due to hydatid disease. *J Bone Joint Surg* 1956 ; 38 B : 884-891.
11. **Norman D, Mills CM, Brant-Zawadzki M et al.** Magnetic resonance imaging of the spinal cord and canal : potentials and limitations. *AJR* 1983 ; 141 : 1147-1152.
12. **Pandey M, Chaudhari MP.** Primary hydatid cyst of sacral spinal canal : case report. *Neurosurgery* 1997 ; 40 : 407-409.
13. **Turtas S, Viale ES, Pau A.** Long-term results of surgery for hydatid disease of the spine. *Surg Neurol* 1980 ; 13 : 468-470.
14. **Unger HS, Schneider LH, Sher J.** Paraplegia secondary to hydatid disease. *J Bone Joint Surg* 1963 ; 45-A : 1479-1484.
15. **Zlitni M, Kooli M, Ezzaouia K, Lebib H, Mestiri M.** Manifestations osseuses des parasitoses. *Encycl Méd Chir, Appareil locomoteur, Elsevier, Paris, 1996, p 14021.*