



Venous thromboembolism in shoulder surgery : A systematic review

Nwakile I. OJIKE, Arup K. BHADRA, Peter V. GIANNOUDIS, Craig S. ROBERTS

From the University of Louisville, KY, USA

Although it is generally believed that venous thromboembolism (VTE) after shoulder surgery is very rare, there are increasing reports of deep venous thrombosis (DVT) and pulmonary embolism (PE) associated with shoulder surgery. To our knowledge only few studies have reviewed the available evidence on the subject. The purpose of this study was to review the available evidence in the published literature regarding incidence, risk factors, diagnosis and management of DVT/PE following shoulder surgery (Level IV evidence).

Keywords : venous thromboembolism ; deep vein thrombosis ; shoulder surgery.

INTRODUCTION

In this Institutional Review Board-exempt study, we found a total of eight articles which fulfilled all criteria of our search (4,10,15,20,29,31,33,37). We identified a deep venous thrombosis (DVT) incidence rate of 0.02%-13% confirming the existence of variable rates across different hospital settings. Nonetheless, the incidence of DVT after shoulder arthroscopy was found to be 0.08%. There is the need for further prospective studies evaluating the prevalence and management of DVT/PE following shoulder surgery. The purpose of our study was to review the available evidence in the published literature regarding incidence, risk factors, diagnosis and management of VTE after shoulder surgery.

The eight published studies [seven level II (4,10,15,20,29,33,37) and one level IV (31)] indicate a variable, low incidence of VTE after shoulder surgery.

METHODS

This was an Institutional Review Board-exempt study performed at a level I trauma centre. A search of the PubMed database was made using the search terms venous thrombosis and shoulder yielding 108 hits. Also a search of the OVID Medline database was made using the medical subject headings (MeSH) “venous thrombosis and shoulder” yielding 64 hits. The search was dated October 1, 2010. Both searches were coalesced to remove 64 duplicate articles (Fig. 1). All articles were cross-referenced and screened for relevance to the study. Cross-referencing yielded an additional fourteen articles.

-
- Nwakile I. Ojike, MD, Research Fellow.
 - Arup K. Bhadra, MD, Orthopaedic Fellow.
 - Craig S. Roberts, MD, MBA, Professor of Orthopaedic Surgery ; Orthopaedic Surgery Residency Program Director.
Department of Orthopaedic Surgery, University of Louisville, Louisville, KY, USA.
 - Peter V. Giannoudis, MD, Professor of Trauma and Orthopaedic Surgery.
Department of Orthopaedic Surgery, University of Leeds, Leeds, United Kingdom.
- Correspondence : Craig S. Roberts, MD, MBA, 210 E. Gray Street, Suite 1003, Louisville, KY 40202, USA.
E-mail : craig.roberts@louisville.edu
© 2011, Acta Orthopædica Belgica.
-




Fig. 1. — Algorithm showing search methods

Articles to be selected were case series reporting two or more cases of upper extremity or lower extremity DVT following shoulder surgery (including shoulder arthroplasty and arthroscopy) in the English literature. Full text copies of all relevant articles were obtained and assessed for eligibility. Single case reports, deep venous thromboses from primary malignancies, exercise-induced DVT and other non-surgical causes of DVT were excluded. There were seven level II studies (4,10,15,20,29,33,37) and one level IV study (31). All papers selected were analysed for incidence of DVT and pulmonary embolism (PE), risk factors, method of diagnosis, and DVT/PE management (prophylaxis/management).

RESULTS

A total of eight articles fulfilled all criteria of our search (4,10,15,20,29,31,33,37).

Incidence

The total number of shoulder surgery cases reviewed for DVT/PE was 40,537 (7,314 total shoulder arthroplasties ; 9,432 hemiarthroplasties ; and 23,791 shoulder arthroscopies). From the six articles reporting the average age of patient, the average of the mean age of the patients was 40.2 years (range, 18-88 years). All eight articles (4, 10,15,20,29,31,33,37) reported incidence of DVT following shoulder surgery (Table I). The incidence of DVT after shoulder surgery was 0.24%, and incidence of PE was 0.11% with an overall incidence of VTE after shoulder surgery as 0.35%. The location of the thrombosis was not well-described in the studies as only 26 of the 98 cases of DVT after shoulder surgery described the location of the clot as either lower extremity DVT or upper extremity DVT (Table II). The location was nearly equally split with 42% of the cases involving lower extremity DVT (Table II). Four articles described gender of patients experiencing DVT/PE, six out of a possible twelve patients (50%) were female (4,10,31, 33).

Risk Factors

Kuremsky *et al* (15) reported the presence of significant risk factors in 50% of patients developing DVT/PE after shoulder arthroscopy. A previous history of DVT/PE event was found in 7% of cases reporting incidence of risk factors. The most occurring risk factors were history of heart disease, age > 70 years, obesity and history of recent major surgery (Table III).

Methods of Diagnosis

Seven articles described methods of diagnosing DVT or PE (Table IV). Doppler ultrasound was the most widely used tool for extremity DVT diagnosis, whilst chest CT was more widely used for PE diagnosis (72%). One patient had a post-mortem diagnosis of PE (31) whilst another case fatality had respiratory symptoms classic for PE (37).

Of the 32 recorded cases of Doppler ultrasound screening for symptoms suspicious of DVT/PE, four (4) were negative for blood clots.

Table I. — Incidence of DVT following shoulder surgery

Author	Procedure	DVT	PE
Sperling JW <i>et al</i> 2002	TSA 2,308	-	1
	SHA 577	-	4
	SA -	-	-
Rockwood CA Jr <i>et al</i> 2003	TSA 2	1	2
	SHA -	-	-
	SA -	-	-
Lyman S <i>et al</i> 2006	TSA 4,931	20	13
	SHA 8,828	49	19
	SA -	-	-
Kuremsky M <i>et al</i> 2008	TSA -	-	-
	SHA -	-	-
	SA 2,872	5	2
Bongiovanni SL <i>et al</i> 2009	TSA -	-	-
	SHA -	-	-
	SA 1,082	3	-
Willis AA <i>et al</i> 2009	TSA 73	13	3
	SHA 27	-	-
	SA -	-	-
Garofalo R <i>et al</i> 2010	TSA -	-	-
	SHA -	-	-
	SA 10,452	2	1
Randelli P <i>et al</i> 2010	TSA -	-	-
	SHA -	-	-
	SA 9,385	5	1
Total	40,537	98 (0.24%)	46 (0.11%)
	TSA/SHA 16,746	83	42
	SA 23,791	15	4

TSA- Total Shoulder Arthroplasty ; SHA- Shoulder Hemi-Arthroplasty ; SA- Shoulder Arthroscopic Surgery.

Timing of the screening Doppler ultrasonography for high risk patients ranged from the first post-operative day to twelve weeks after surgery.

Treatment

Six of the eight articles reported on the treatment modality employed (Table V). The various types of modalities employed included enteric-coated aspirin, pneumatic compression pumps, throm-

boembolic deterrent stockings (TEDS), early ambulation and pharmacologic agents (31,37).

Eighteen patients had definitive treatment for PE using anticoagulants : coumadin alone seven cases (39%), low molecular weight heparin with or without coumadin in six cases (33%), IVC filters with anticoagulation in one case (6%), and unspecific pharmacologic anti-coagulation in four cases (22%) (15,33). Two thousand nine hundred and seventy-four cases had DVT thromboprophylaxis

Table II. — Relative incidence of upper extremity and lower extremity DVT

AUTHOR	Upper Extremity DVT	Lower Extremity DVT
Rockwood <i>et al</i> 2003	unspecified	1
Kuremsky <i>et al</i> 2008	5	2
Bongiovanni <i>et al</i> 2009	2	1
Willis <i>et al</i> 2009	6	7
Garofalo R <i>et al</i> 2010	2	-
TOTAL	15 (58%)	11 (42%)

Table III. — Risk factors for VTE

Risk Factor	Author						Total
	Sperling JW <i>et al</i> 2002	Rockwood CA jr <i>et al</i> 2003	Lyman S <i>et al</i> 2006	Kuremsky M <i>et al</i> 2008	Bongiovanni SL <i>et al</i> 2009	Willis AA <i>et al</i> 2009	
Smoking	-	-	-	5	-	-	5 (2%)
Haemostatic disorder	1	-	-	2	3	1	7 (3%)
Cardiovascular disease (CVA, CAD, hypertension)	3	-	-	-	-	73	76 (33%)
Previous history of DVT/PE	-	-	-	-	-	17	17 (7%)
History of recent major surgery	1	-	-	-	-	29	30 (13%)
Age > 70 years	3	1	-	-	-	56	60 (25%)
Obesity	-	1	-	-	-	40	41 (17%)
Total	8	2	-	7	-	216	2,336 (100%)

using anti-embolic stockings and pneumatic compression devices alone.

DISCUSSION

We identified a DVT incidence rate of 0.02% - 13% confirming the existence of variable rates across different hospital settings. Nonetheless, the incidence of DVT after shoulder arthroscopy was found to be 0.08%. This low frequency is approximately ten times lesser when compared to the rate of DVT after shoulder arthroplasty (0.7%). It is also significantly lower and not comparable to incidence rates after total hip arthroplasty or total knee arthroplasty (9,18,20,35).

One major risk factor for VTE is ethnicity, with a significantly higher incidence among Caucasians and African Americans than among Hispanic persons and Asian-Pacific Islanders (36). Deleterious

effects of sickling erythrocytes on coagulation in patients with sickle cell trait has been identified as risk factor and is responsible for 7% of all VTE in the African-American population (1).

Shoulder surgery following trauma and history of malignancy increased the risk of DVT. Also, overall mortality may be higher for shoulder surgery following trauma (20). Patients undergoing shoulder hemi-arthroplasty may be at a higher risk of DVT compared to patients undergoing total shoulder arthroplasty. Shoulder surgery patients with concomitant head injury may be at higher risk due to increased incidence of DVT among injured patients with traumatic brain injury compared with those without head injury, independent of anticoagulation (14,20).

Length of surgery, axillary vein manipulation with associated intimal injury, intramedullary instrumentation, and use of bone cement increase

Table IV. — Methods of diagnosis of DVT or PE

Author	Number of Cases Reporting DVT Diagnostic Tool	Method of DVT Diagnosis		Number of Cases Reporting PE Diagnosis	Method of PE Diagnosis			
		Upper/ Lower Extremity Doppler	Upper/ Lower Extremity Doppler		Ventilation/ Perfusion Scan	CT Scan	Autopsy	Clinical Diagnosis
Sperling JW <i>et al</i> 2002	4	4	4	5	1	4	-	-
Rockwood jr CA <i>et al</i> 2003	-	-	-	2	1	-	1	-
Lyman S <i>et al</i> 2006	-	-	-	-	-	-	-	-
Kuremsky M <i>et al</i> 2008	5	5	5	2	-	2	-	-
Bongiovanni SL <i>et al</i> 2009	3	3	3	-	-	-	-	-
Willis AA <i>et al</i> 2009	13	13	13	3	-	2	-	1
Garofalo R <i>et al</i> 2010	5	5	5	1	-	1	-	-
Randelli P <i>et al</i> 2010	2	2	2	1	-	1	-	-
Total	32 (100%)	32 (100%)	32 (100%)	14 (100%)	2 (14%)	10 (72%)	1 (7%)	1 (7%)

Table V. — Treatment of DVT or PE

Author	Prophylactic Treatment			Definitive Treatment					
	No of Cases Reported	TEDS + Pneumatic compression device	TEDS + Pneumatic compression device + Post-Op Aspirin	Pharmacologic Prophylaxis	No of Cases Reported	Coumadin	LMW ± Coumadin	LMWH + Coumadin + IVC Filter	Unspecified
Sperling <i>et al</i> 2002	-	-	-	-	5	-	4	1	-
Rockwood <i>et al</i> 2003	2	2	-	-	-	-	-	-	-
Lyman <i>et al</i> 2006	-	-	-	-	-	-	-	-	-
Kuremsky <i>et al</i> 2008	2,872	2,872	-	-	7	7	-	-	-
Willis A <i>et al</i> 2009	100	100	75	-	-	-	-	-	-
Garofalo R <i>et al</i> 2010	-	-	-	-	2	-	2	-	-
Randelli P <i>et al</i> 2010	2	-	-	2	4	-	-	-	4
Total	2,976	2,974 (99.9%)	75 (3%)	2 (0.07%)	18 (100%)	7 (39%)	6 (33%)	1 (6%)	4 (22%)

physiological stress, affecting the coagulation and fibrinolytic systems (22,25,26,34). Beach chair positioning of patients for shoulder arthroplasty leads to increased lower extremity venostasis, increasing the risk of DVT.

A previous history of DVT/PE and a history of clotting disorder (including a family history) are equally threatening. Significant activation of coagulation has been demonstrated after air travel, indicating an additional mechanism to immobilisation as a factor in VTE (32).

Clinical diagnosis of DVT/PE can be misleading (12). Serious concerns exist about risks of misinterpretation of early symptoms suggesting that the incidence of DVT/PE after shoulder surgery is underestimated (33). Also, the lack of evidence on the usefulness of routine perioperative anti-coagulation for shoulder surgery prevents its widespread adoption by physicians. Vague post-operative respiratory symptoms, with or without non-invasive evidence of lower extremity or upper extremity blood clot, need to be explored further for PE. Clinical factors highly predictive of risks of fatal PE include advanced age (> 75 years), cancer, immobilisation for concomitant neurological disease, and DVT with PE at initial presentation (16). Common perioperative routines including traction, immobilisation of the upper limb in a sling, and surgical positioning, in addition to one or more known risk factors may confer additional risk of a thrombotic event, or allow a silent post-operative clot to propagate (10,11). In patients with multiple positive risk factors, and a potentially increased risk of DVT, there is limited information in the literature concerning the use of pharmacologic anti-coagulants prophylactically.

An acute DVT or PE event after shoulder surgery may dramatically increase the length of hospital stay and total healthcare cost. MacDougall *et al* (21) reported the mean inpatient length of hospital stay for patients with an inpatient diagnosis of DVT and or PE was 10±13 days (median, 6 days), with a mean inpatient confinement costs of \$22,749 (median, \$9587). Using matched controls in patients undergoing major orthopaedic surgery, Oster *et al* (24) further demonstrated the mean length of stay for the index admission was 4.5 days

longer for patients with in-hospital VTE than that of matched controls (11.1 vs 6.6), whilst mean billed charges for the index admission were \$17,552 higher US dollars for the VTE group. This is largely preventable. There is a lack of consensus on the criteria for and type of prophylaxis for DVT/PE following shoulder surgery. In contrast, several reports demonstrate a reduction in the rate of thrombotic events following knee arthroscopy with the prophylactic use of pharmacologic anti-coagulants. Prophylactic anti-coagulation for knee arthroscopic procedures is required only in the presence of thromboembolic risk factors or surgical complications. Elective hip replacement surgery and knee replacement require routine anti-coagulation to prevent risks of DVT.

For acute lower limb DVT, the recommended treatment is using initial low molecular weight heparin (LMWH) and vitamin K antagonist (VKA) for 5 to 7 days (Fig. 2). Treatment is continued with VKA for at least 3 months or 6 to 12 months in the presence of permanent risk factors like malignant disease (11).

Although there is general agreement that acute upper limb DVT requires treatment to prevent extension and emboli, there is a perception among physicians that it does not require extended anti-coagulant therapy (23). There are no randomised clinical trials evaluating the relative safety and efficacy of IV or subcutaneous heparin for initial treatment of upper extremity DVT or anticoagulation for long-term treatment. However, several studies underline the benefits of using treatment regimens identical to those for lower limb DVT (6,8,19,28). Perioperative compression stockings prevent the development of post-thrombotic syndrome in patients with or without documented previous episode of DVT (5,10).

Hereditary and acquired hypercoagulable states and insufficient anti-coagulation contribute to occurrence of VTE events in low molecular weight heparin-treated patients undergoing prosthetic orthopedic surgery (2,3,27).

DVT after shoulder surgery may be underreported. Doppler ultrasound screening of upper and lower extremities is required post-operatively in high-risk patients.

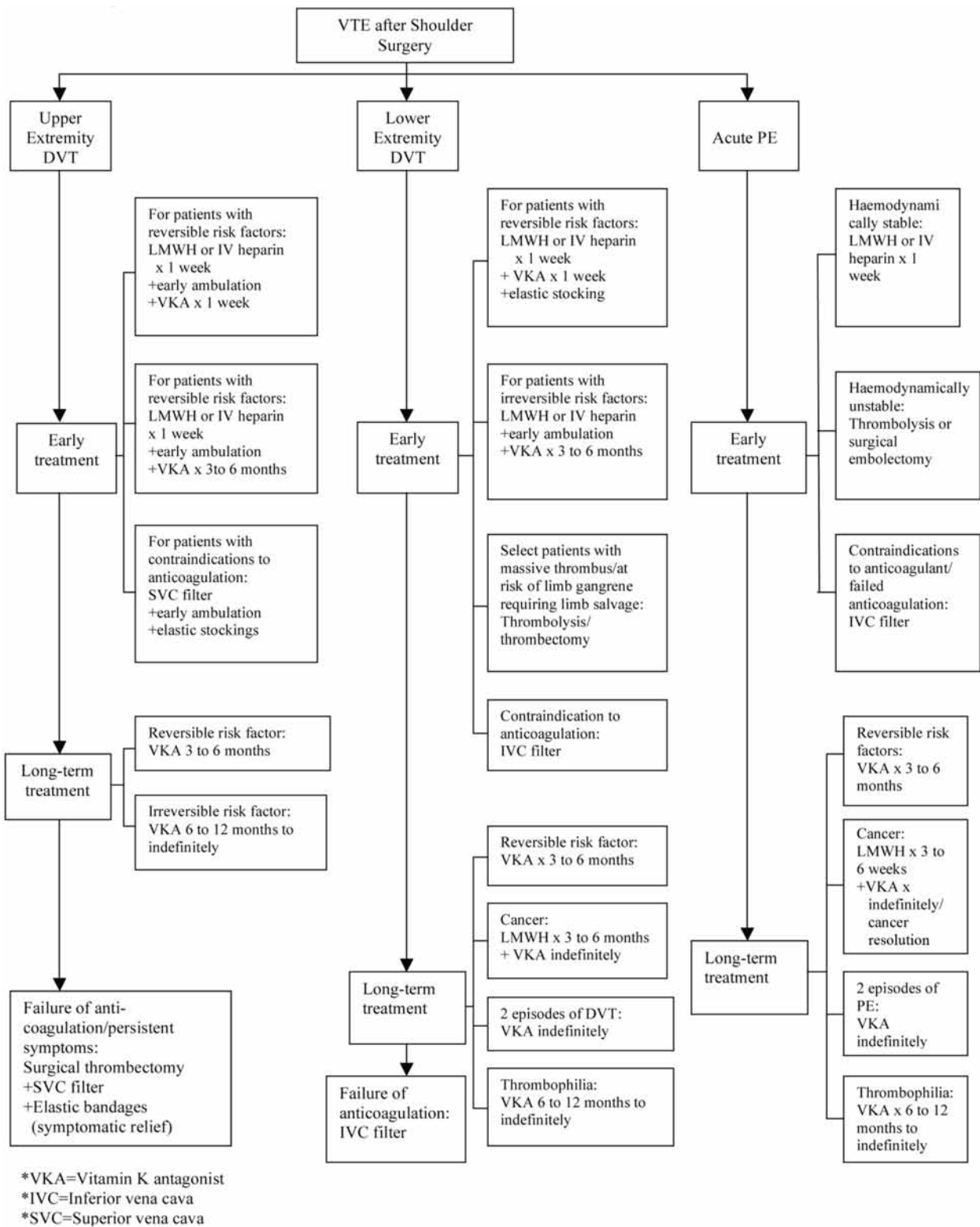


Fig. 2. — Algorithm for VTE after shoulder surgery

Without prophylaxis, rates of deep vein thrombosis (DVT) after major orthopaedic surgery range from 40% to 60%, and prophylaxis to prevent venous thromboembolism (VTE) in patients at risk has been ranked as the highest safety practice for hospitalised patients (7). Therefore, routine use of prophylactic pharmacologic and physical anti-thrombotic agents may be required, especially in patients with significant risk factors, to prevent development of VT/PE after shoulder surgery as these may be clinically silent. Early ambulation/rehabilitation and overall decreased length of hospital stay favor low risk of DVT. Patients undergoing shoulder surgery require anti-thrombotic stockings and automated pneumatic compression perioperatively.

Risks of pharmacologic prophylaxis such as shoulder haematoma and major organ bleed should be explained to the patient before surgery. Leonardi *et al* (17) in a level I evidence report demonstrated bleeding complication rates of < 3%, buttressing the idea that surgical patients could safely receive pharmacological thromboprophylaxis.

This study suggests that DVT may be an uncommon but significant complication of shoulder arthroplasty. Whilst the incidence of DVT after shoulder arthroscopy is low (0.08%), there is little or no evidence about DVT/PE events after open reduction and internal fixation of fractures involving the shoulder joint. Proper patient selection, attention to operative procedure (patient positioning including beach chair positioning, proper traction, and anatomic portal placement), and careful post-operative care can minimise the morbidity associated with these complications if they occur. There is the need for further prospective studies evaluating the prevalence and management of DVT/PE following shoulder surgery.

CONCLUSION

The purpose of our study was to review the available evidence in the published literature regarding incidence, risk factors, diagnosis and management of VTE after shoulder surgery. The eight published studies (seven level II and one level IV) indicate a

variable, low incidence of VTE after shoulder surgery.

REFERENCES

1. Austin H, Key NS, Benson JM *et al*. Sickle cell trait and the risk of venous thromboembolism among blacks. *Blood* 2007 ; 110 : 908-912. doi :10.1182/blood-2006-11-077604.
2. Beksac B, González Della Valle A, Salvati EA. Thromboembolic disease after total hip arthroplasty : who is at risk ? *Clin Orthop Relat Res* 2006 ; 453 : 211-224.
3. Bergqvist D, Benoni G, Björgell O *et al*. Low-molecular-weight heparin (enoxaparin) as prophylaxis against venous thromboembolism after total hip replacement. *N Engl J Med* 1996 ; 335 : 696-700.
4. Bongiovanni SL, Ranalletta M, Guala A, Maignon GD. Case reports : heritable thrombophilia associated with deep venous thrombosis after shoulder arthroscopy. *Clin Orthop Relat Res* 2009 ; 467 : 2196-2199.
5. Brandjes DP, Buller HR, Heijboer H *et al*. Randomised trial of effect of compression stockings in patients with symptomatic proximal-vein thrombosis. *Lancet* 1997 ; 349 : 759-762.
6. Burihan E, de Figueiredo LF, Francisco JJ, Miranda Júnior F. Upper extremity deep venous thrombosis : analysis of 52 cases. *Cardiovasc Surg* 1993 ; 1 : 19-22.
7. Colwell CW Jr. Rationale for thromboprophylaxis in lower joint arthroplasty. *Am J Orthop* 2007 ; 36(9 Suppl) : 11-13.
8. Feugier P, Aleksic I, Salari R, Durand X, Chevalier JM. Long-term results of venous revascularization for Paget-Schroetter syndrome in athletes. *Ann Vasc Surg* 2001 ; 15 : 212-218.
9. Francis CW, Pellegrini VD Jr, Stulberg BN *et al*. Prevention of venous thrombosis after total knee arthroplasty. Comparison of antithrombin III with low-dose heparin and dextran. *J Bone Joint Surg* 1990 ; 72-A : 976-982.
10. Garofalo R, Notarnicola A, Moretti L *et al*. Deep vein thromboembolism after arthroscopy of the shoulder : two case reports and a review of the literature. *BMC Musculoskel Disord* 2010 ; 11 : 65.
11. Geerts WH, Bergqvist D, Pineo GF *et al*. Prevention of venous thromboembolism : American College of Chest Physicians Evidence-Based Clinical Practice Guidelines (8th Edition). *Chest* 2008 ; 133 (6 Suppl) : 381S-453S.
12. Ginsberg JS, Hirsh J, Julian J *et al*. Prevention and treatment of postphlebotic syndrome : results of a 3-part study. *Arch Intern Med* 2001 ; 161 : 2105-2109.
13. King AD, Bell SD, Stuttle AW *et al*. Platelet imaging of thromboembolism. Natural history of postoperative deep venous thrombosis and pulmonary embolism illustrated using the 111 In-labelled platelet-specific monoclonal antibody, P256. *Chest* 1992 ; 101 : 1597-600.

14. **Kudsk KA, Fabian TC, Baum S et al.** Silent deep vein thrombosis in immobilized multiple trauma patients. *Am J Surg* 1989 ; 158 : 515-519.
15. **Kuremsky MA, Cain L, Fleischli J.** Thromboembolic events after arthroscopic shoulder surgery : a case series of unusual complications. *Arthroscopy* 2007 ; 23(6) : e18-e19.
16. **Laporte S, Mismetti P, Decousus H et al.** Clinical predictors for fatal pulmonary embolism in 15,520 patients with venous thromboembolism : findings from the Registro Informatizado de la Enfermedad TromboEmbolica venosa (RIETE) Registry. *Circulation* 2008 ; 117 : 1711-1716. doi:10.1161/CIRCULATIONAHA.107.726232.
17. **Leonardi MJ, McGory ML, Ko CY.** The rate of bleeding complications after pharmacologic deep venous thrombosis prophylaxis : a systematic review of 33 randomized controlled trials. *Arch Surg* 2006 ; 141 : 790-797.
18. **Lieberman JR, Geerts WH.** Prevention of venous thromboembolism after total hip and knee arthroplasty. *J Bone Joint Surg* 1994 ; 76-A : 1239-1250.
19. **Lindblad B, Tengborn L, Bergqvist D.** Deep vein thrombosis of the axillary-subclavian veins : epidemiologic data, effects of different types of treatment and late sequelae. *Eur J Vasc Surg* 1988 ; 2 : 161-165.
20. **Lyman S, Sherman S, Carter TI et al.** Prevalence and risk factors for symptomatic thromboembolic events after shoulder arthroplasty. *Clin Orthop Relat Res* 2006 ; 448 : 152-156.
21. **MacDougall DA, Feliu AL, Boccuzzi SJ, Lin J.** Economic burden of deep-vein thrombosis, pulmonary embolism, and post-thrombotic syndrome. *Am J Health-Syst Pharm* 2006 ; 63(20 Suppl 6) : S5-15.
22. **Mansfield AO.** Alteration in fibrinolysis associated with surgery and venous thrombosis. *Br J Surg* 1972 ; 59 : 754-757.
23. **Munoz JF, Mismetti P, Poggio R et al.** Clinical outcome of patients with upper-extremity deep vein thrombosis : results from the RIETE registry. *Chest* 2008 ; 133 : 143-148. doi :10.1378/chest.07-1432.
24. **Oster G, Ollendorf DA, Vera-Llonch M et al.** Economic consequences of venous thromboembolism following major orthopedic surgery. *Ann Pharmacotherapy* 2004 ; 38 : 377-382.
25. **Paramo JA, Rocha E.** Changes in coagulation and fibrinolysis after total hip replacement and their relations with deep vein thrombosis. *Haemostasis* 1985 ; 15 : 345-352.
26. **Paramo JA, Rocha E.** Deep vein thrombosis and related platelet changes after total hip replacement. *Haemostasis* 1985 ; 15 : 389-394.
27. **Planes A, Vochelle N, Darmon JY et al.** Risk of deep-venous thrombosis after hospital discharge in patients having undergone total hip replacement : double-blind randomised comparison of enoxaparin versus placebo. *Lancet* 1996 ; 348 : 224-228.
28. **Pradoni P, Bernardi E.** Upper extremity deep vein thrombosis. *Curr Opin Pulm Med* 1999 ; 5 : 222-226.
29. **Randelli P, Castagna A, Cabitza F et al.** Infectious and thromboembolic complications of arthroscopic shoulder surgery. *J Shoulder Elbow Surg* 2010 ; 19 : 97-101.
30. **Reiff DA, Haricharan RN, Bulington NM et al.** Traumatic brain injury is associated with the development of deep vein thrombosis independent of anticoagulation therapy. *J Trauma* 2009 ; 66 : 436-440.
31. **Rockwood CA Jr, Wirth MA, Blair S.** Warning : pulmonary embolism can occur after elective shoulder surgery-report of two cases and survey of the members of the American Shoulder and Elbow Surgeons. *J Shoulder Elbow Surg* 2003 ; 12 : 628-630.
32. **Schreijer AJM, Cannegieter SC, Meijers JC et al.** Activation of coagulation system during air travel : a crossover study. *Lancet* 2006 ; 367 (9513) : 832-839.
33. **Sperling JW, Cofield RH.** Pulmonary embolism following shoulder arthroplasty. *J Bone Joint Surg* 2002 ; 84-A : 1939-1941.
34. **Stern SH, Insall JN.** Haematologic effects of total knee arthroplasty. A prospective evaluation. *Clin Orthop Relat Res* 1993 ; 286 : 10-14.
35. **Stulberg BN, Insall JN, Williams GW, Ghelman B.** Deep-vein thrombosis following total knee replacement. An analysis of six hundred and thirty-eight arthroplasties. *J Bone Joint Surg* 1984 ; 66-A : 194-201.
36. **White RH.** The epidemiology of venous thromboembolism. *Circulation* 2003 ; 107 : 1-4. doi:10.1161/01.CIR.0000078468.11849.66.
37. **Willis AA, Warren RF, Craig EV et al.** Deep vein thrombosis after reconstructive shoulder arthroplasty : a prospective observational study. *J Shoulder Elbow Surg* 2009 ; 18 : 100-106.