



## Comparison between two classifications of humeral head fractures : Neer and AO-ASIF

Stefano GUMINA, Giuseppe GIANNICOLA, Paolo ALBINO, Daniele PASSARETTI, Gianluca CINOTTI, Franco POSTACCHINI

*From the department of Orthopaedics and Traumatology, University of Rome "Sapienza", Rome, Italy*

**Our purpose was to verify if the Neer and AO-ASIF classifications for fractures of the proximal humerus satisfy the requisites of simplicity and reproducibility and if the parameters that they consider to establish the severity of the fracture are similar.**

**Two of the authors classified the proximal humeral fractures of 227 patients based on plain radiographs, and they repeated the classification five years later. The reliability, reproducibility and coherence of the classifications were investigated.**

**Inter-observer reliability was  $K = 0.77$  (Neer) and  $K = 0.65$  (AO-ASIF) while intra-observer reproducibility was  $K = 0.68$  (examiner I) and  $K = 0.63$  (examiner II). In 1/5 of the cases, disagreement led to a different classification of the same fracture. Furthermore, neither classification establishes a linear scale of gravity able to provide an indication for treatment.**

**The Neer and AO-ASIF classifications have a low reproducibility and reliability when fractures, especially those with 3 or 4 parts, are assessed by means of plain radiographs. Therefore, patients with complex fractures should be submitted to CT to have a correct pre-operative diagnosis.**

**Keywords :** humeral head fractures ; Neer classification ; AO-ASIF classification ; reproducibility, reliability.

### INTRODUCTION

The purpose of a fracture classification is to establish, following conventional parameters such as morphologic characteristics and fracture level, a

simple and memorisable scale of fracture severity and outcome and to guide fracture treatment. A classification should have a high reproducibility and reliability and allow a meaningful comparison of results between different studies.

Several classifications of proximal humeral head fractures have been suggested. In 1896 Kocher (19) proposed a classification based on the anatomical level of the fracture. Codman (8) distinguished four main anatomical fragments of the fracture : greater tuberosity, lesser tuberosity, articular segment and surgical neck. In 1945 Dehen (11) presented a new classification based on aetiopathogenic mechanisms. These classifications did not have a wide

- Stefano Gumina, MD, PhD, Professor Orthopaedic surgery and Traumatology.
- Giuseppe Giannicola, MD, Professor Orthopaedic surgery and Traumatology.
- Paolo Albino, MD, Resident.
- Daniele Passaretti, MD, Resident.
- Gianluca Cinotti, MD, Professor Orthopaedic surgery and Traumatology.
- Franco Postacchini, MD, Professor Orthopaedic surgery and Traumatology.

*Department of Orthopaedics and Traumatology, University of Rome "Sapienza", Rome, Italy.*

Correspondence : Prof. Stefano Gumina, Department of Orthopaedics and Traumatology, University of Rome "Sapienza", Piazzale Aldo Moro 3, 00185, Rome, Italy.

E-mail : s.gumina@tiscali.it

© 2011, Acta Orthopædica Belgica.

application, but represented the basis of the successive systems, together with the studies of Laing (22) on the vascularisation of the humeral head. In 1970 Neer (29) proposed a new classification, which is currently the most widely used ; this was based on the anatomy of the humeral head, on the biomechanics of the injury and on displacement of the fragments. This classification distinguishes four main parts (humeral head, lesser and greater tuberosity and shaft), 6 Groups (I-VI) and 16 Subgroups, according to the level of the fracture or fracture-dislocation and to the importance of the displacement of one or more parts (30). The AO-ASIF classification (34), which is not so widely used, distinguishes 27 subgroups on the basis of location, articular involvement, degree of comminution and associated shoulder dislocation, with special emphasis on the integrity of the vascular supply. This system distinguishes valgus impacted four-part proximal humerus fractures from other four-part injuries with partial preservation of vascular inflow to the articular segment through the medial capsule.

The validity of the Neer and AO-ASIF classification has been scarcely analysed. Court-Brown *et al* (10) found the AO-ASIF classification more comprehensive than the Neer system, while Naranja and Iannotti (28) emphasised the usefulness of Neer's criteria in intraoperative decision making. Nevertheless it emerged that both classifications have a low reproducibility and reliability ( $0.25 < K$  coefficient of Cohen  $< 0.75$ ) (20,35).

The purpose of this study was to verify if the two most commonly used classifications of humeral head fractures satisfy the requisites of simplicity, clinical usability and reproducibility and if their differing principles of codification may lead to a different treatment approach of the same fracture.

## MATERIALS AND METHODS

Between 1993 and 2001, 642 patients with a proximal humeral fracture were conservatively treated at our department. At the time of injury, the mean age of the patients (205 males and 437 females) was 73 years (range : 18-97 years). In 2004 all the fractures were catalogued by two authors using the Neer system. Six

years later, 250 of the 642 medical records were randomly selected and 23 were eliminated because of poor radiographic quality. For each of the 227 cases included, at least two preoperative radiographic views were available (true AP + axillary views in 99 cases and true AP + axillary and outlet view in 128). The same two authors separately catalogued again the 227 fractures according to the Neer and AO-ASIF classification. They were not involved in the random selection of the cases. Both expert examiners with a different clinical experience (the first examiner more specifically competent than the second one), were provided with a goniometer, a millimeter-scale and the description of the two classification systems.

Intra-observer reliability was analysed for both classifications while intra-observer reproducibility, after 6 years, was analysed for each of the two authors. Reasons for disagreement were assessed as well as the correlation between reproducibility and degree of clinical experience of the two authors. Finally, the classifications were compared in order to assess the coherence between the two systems.

## Statistical Analysis

The kappa coefficient of Cohen was used, as a statistical measure of inter-rater agreement, to assess the inter-observer reliability and reproducibility of the classification (9). This coefficient (K) can have values from -1 to 1 (-1 = highest disagreement ; 0 = random agreement ; 1 = highest agreement). K values  $< 0.8$  stand for a non optimal reproducibility or reliability (23).

## RESULTS

### NEER classification

In 2004, the examiners' classifications were in agreement for 71.8% of the fractures (Concordance  $K = 0.77$ ). In 48 of the 227 fractures, the degree of disagreement between the examiners was appreciable. The same fracture was allotted to different groups in 20.7% of the cases or subgroups in 7.4% of the cases (Fig. 1) ; in 82% of these cases there was a fracture of the surgical neck with the participation of one or both tuberosities. After 6 years, examiner II classified the same fracture similarly as before in 73.1% of the cases (reproducibility :  $K = 0.63$ ) and examiner I in 68.7% of the cases (repro-

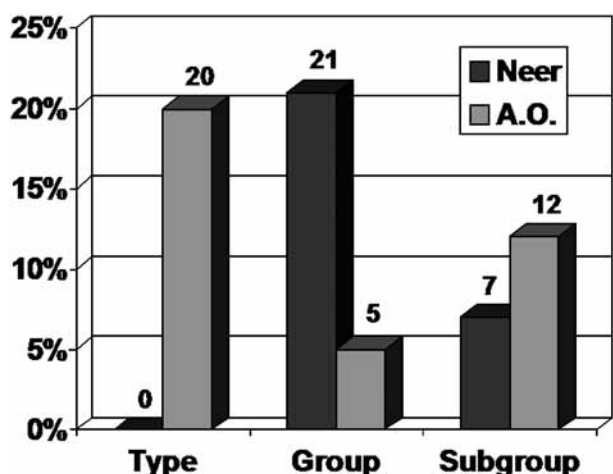


Fig. 1. — Graphic representation of examiners discordance in fracture classification.

ducibility :  $K = 0.68$ ). The different experience of the examiners did not influence the reproducibility of this classification ( $K = 0.68$  and  $K = 0.63$ ). Table I shows the classifications of the 227 fractures carried out by the two examiners.

#### AO-ASIF classification

Concordance between the two examiners was observed in 62.9% of the cases ( $K = 0.65$ ). In 45 of the 227 fractures, the degree of disagreement between the examiners was considerable and led to a different classification of the same fracture ; 20.2%, 4.8% and 11.9% of the fractures examined were catalogued, respectively, into different Types, Groups or Subgroups (Fig. 1). Disagreement occurred above all for extra-articular fractures. Table II shows the classifications of the 227 fractures according to the two examiners.

#### Coherence between the two classifications

A single fracture belonging to a specific group of the Neer classification could be catalogued into different Groups of the AO-ASIF classification, which includes fractures with satisfactory (type A) or unsatisfactory (type C) prognosis. This discordance was seen especially for the following fractures : Groups : I, II, IV 2 part (2p), V 2p and VI 2p. At the same time, it emerged that different AO-ASIF

Table I. — The Neer classification of the 227 included fractures by the two examiners

Type of fracture	Examiner I	Examiner II
Group I	83	81
Group II	3	2
Group III	33	38
Group IV 2p	19	26
Group V 2p	2	2
Group IV 3p	24	21
Group V 3p	3	2
4 part fractures	14	8
Group VI 2p	43	41
Group VI 3p	0	2
Group VI 4p	3	4
TOTAL	227	227

Groups corresponded to different Neer Groups : e.g., B1.1 and B2.1 fractures (AO-ASIF) corresponded, respectively, to Group I, III, IV2p, IV3p and I, III, V 2p, V 3p (Neer). Furthermore, Groups B2.1 and B2.3 (AO-ASIF) corresponded to Neer Group I, III, IV 2p, V 2p and IV 3p. Table III shows the correspondence between the two systems.

#### DISCUSSION

Both classifications (Neer and AO-ASIF) were difficult to memorise, compromising their practical use during ordinary clinical practice. After 6 years, the reproducibility of the Neer classification was low for both examiners and not significantly dependent of the level of expertise, contrary to what has been reported by other studies (20,39). Moreover, a recent study demonstrated that training improves agreement among both experts and non-experts (74).

The highest percentage of disagreement was found with fractures belonging to Group III, IV 2p and 4p of Neer and Type B of AO-ASIF classification, or with those pluri-fragmented fractures in which it was hard to establish the degree and type of displacement. Neither classification establishes a clear linear scale of the severity of the fracture, able to provide an immediate indication for treatment ; besides, the prognosis of the fracture is not always deducible from the group it belongs to, and does not worsen with the progression of the groups. For

Table II. — The AO-ASIF classification of the 227 included fractures by the two examiners

Groups	Examiner I	Examiner II
A 1.1	15	21
A 1.2	7	2
A 1.3	41	40
A 2.1	15	21
A 2.2	21	15
A 2.3	2	0
A 3.1	2	2
A 3.2	3	5
A 3.3	2	0
B 1.1	71	83
B 1.2	2	3
B 1.3	12	0
B 2.1	0	2
B 2.2	10	15
B 2.3	0	5
B 3.2	0	2
C 1.1	3	2
C 1.2	2	0
C 1.3	2	2
C 2.1	3	0
C 2.2	7	0
C 2.3	2	0
C 3.2	3	2
C 3.3	2	5
TOTAL	227	227

example, the non or slightly displaced fractures of the anatomical neck may be classified in opposite groups between the two classifications – Group I

(Neer) and Group C (AO-ASIF) – as well as displaced fractures of the greater tuberosity combined with gleno-humeral dislocation – Group A (AO-ASIF) and Group VI (Neer). The fracture of the greater tuberosity with proximal migration of the fragment causing narrowing of the subacromial space (generally with a negative prognosis) could be catalogued in Group I of Neer and in Group A1.2 of AO-ASIF, while the same fracture with a distal migration of the tuberosity (generally with a good prognosis) is catalogued in Group IV of Neer and A2.2 of AO-ASIF (32). Furthermore, a fracture of the surgical neck with a 30° varus displacement leading to poor results in 80% of cases (32), is classified in the first group of both classifications (Group I of Neer and Group A2.2 of AO-ASIF), while fractures of the surgical neck with a marked valgus displacement of the humeral head and an inferior or posterior displacement of the greater tuberosity (11% of unsatisfactory results in our experience) are catalogued, respectively, in Group III and B2.3.

Both classifications have an excessive subdivision into Groups, which is not always useful during ordinary clinical practice : for example, fractures 1p and 2p of Neer classification and those belonging to Group A1, A2, A3, B1 are similar in prognosis and therapeutic indications in most cases (16). Despite this, some types of fractures associated with poor results, for example those of the surgical neck with

Table III. — The Neer and AO-ASIF classification of each fracture compared : a fracture catalogued in a particular Neer Group may be catalogued in different Groups of the AO-ASIF system

Group I	A1.1, A1.2, A2.1, A2.2, (A2.3), (A3.1), (A3.3), B1.1, (B1.2), B1.3, (B2.1), (B2.3), C1.1, C1.2, (C1.3)
Group II	C1.3, (C2.1), (C2.2)
Group III	A2.1, A2.2, A2.3, A3.1, A3.2, A3.3, B1.1, (B1.2), B1.3, B2.1, B2.2, (B2.3)
Group IV 2p	A1.2, B1.1, B1.3, (B2.1), B2.3, (C1.1), (C1.2)
Group V 2p	A1.1, B1.2, (B2.1), (B2.3), (C1.1), (C1.2)
Group IV 3p	B1.1, B1.3, B2.1, B2.2, B2.3
Group V 3p	B1.2, (B2.2)
4 part fractures	C1.1, C2.1, C2.2, C2.3, C3.3
Group VI 2p	A1.3, (B3.1), (B3.2), (C3.1), C3.2
Group VI 3p	B3.2, (B3.3), C3.2
Group VI 4p	C3.2, C3.3
Fractures of the articular segment	(C2.3), (C3.3)

slight varus displacement or those with an upward migrated greater tuberosity, are not well identified in either classification (2,32).

Our study highlighted the scarce coherence between the two classifications : the same fracture may be catalogued differently by the two systems. For example, among extra-articular bifocal fractures, those of Group B1.1 (AO-ASIF), are included in different Groups of Neer system (Group I, III, IV 2p and IV 3p). Furthermore, Group I of Neer (generally with a good prognosis) corresponds, in the AO-ASIF system, to many Groups with satisfactory and unsatisfactory prognosis (A1.1, A1.2, A2.1 A2.2, A2.3, A3.1, A3.3, B1.1, B1.2, B1.3, B2.1, B2.3, C1.1, C1.2, C1.3). We found many contrasting points between the two classifications and a low reproducibility and reliability. These data may explain the great disagreement concerning therapeutic indications and results presented in literature with humeral head fractures (14,15,17,21,24,25,31,33, 36,37,39,42,43,48).

Finally, these two systems are based on the accurate determination of the degree of angular displacement of the four main segments ; nevertheless, the radiographical examination did not allow an accurate evaluation, especially in the case of complex fractures. This fact raised doubts concerning the classification of a single fracture using the two systems ; such doubts can be blamed on the disagreement and low reproducibility which resulted from this study and from others (3,4,6,20,26,35,38, 39,41).

Neer in 2002 stated that reliable use of the 4-segment system requires exacting roentgen studies and knowledgeable interpretation of the films. Previous studies revealed that lateral scapular projections do not improve the reliability and reproducibility of the Neer and AO-ASIF classifications (35,40,44). CT has been shown to be useful when conventional radiography is not sufficient due to low quality imaging and presence of osseous overlap (1). Furthermore, CT reveals fractures not clearly seen on plain radiographs and contributes to a better understanding of displaced three and four-part fractures (5,46) ; it is also valuable in delineating the configuration of the fracture, helping to plan surgical reconstruction (13,47). For this reason, further

studies have tried to incorporate computed tomographies (CTs and 3D reconstructions) in delineating the fracture patterns and subsequently applying the Neer classification, reporting contrasting results (12,45).

In conclusion, our study shows that the Neer and AO-ASIF classifications are not compatible with each other and are time-consuming. They may lead to different treatment approaches for the same fracture, depending on the classification used.

The two classifications have a low reproducibility and reliability, above all when they refer to 3 and 4 parts fractures and when the classification is made based on standard radiographic views. Therefore, we suggest submitting patients with complex fractures to CT evaluation.

## REFERENCES

1. **Bahrs C, Rolauffs B, Südkamp NP et al.** Indications for computed tomography (CT-) diagnostics in proximal humeral fractures : a comparative study of plain radiography and computed tomography. *Musculoskelet Disord* 2009 ; 10 : 33-39. doi :10.1186/1471-2474-10-33.
2. **Bahrs C, Schmal H, Lingenfelter E et al.** Inter- and intraobserver reliability of the MTM-classification for proximal humeral fractures : A prospective study. *Musculoskelet Disord* 2008 ; 9 : 21-31. doi :10.1186/1471-2474-9-21.
3. **Bernstein J, Adler LM, Blank JE et al.** Evaluation of the Neer system of classification of proximal humeral fractures with computerized scans and plain radiographs. *J Bone Joint Surg* 1996 ; 78-A : 1371-1379.
4. **Brien H, Nofthal F, MacMaster S et al.** Neer's classification system : a critical appraisal. *J Trauma* 1995 ; 38 : 257-260.
5. **Brorson S, Bagger J, Sylvest A, Hrobjartsson A.** Diagnosing displaced four-part fractures of the proximal humerus : a review of observer studies. *Int Orthop* 2009 ; 33 : 323-327. doi : 10.1007/s00264-008-0591-2.
6. **Brorson S, Bagger J, Sylvest A, Hrobjartsson A.** Low agreement among 24 doctors using the Neer classification ; only moderate agreement on displacement, even between specialists. *Int Orthop* 2002 ; 26 : 271-273. doi :10.1007/s00264-002-0369-x.
7. **Brorson S, Hrobjartsson A.** Training improves agreement among doctors using the Neer system for proximal humeral fractures in a systematic review. *J Clin Epidemiol* 2008 ; 61 : 7-16. doi : 10.1016/j.jclinepi.2007.04.014.
8. **Codman EA.** *The Shoulder*. T Todd, Boston, 1934.
9. **Cohen EA.** Weighted kappa : nominal scale agreement with prevision for scaled disagreement or partial credit. *Psychol Bull* 1968 ; 70 : 213.

10. **Court-Brown CM, Garg A, McQueen MM.** The epidemiology of proximal humeral fractures. *Acta Orthop Scand* 2001 ; 72 : 365-371.
11. **Dehen E.** Fractures of the upper end of the humerus : a classification based on the etiology of trauma. *Surg Clin North Am* 1945 ; 25 : 28-47.
12. **Edelson G, Kelly I, Vigder F, Reis ND.** A three-dimensional classification for fractures of the proximal humerus. *J Bone Joint Surg* 2004 ; 86-B : 413-425. doi :10.1302/0301-620X.86B3.14428.
13. **Edelson G, Saffuri H, Obid E, Vidger F.** The three-dimensional anatomy of proximal humeral fractures. *J Shoulder Elbow Surg* 2009 ; 18 : 535-544. doi :10.1016/j.jse.2009.03.001.
14. **Esser RD.** Open reduction and internal fixation of three- and four-part fractures of the proximal humerus. *Clin Orthop Relat Res* 1994 ; 299 : 244-251.
15. **Frich LH, Sojbjerg JO, Sneppen O.** Shoulder arthroplasty in complex acute and chronic proximal humeral fractures. *Orthopedics* 1991 ; 14 : 949-954.
16. **Giannicola G, Gumina S, Cinotti G, Postacchini F.** [Reproducibility and usefulness of the Neer classification of fractures and fracture-dislocations of the proximal humerus.] (in Italian). *GIOT* 1998 ; 24 : 323-332
17. **Jaberg H, Warner JJP, Jakob RP.** Classification and aspect of treatment of fractures of the proximal humerus. *J Bone Joint Surg* 1984 ; 74-A : 508-515.
18. **Jakob RP, Kristiansen T, Mayo K et al.** Classification and aspect of treatment of fractures of the proximal humerus. In : Bateman JE, Welsh RP (eds). *Surgery of the Shoulder*. Philadelphia, Decker, 1984, p 330-343.
19. **Kocher T.** *Beitrage zur Kenntnis einiger praktischer wichtiger Fractur-Formen*. Carl Sallman Verlage, Basel, 1896.
20. **Kristiansen B, Andersen ULS, Olsen CA, Varmarken JE.** The Neer classification of fractures of the proximal humerus. *Skeletal Radiol* 1988 ; 17 : 420-422.
21. **Kristiansen B, Christensen SW.** Proximal humeral fractures. *Acta Orthop Scand* 1987 ; 58 : 124-127.
22. **Laing PG.** The arterial supply to the adult humerus. *J Bone Joint Surg* 1956 ; 38-A : 1105-1116.
23. **Landis JR, Koch GC.** The measurement of observer agreement for categorical data. *Biometrics* 1977 ; 33 : 159-174.
24. **Leyshon RL.** Closed treatment of fractures of the proximal humerus. *Acta Orthop Scand* 1984 ; 55 : 48-51.
25. **Moechel BH, Dines DM, Warren RF, Altchek DW.** Modular hemiarthroplasty for fractures of the proximal part of the humerus. *J Bone Joint Surg* 1992 ; 74-A : 884-889.
26. **Mora Guix JM, Pedrós JS, Castaño Serrano A.** Updated classification system for proximal humeral fractures. *Clin Med Res*. 2009 ; 7 : 32-44. doi : 10.3121/cmr.2009.779.
27. **Muller ME, Nazarian S, Koch P, Schatzker J.** *The Comprehensive Classification of Fractures of the Long Bones*. Springer, Berlin, 1990.
28. **Naranja R Jr, Iannotti JP.** Displaced three- and four-part proximal humeral fractures : evaluation and management. *J Am Acad Orthop Surg* 2000 ; 8 : 373-382.
29. **Neer CS II.** Displaced proximal humeral fractures. Part I. Classification and evaluation. *J Bone Joint Surg* 1970 ; 52-A : 1077-1089.
30. **Neer CS II.** Displaced proximal humeral fractures. Part II. Treatment of the three-part and four-part displacement. *J Bone Joint Surg* 1970 ; 52-A : 1090-1103.
31. **Paavolainen P, Bjorkenheim JM, Slati P, Pakku P.** Operative treatment of severe proximal humeral fractures. *Acta Orthop Scand* 1983 ; 54 : 374-379.
32. **Postacchini F, Giannicola G, Gumina S, Perugia D.** [Surgical treatment of fractures and fractures-dislocations of the proximal humerus. Long-term results.] (in Italian). *GIOT* 1997 ; 23 : 147-156.
33. **Robinson CM, Christie J.** The two-part proximal humeral fracture : a review of operative treatment using two techniques. *Injury* 1993 ; 24 : 123-125.
34. **Bohsali KI, Wirth MA.** Fractures of the proximal humerus. In : Rockwood CA Jr, Matsen FA III. *The Shoulder*. 4<sup>th</sup> ed, Volume I, WB Saunders, Philadelphia, 2009.
35. **Sallay PI, Pedowitz RA, Mallon WJ et al.** Reliability and reproducibility of radiographic interpretation of proximal humeral fracture pathoanatomy. *J Shoulder Elbow Surg* 1997 ; 6 : 60-69.
36. **Sartori E, Fusi M, Gaudenzi A, Cantalamessa G.** Long-term results of conservatively treated fractures of the upper end of the humerus.] (in Italian). *Archivio Putti-Chir Organi Mov* 1989 ; 37 : 389-396.
37. **Savoie FH, Geissler WB, Vander Griend RA.** Open reduction and internal fixation of three-part fractures of the proximal humerus. *Orthopedics* 1989 ; 12 : 65-70.
38. **Sharder MW, Sanchez-Sotelo J, Sperling JW, Rowland CM, Cofield RH.** Understanding proximal humerus fractures : Image analysis, classification, and treatment. *J Shoulder Elbow Surg* 2005 ; 14 : 497-505.
39. **Sidor ML, Zuckerman JD, Lyon T et al.** The Neer classification system for proximal humeral fractures. An assessment of interobserver reliability and intraobserver reproducibility. *J Bone Joint Surg* 1993 ; 75-A : 1745-1750.
40. **Sidor ML, Zuckerman JD, Lyon T et al.** Classification of proximal humerus fractures : The contribution of the scapular lateral and axillary radiographs. *J Shoulder Elbow Surg* 1994 ; 3 : 24-27.
41. **Siebenrock KA, Gerber C.** The reproducibility of classification of fractures of the proximal end of the humerus. *J Bone Joint Surg* 1993 ; 75-A : 1751-1755.
42. **Siebler G, Kuner EH.** [Initial experience using the dynamic hip screw in osteosynthesis of femoral neck fractures.] (in German). *Hefte Unfallheil* 1987 ; 186 : 171-178.
43. **Siebler G, Kuner EH.** [Late results after operative treatment of fractures of the proximal humerus in adults.] (in German). *Unfallchirurg* 1985 ; 11 : 119-126.

44. **Sjoden G, Movin T, Guntner P et al.** Poor reproducibility of classification of proximal humeral fractures : additional CT of minor value. *Acta Orthop Scand* 1997 ; 68 : 239-242.
45. **Sjoden G, Movin T, Guntner P et al.** 3D-radiographic analysis does not improve the Neer and AO classifications of proximal humeral fractures. *Acta Orthop Scand* 1999 ; 70 : 325-328.
46. **Tamai K, Ishige N, Kuroda S et al.** Four-segment classification of proximal humeral fractures revisited : A multicenter study on 509 cases. *J Shoulder Elbow Surg* 2009 ; 18 : 845-850. doi :10.1016/j.jse.2009.01.018.
47. **Wadlington VR, Hendrix RW, Rogers LF.** Computed tomography of posterior fracture-dislocation of the shoulder : case report. *J Trauma* 1992 ; 32 : 113-115.
48. **Young TB, Wallace WA.** Conservative treatment of fractures and fracture-dislocations of the upper end of the humerus. *J Bone Joint Surg* 1985 ; 67-B : 373-377.