



## The percutaneous use of a pointed reduction clamp during intramedullary nailing of distal third tibial shaft fractures

Jordanna M. FORMAN, Adriana M. URRUELA, Kenneth A. EGOL

*From the Musculoskeletal Research Center, NYU Hospital for Joint Diseases, New York, NY, USA and the Jamaica Hospital Medical Center, Jamaica, NY, USA*

The purpose of this retrospective chart and radiographic review is to describe an effective reduction technique during intramedullary nailing of distal metaphyseal tibia fractures with the use of a pointed percutaneous clamp.

Between 2007 and 2010, 100 patients who sustained 102 tibia fractures were definitively treated with an intramedullary nail at one of two medical centers. Diaphyseal fractures and injuries with an associated disruption of the distal tibiofibular joint were excluded from our study. A total of 27 patients with 27 distal metaphyseal tibia fractures (OTA types 42-A, 43-A, and 43-B) were included. All 27 patients underwent IM nailing of their fractures with anatomic reduction achieved using a percutaneously placed pointed reduction clamp prior to insertion of the IM implant. Fracture alignment and angular deformity was assessed using goniometric measurement functions on the PACS system (GE, Waukesha, WI) obtained from preoperative and postoperative anteroposterior and lateral images for all subjects. Malalignment was defined as more than 5° of angulation in any plane.

Fourteen of the fractures were classified as OTA 42-A, 9 were OTA 43-A, and 4 were OTA 43-B. Analysis of post-closed reduction, preoperative anteroposterior radiographs revealed a mean of 7.9° of coronal plane (range : 0.9°-26°) angulation. Post closed reduction preoperative lateral radiographs revealed a mean of 6.8° sagittal plane (range : 0°-24.6°) angulation. Postoperative anteroposterior and lateral radiographs showed the distal segment returned to its anatomical alignment with a mean angulation of 0.5° (range, 0°-3.5°) and 0.7° (range, 0°-4.2°) of varus/

valgus and apex anterior/posterior angulation, respectively. These results showed an acceptable postoperative alignment in all 27 distal third fractures. No intra-operative or postoperative complications were noted in the study group.

This study suggests that the use of percutaneous clamps during intramedullary nailing of distal metaphyseal tibia fractures is an easily-reproducible and effective method of reduction with no associated intraoperative complications.

**Keywords :** intramedullary nailing, distal tibia, reduction technique.

### INTRODUCTION

The management of distal third tibia fractures is challenging due to their close proximity to the ankle joint. Although the optimal treatment of unstable distal tibia fractures remains controversial, a variety

- 
- Jordanna Forman, BS, Research Associate.
  - Adriana Urruela, BS, Research Associate.
  - Kenneth Egol, MD, Chief, Division of Fracture Surgery.  
*Musculoskeletal Research Center, NYU Hospital for Joint Diseases, New York, NY.*
- Correspondence : Jordanna M. Forman, BS, 301 E 17<sup>th</sup> Street, Suite 1500, New York, NY 10003, 212-598-6460.  
E-mail : Jordanna.Forman@nyumc.org  
© 2011, Acta Orthopædica Belgica.
-

of different treatment methods have been suggested including : nonoperative treatment, external fixation, open reduction and internal fixation (ORIF), minimally invasive plate osteosynthesis (MIPO), and intramedullary nailing (13). Apart from being the “gold standard” for the treatment of tibial mid-shaft fractures, intramedullary nailing is gaining popularity for the treatment of extra articular and simple intra articular metaphyseal fractures-AO/OTA types 42 A and 43-A,B. The surgical management of metaphyseal distal tibia fractures is potentially more complicated than their midshaft counterparts due to the difficulty in reducing the short distal fragment that articulates with the ankle (8). A number of strategies for gaining alignment prior to IM nail passage have been described, including : “blocking screws”, temporary external fixation, temporary unicortical plate and screw placement, use of a femoral distractor and fibular plating (1,3,4,6,11). Although these techniques are effective, their intraoperative application adds length to the time of the surgical procedure. We have utilized percutaneously placed pointed reduction clamps to accurately reduce the distal fragment of the tibial fracture to an anatomic alignment prior to guide wire placement for intramedullary nailing. This technique has proven to be a reliable method of reduction for extra articular and simple intra articular distal tibial fractures.

## MATERIALS AND METHODS

Between 2007 and 2010, 100 patients who sustained 102 tibia fractures were definitively treated with an intramedullary nail at a level 1 trauma center or an academic medical center. Of the 102 cases available for retrospective review, a total of 27 patients with 27 distal third tibia fractures (OTA types 42-A, 43-A, and 43-B) were identified by individual retrospective chart and radiographic review and included in our study cohort. Diaphyseal fractures, as defined by any area proximal to the isthmus of the diaphysis, were excluded as well as injuries with an associated disruption of the distal tibiofibular joint. Fractures that extended to the articular surface were considered acceptable for the purposes of our study. Operative records were reviewed to identify the method of reduction ; any method other than the percutaneous clamp was excluded. All subjects were treated

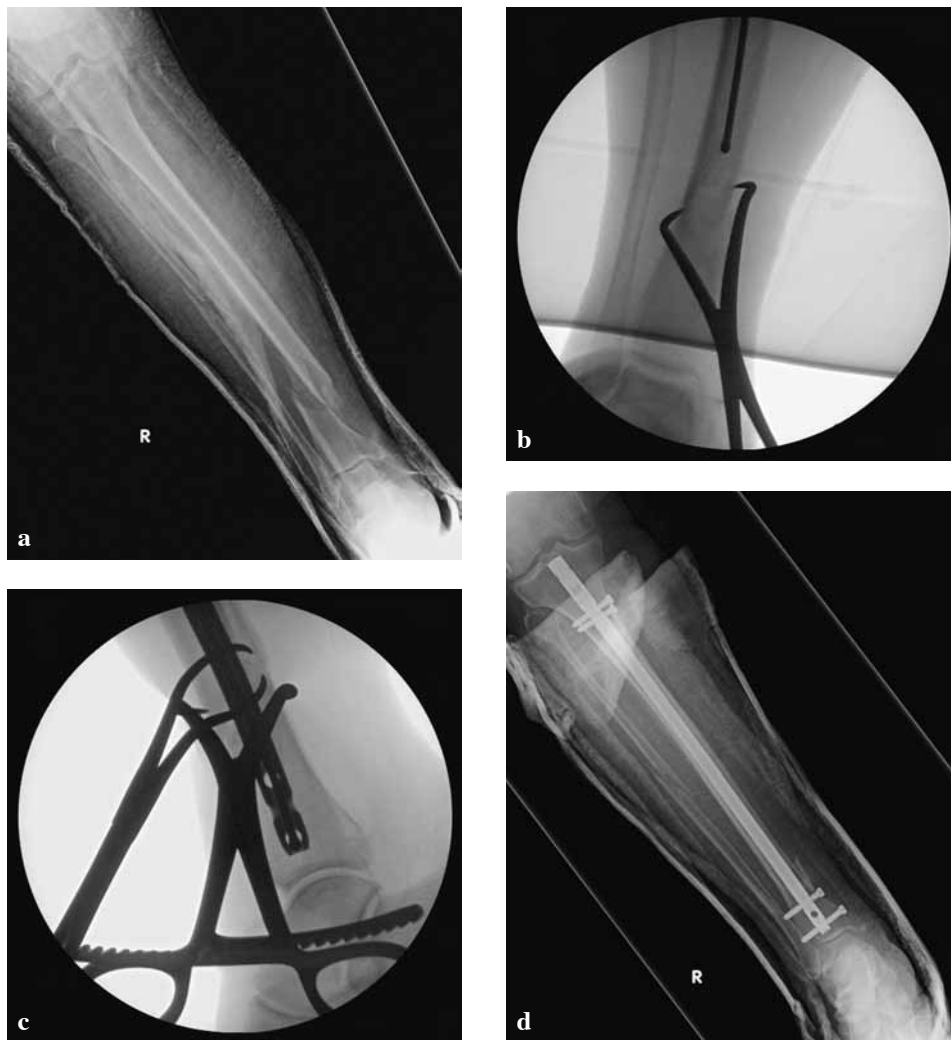
surgically by one of two orthopaedic trauma fellowship-trained surgeons with a statically locked, intramedullary nail, each with a diameter of 10 mm. All tibias were reamed prior to intramedullary nail insertion and locked with a minimum of two screws proximally and distally.

The study cohort included 13 women and 14 men with an average age of 47 (range : 20-89 years). All patients were skeletally mature. The mechanism of injury was a low velocity fall in 15 patients, a high velocity fall in 1, a twisting injury in 5, a motor vehicle accident in 2, pedestrian struck in 2, a crush injury in 1 and a motorcycle accident in 1. Of the 27 metaphyseal tibia fractures, 5 were open, 22 were closed, 25 had an associated fibula fracture, and 4 had both an open wound and a fibula fracture. Fourteen of the fractures were classified as OTA 42-A, 9 were OTA 43-A, and 4 were OTA 43-B. Fractures that extended into the ankle joint (OTA 43-B) were provisionally stabilized prior to nailing using lag screws across the joint. When there was an associated distal fibula fracture, the fibula was not plated in any case.

Preoperative and postoperative anteroposterior and lateral radiographic films were obtained and examined for all subjects. Radiographs were obtained at 6 weeks, 3, 6 and 12 month clinical follow-up and were evaluated to determine time to union. Fracture alignment and angular deformity was assessed using goniometric measurements as described by Freedman and Johnson (7). Malalignment was defined as more than 5° of angulation in any plane.

## SURGICAL TECHNIQUE

The patient with a distal metaphyseal tibia fracture was positioned supine on a radiolucent fracture table. Intravenous prophylactic antibiotics were administered and the extremity was prepped and draped in the usual sterile fashion. If present, open wounds were treated with irrigation and debridement, followed by bony stabilization. The standard starting point for the intramedullary nail was identified at the proximal tibia with a guide pin and was confirmed with anteroposterior and lateral image intensification. The entry portal was reamed, and the beaded-tip guide wire was passed down the intramedullary canal of the tibia until it was proximal to the fracture site. Stab incisions were made around the fracture site and a pointed reduction clamp was applied to afford reduction between the major fracture fragments.



**Fig. 1** — a : 61 year-old female, fall LV sustained a closed distal tib-fib fracture, AP radiograph. b : intra-operative picture showing beaded tip guidewire being passed down the intramedullary canal proximal to the fracture site with one set of clamps holding a reduced position. c : after insertion of the intramedullary nail, two clamps employed to maintain reduction. d : postoperative IM nailing with reduction obtained using clamps (Fig. a, b), AP radiograph.

The distal fragment was then reduced by reversing the deforming forces that caused the fracture in order to return the limb to a more anatomic position. If the fracture proved difficult to reduce with one clamp, a second was used to obtain reduction in the orthogonal plane. Fluoroscopic evaluation in the coronal and sagittal planes was performed to confirm anatomic alignment. Percutaneously placed clamps were used to correct translation in fractures as close to 0° angulation in any plane as possible. The canal was then reamed incrementally and an

appropriately sized nail was inserted over the guide wire while maintenance of the clamp(s) ensured reduction (Fig. 1). The nail was then inserted over the wire with the tibia held in a reduced position. The nail was then locked proximally and distally to stabilize the construct.

## RESULTS

Twenty-seven patients with 27 tibia fractures were treated with the described technique.

Radiographic analysis of preoperative anteroposterior radiographs revealed a mean of  $7.9^\circ$  of coronal plane (range :  $0.9^\circ$ - $26^\circ$ ) angulation (Fig. 2a). Preoperative lateral radiographs revealed a mean of  $6.8^\circ$  sagittal plane (range :  $0^\circ$ - $24.6^\circ$ ) angulation (Fig. 2b). Radiographs taken post operatively were then evaluated to determine the final alignment. All of the 27 patients were found to have acceptable alignment. Postoperative anteroposterior and lateral radiographs showed the distal segment returned to its anatomical alignment with a mean angulation of  $0.5^\circ$  (range,  $0$ - $3.5^\circ$ ) and  $0.7^\circ$  (range,  $0^\circ$ - $4.2^\circ$ ) of varus/valgus and apex anterior/posterior angulation, respectively (Fig. 2c, d). Twenty of the 27 patients (74%) had complete clinical and radiographic follow-up at the time of union, the remaining 7 were lost to follow-up. Radiographic union was achieved by an average of 4.4 months. Two patients (7.4%) had a delayed union and healed at a mean 10 months ; one was treated with an external bone stimulator and both fractures eventually went on to unite. Another patient (3.7%) underwent reoperation for removal of painful hardware. In one case, there was locking bolt breakage and the patient's fracture healed in  $3^\circ$  of varus ; removal of hardware was never indicated.

## DISCUSSION

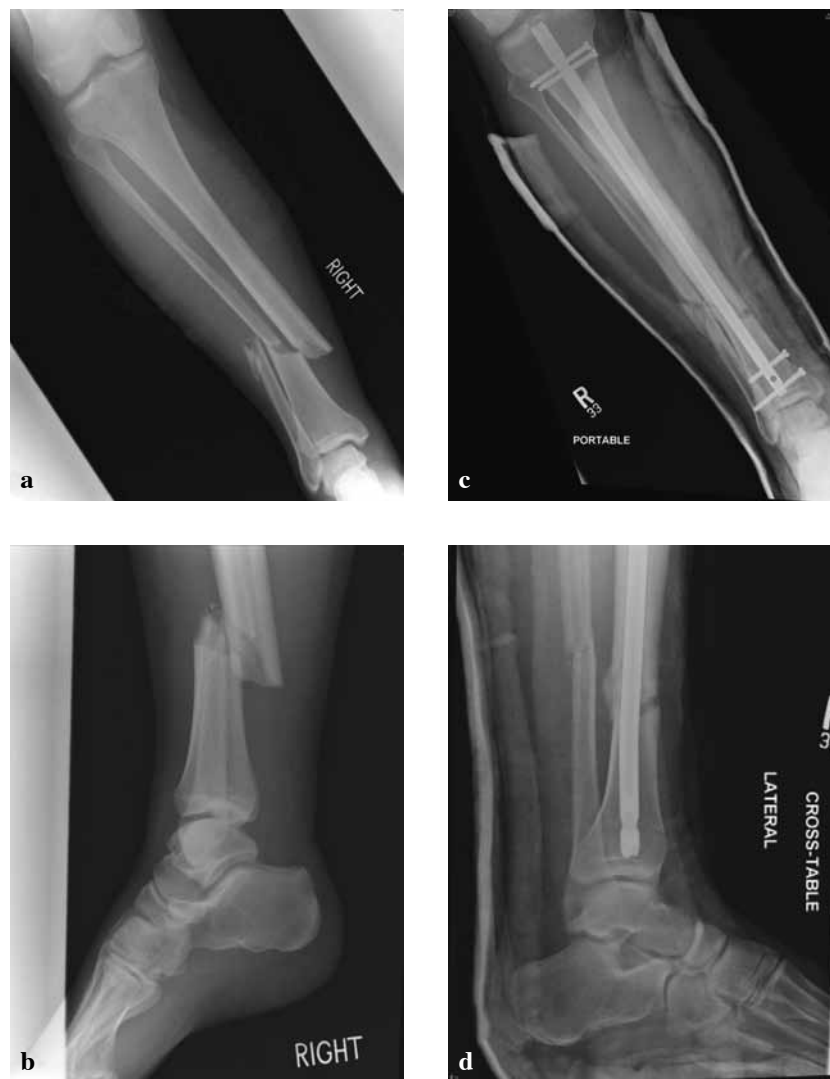The reduction of distal metaphyseal tibia fractures can be difficult due to the short length of the distal fragment, the widening of the medullary canal and the proximity to the tibial plafond. Careful preoperative planning must be employed and take into consideration fracture displacement, comminution, proximity to the ankle joint and the extent of soft-tissue damage (5). Once an intramedullary nail has been selected as the definitive treatment method, the surgeon must decide on the preferred or most appropriate reduction technique. Careful control of the distal segment is critical in achieving acceptable reduction, which must be attained to prevent angular deformity and malunion. In this report we found that the use of percutaneously placed pointed reduction clamps can afford a fracture reduction comparable to other techniques with no associated complications.

Furthermore, this technique afforded our cohort alignment within  $5^\circ$  of neutral in every case. Of the 27 patients evaluated, 27 were found to have acceptable post-operative alignment.

Surgical reduction techniques other than the pointed reduction percutaneous clamp include, but are not limited to : blocking screws, the use of a femoral distractor, external fixation or "traveling traction", fibular plating and temporary unicortical plate and screw fixation (1,4,6,11,12).

In a biomechanical study, Krettek *et al* (10) used fresh human cadaveric tibiae to measure the force-displacement curves before and after placing blocking or "Poller screws" in the proximal and distal third segments of the tibia. They found that the blocking screws decreased the deformation in the distal bone-implant constructs by 57%. In support of this finding, Krettek *et al* (11) applied the use of blocking screws clinically to gain alignment and supplement stability after fixation with intramedullary nailing of proximal and distal tibial fractures. The authors discovered that the use of "Poller screws" decreased the width of the metaphyseal medulla, improved construct stability after nail insertion, prevented nail translation and facilitated with reduction by preventing axial deformities during nailing with minimal soft tissue disruption. A potential complication with the utilization of blocking screws is irritation around the ankle where the screws are placed due to the thin layer of soft tissue and skin. This is also considered to be a technically challenging method and may prove difficult in achieving precise reduction of severely comminuted fractures.

The use of a femoral distractor, although more commonly used for IM nailing of femur fractures, can also be employed to obtain reduction of distal fractures of the tibia. The distractor offers an alternative to the fracture table and provides stability when nailing (2). For distal tibia fractures, pins are placed posteriorly in the proximal metaphysis and distally in the talus or calcaneus (4). This technique allows for complete and gross control over the extremity, however, it is limited in its ability to control smaller fragments and may require additional manipulation manually or with clamps.



**Fig. 2** — a : 43 year-old male sustained a closed tib-fib fracture from a crush injury, AP preoperative radiograph. b : AP postoperative radiograph. c : lateral preoperative radiograph. d : lateral postoperative radiograph.

Similarly, Wysocki *et al* (12) reported on the postoperative radiographic outcome of intramedullary nailing of proximal and distal one-third tibial shaft fractures using intraoperative two-pin external fixation, or “traveling traction.” The results of this study revealed 25 of the 27 patients with distal third tibia fractures to have acceptable alignment with 5° or less of angulation in every plane and less than 1 cm shortening. The authors concluded that traveling traction is a useful and effective tool in obtaining intraoperative reduction. However, the set up time

for the fixation device is significant and can obstruct insertion of locking screws.

Although only relevant to distal tibia fractures with an associated fibula fracture, a study conducted by Egol *et al* (6) examined the effect of stabilization of the fibula in addition to IM nailing of the tibia compared to IM nailing alone. The purpose was to evaluate whether or not adjunctive fibular fixation resulted in a lower incidence of malalignment post operatively. The authors of this study found that fixation of the associated fibula fracture

aided in maintaining alignment intraoperatively and resulted in a significantly lower incidence of malalignment and/or loss of alignment (4% compared to 13% without stabilization of the fibula) when treating distal third tibia-fibula fractures with an IM nail. This technique has proven effective in the maintenance of alignment post operatively ; however, it increases operative time and may lead to morbidity at the fibular surgical site.

Finally, the use of temporary unicortical fracture fixation plates can be applied as an intraoperative technique for reducing distal tibia fractures prior to definitive fixation. Typically implemented in the treatment of proximal third tibia fractures, as described by Kim *et al* (9), this technique has been proven effective in decreasing rates of malalignment, enhancing fracture stability and minimizing the disruption of the vascular periosteum during reaming. In a study by Archdeacon *et al* (1), the use of this technique, termed "reduction plating," was found to provide the same benefits in the treatment of distal third tibia fractures. Although usually effective in achieving and maintaining alignment, if the reduction plate is fixed with the fracture in a malreduced position, it is necessary that the plate be removed and corrected. Larger incisions needed for this technique may be compromised in an already damaged soft tissue envelope. Another complication is the possibility that the unicortical screws intersect with the path of the reamer.

In this study we found that the use of a pointed reduction percutaneous clamp for the reduction of distal metaphyseal tibia fractures provides direct and precise manipulation of the small distal segment. The use of the clamps does not require excessive set up time prior to the operation and does not significantly increase the length of the procedure. This method is also minimally disruptive to the soft-tissue and periosteum, therefore it decreases the risk of vascular insult. This technique offers a controlled and exact method of obtaining reduction in these historically difficult to treat injuries. Limitations of this technique include the presence of a purely transverse fracture pattern. In such cases, other perioperative alignment strategies should be chosen. An oblique or spiral fracture pattern is optimal for the reduction clamps to be utilized.

## CONCLUSION

The use of percutaneous clamps during intramedullary nailing of distal third tibia fractures is an effective and easily reproducible method to achieve anatomic alignment. We achieved acceptable postoperative alignment in 27 of 27 (100%) distal tibia fractures using this technique. There is no absolute standard for acceptable reduction ; however, we considered an amount less than 5 degrees of angulation within any plane to be sufficiently aligned. Although no reduction technique for distal metaphyseal tibia fractures is universally accepted, we believe that the use of the pointed reduction percutaneous clamp is a comparable, if not superior technique to those which are commonly used.

## REFERENCES

1. Archdeacon MT, Wyrick JD. Reduction plating for provisional fracture fixation. *J Orthop Trauma* 2006 ; 20 : 206-211.
2. Baumgaertel F, Dahlen C, Stiletto R, Gotzen L. Technique of using the AO-femoral distractor for femoral intramedullary nailing. *J Orthop Trauma* 1994 ; 8 : 315-321.
3. Beazley JC, Hull P. Temporary intra-operative reduction techniques for tibial fracture fixation : A review of the literature. *Injury* 2010 ; 41 : 1228-1233.
4. Bedi A, Le TT, Karunakar MA. Surgical treatment of nonarticular distal tibia fractures. *J Am Acad Orthop Surg* 2006 ; 14 : 406-416.
5. Cheng W, Li Y, Manyi W. Comparison study of two surgical options for distal tibia fracture-minimally invasive plate osteosynthesis vs. open reduction and internal fixation. *Int Orthop* 2011 ; 35 : 737-742.
6. Egol KA, Weisz R, Hiebert R *et al*. Does fibular plating improve alignment after intramedullary nailing of distal metaphyseal tibia fractures ? *J Orthop Trauma* 2006 ; 20 : 94-103.
7. Freedman EL, Johnson EE. Radiographic analysis of tibial fracture malalignment following intramedullary nailing. *Clin Orthop Relat Res* 1995 ; 315 : 25-33.
8. Joveniaux P, Ohl X, Harisboure A *et al*. Distal tibia fractures : management and complications of 101 cases. *Int Orthop* 2010 ; 34 : 583-588. PMID : 2903136.
9. Kim KC, Lee JK, Hwang DS, Yang JY, Kim YM. Provisional unicortical plating with reamed intramedullary nailing in segmental tibial fractures involving the high proximal metaphysis. *Orthopedics* 2007 ; 30 : 189-192.

10. **Krettek C, Miclau T, Schandelmaier P et al.** The mechanical effect of blocking screws ("Poller screws") in stabilizing tibia fractures with short proximal or distal fragments after insertion of small-diameter intramedullary nails. *J Orthop Trauma* 1999 ; 13 : 550-553.
11. **Krettek C, Stephan C, Schandelmaier P et al.** The use of Poller screws as blocking screws in stabilising tibial fractures treated with small diameter intramedullary nails. *J Bone Joint Surg* 1999 ; 81-B : 963-968.
12. **Wysocki RW, Kapotas JS, Virkus WW.** Intramedullary nailing of proximal and distal one-third tibial shaft fractures with intraoperative two-pin external fixation. *J Trauma* 2009 ; 66 :1135-1139.
13. **Zelle BA, Bhandari M, Espiritu M, Koval KJ, Zlowodzki M.** Treatment of distal tibia fractures without articular involvement : a systematic review of 1125 fractures. *J Orthop Trauma* 2006 ; 20 : 76-79.