



Results of ulnar shortening osteotomy for ulnocarpal abutment after malunited distal radius fracture

Masahiro TATEBE, Takaaki SHINOHARA, Nobuyuki OKUI, Michiro YAMAMOTO, Toshihiko IMAEDA, Hitoshi HIRATA

From Nagoya University School of Medicine and Kinjo Gakuin University School of Human Life and Environment, Nagoya, Japan

Surgical correction for ulnocarpal abutment syndrome after malunited distal radius fracture remains controversial. We reviewed sixteen patients (7 men, 9 women) who underwent isolated ulnar-shortening osteotomy for ulnar wrist pain as their main complaint. Mean age was 48 years. The range of flexion-extension increased from 81° to 103°, and range of supination-pronation from 120° to 142° after osteotomy. Mean grip strength increased from 49% to 69%. Mayo wrist score was excellent in 2 cases, good in 7 cases, fair in 6 cases, and poor in 1 case. Grip strength was found to correlate with radial inclination and flexion-extension range with the amount of ulna shortening.

Keywords: ulnar shortening osteotomy ; malunited distal radius fracture ; ulnar wrist pain.

INTRODUCTION

Distal radius fracture (DRF) is one of the most common fractures ; 10% of women over 65 years of age are expected to sustain such a fracture (13). Malunion of DRF most often results in radial shortening as the main deformity, and presents clinically as ulnocarpal abutment syndrome (UCA) (10,15,17, 20). Corrective osteotomy of the distal part of the radius – the logical treatment of malunion – may be technically difficult (7,13). We use to perform isolated ulnar-shortening osteotomy (USO) if the main deformity of the radius is shortening (8,21).

Consensus has yet to be reached regarding what constitutes an 'acceptable' radiological position before or after treatment (7,8,12,21). In an attempt to identify potential predictors of functional outcome after ulnar shortening osteotomy for malunited DRF apart from shortening, we studied the three other key radiological indices (volar tilt [VT], radial inclination [RI], ulnar variance [UV]). All abbreviations used are listed in Table I.

- Masahiro Tatebe MD, PhD, Hand Surgeon, Assistant professor.
- Takaaki Shinohara MD, PhD, Hand Surgeon, Assistant professor.
- Nobuyuki Okui MD, PhD, Hand Surgeon, Assistant professor.
- Michiro Yamamoto MD, PhD, Hand Surgeon, Assistant professor.
- Hitoshi Hirata MD, PhD, Hand Surgeon, Professor.
Department of Hand Surgery, Nagoya University School of Medicine.
- Toshihiko Imaeda MD, PhD, Hand Surgeon, Professor.
Department of Food and Nutritional Environment, Kinjo Gakuin University School of Human Life and Environment, Nagoya, Japan.

Correspondence : Tatebe Masahiro MD, Department of Hand Surgery, Nagoya University School of Medicine, 65 Tsurumaicho, Showaku, Nagoya 466-8550, Japan.

E-mail : tatebe@med.nagoya-u.ac.jp

© 2012, Acta Orthopædica Belgica.

Table I. — Abbreviations used

DRF	distal radius fracture
UCA	Ulnocarpal abutment syndrome
USO	ulnar-shortening osteotomy
VT	volar tilt
RI	radial inclination
UV	ulnar variance
SNI	Sigmoid notch inclination
UHI	ulnar head inclination
DRUJ	distal radioulnar joint

PATIENTS AND METHODS

All study protocols were approved by the institutional review board. Data from patients with ulnocarpal abutment syndrome after malunited DRF were retrospectively reviewed. We selected USO only for cases with a limited volar tilt between -10° and 20° and with good joint congruity. For more severe deformities of malunited DRF, we used corrective osteotomy of the radius with or without USO and these patients were excluded from this study (30). Final diagnosis of abutment was confirmed by arthroscopy showing chondral or osteochondral lesions on the ulnar carpus. Sixteen cases of malunited DRF corresponded with these criteria and were included in the present study. Patient demographics, including age, sex, occupation, and time interval between injury and surgery were reviewed. Mean interval between initial injury and surgery was 39.5 months (range : 5-150 months). Mean duration of follow-up was 72 months (range : 18-180 months). Initial treatment of DRF comprised conservative treatment in 9 cases and operative treatment in 7 cases (percutaneous pinning 6, plating 1). Pre- and postoperative ranges of motion were obtained from clinical charts. Range of motion of the wrist in extension-flexion and pronation-supination was measured using a hand-held goniometer. Grip strength in both hands was measured at the latest follow-up. All patients were assessed using the Mayo wrist score to evaluate preoperative value and final functional outcomes with regard to residual pain, ability to return to work, mobility, and grip strength. The Mayo wrist score uses a 100-point scale comprising separate ratings for pain (25 points), range of motion (25 points), grip strength (25 points), and functional status (25 points), with 100 representing normal wrist function (2).

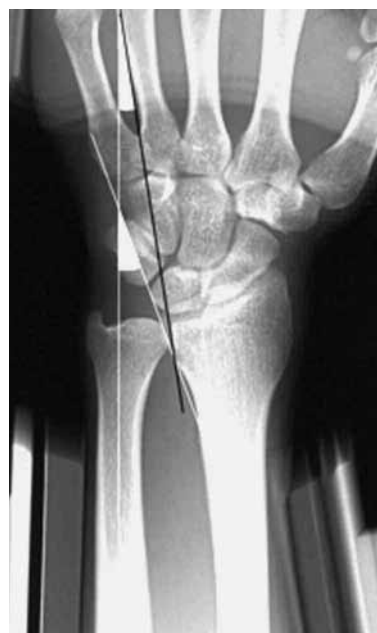

Fig. 1. — Radiological evaluation. Ulnar head inclination represents the angle between the longitudinal shaft of the ulna and the tangent to the ulnar head. Sigmoid notch inclination represents the angle between the longitudinal shaft of the ulna and the tangent to the sigmoid notch of the radius.

Radiological assessment (Fig. 1)

Anteroposterior radiographs were taken with the shoulder in 90° of abduction, the elbow in 90° of flexion and the forearm in neutral rotation. Lateral radiographs were taken with the shoulder in adduction, the elbow in 90° of flexion and the forearm in neutral rotation. Pre- and postoperative radiographic measurements of deformities were obtained by the surgeon : VT, RI, UV, sigmoid notch inclination (SNI), and ulnar head inclination (UHI) (26). UV was measured to the nearest 0.5 mm using the method of perpendiculars (4). In addition, plain radiographs were checked for evidence of bony spur formation. Negative values for VT represent dorsal tilt, and negative values for UV represent an ulna that is shorter than the radius. Negative values for SNI and UHI represent a radial inclination. These parameters were compared with the normal side and delta-values (normal side - affected side) were assessed.

Operative technique (8)

Ulnocarpal abutment was confirmed arthroscopically. The distal ulna was approached through a longitudinal

Table II. — Clinical results

	Pre-op	Post-op
Extension/flexion (df/pf) arc	81 ± 25°	103 ± 22°
Supination/pronation (sup/pro) arc	120 ± 37°	140 ± 32°
Grip strength (%normal)	49 ± 30%	71 ± 19%
Mayo wrist score	28.1 ± 17.1	74.7 ± 10.2

incision between the extensor carpi ulnaris and the flexor carpi ulnaris. We performed a transverse resection of the ulna fixed with a 3.5-mm locking compression plate. The contralateral side served as the reference for the length of shortening. The disappearance of ulnar abutment was then again confirmed arthroscopically. Postoperative immobilization in an above-elbow cast was worn for 3 to 4 weeks.

Statistical analysis

Differences in clinical details such as bony spur at the distal radioulnar joint (DRUJ) and in radiological assessments (UV, length of shortening, RI, VT, SNI, UHI) were analyzed using the Mann-Whitney U test. Spearman's rank correlation coefficient was estimated between clinical results and radiological measurements. All variables are reported as the mean value ± standard deviation. Values of $p < 0.05$ were considered statistically significant and post hoc power analysis was calculated (19). All data analyses were performed using SPSS version 18 software and G*power software.

RESULTS

The data of sixteen cases were available for analysis. Overall, range of wrist motion was significantly better postoperatively (Table II). Complications were rare, with no patients showing ulnar non-union or Complex Regional Pain Syndrome. Mayo wrist score showed that outcomes were excellent in 2 cases, good in 7, fair in 6, and poor in only 1 case. Radiographic measurements of DRUJ alignment (UV, length of shortening, RI, VT, SNI, UHI) are shown in Table III. Post-operative flexion-extension correlated with both pre-operative UV ($r = -0.645$, $\beta = 0.184$) and length of shortening ($r = -0.537$, $\beta = 0.393$) (Fig. 2), and delta-RI ($r = 0.680$, $\beta = 0.128$) (Fig. 3). Post-operative grip strength correlated with RI on the affected side ($r =$

Table III. — Radiological assessments

Pre-op UV (normal side)	4.7 ± 1.9 mm (1.6 ± 1.0 mm)
Delta-UV	3.2 ± 1.5 mm
Post-op UV	1.5 ± 1.2 mm
Length of shortening	3.2 ± 1.1 mm
RI (normal side)	21.4 ± 9.0° (27.1 ± 3.3°)
Delta-RI	5.7 ± 9.8°
VT (normal side)	3.2 ± 11.6° (14.9 ± 4.4°)
Delta-VT	11.7 ± 12.6°
SNI (normal side)	-5.7 ± 14.2° (2.0 ± 5.9°)
Delta-SNI	7.8 ± 12.5°
UHI (normal side)	12.9 ± 7.5° (13.4 ± 5.6°)
Delta-UHI	0.5 ± 5.3°

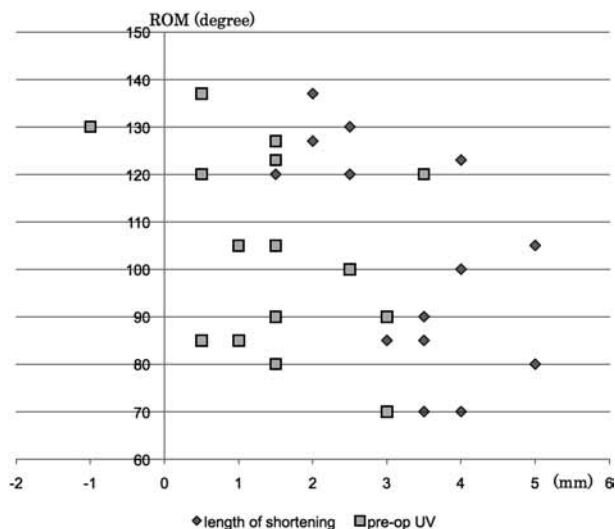


Fig. 2. — Post-operative flexion-extension versus length of shortening and pre-operative ulnar variance ($r = -0.537$, $r = -0.645$, respectively).

0.528, $\beta = 0.411$) and delta-RI (0.570, $\beta = 0.326$) (Fig. 3). No significant correlation was identified between methods of pre-operative treatment (conservative/operative) and parameters as VT. SNI and UHI also showed no correlation with flexion-extension and grip strength. After USO, 10 of 16 wrists showed a bony spur at the DRUJ. No significant associations with bony spur formation were identified for any parameters.

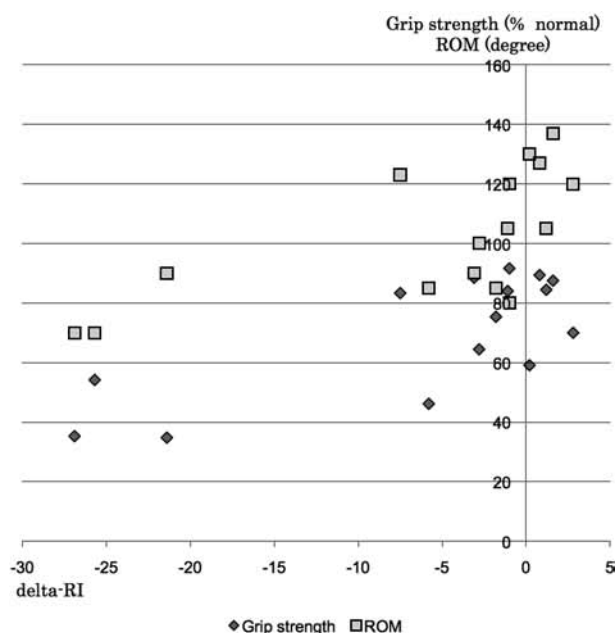


Fig. 3. — Post-operative flexion-extension and grip strength versus delta-RI ($r = 0.680, 0.570$, respectively).

DISCUSSION

The aim of surgery for malunited DRF should be to restore normal anatomy, and surgical correction remains controversial (5). Malunion of DRF often causes discrepancy in the wrist with a long ulna relative to the radius. Restoration of distal radio-ulnar joint congruity using USO is commonly performed to treat UCA (24). The ulnocarpal joint is unloaded and wrist pain relieved. USO satisfactorily restores ulnar variance.

Acceptable limits of the three key radiographic parameters (VT, RI, and UV) after corrective osteotomy have not been clarified (7,12). Orthopaedic surgeons still face a dilemma when deciding between surgical and nonsurgical treatment for DRF (9). Controversy remains regarding acceptable values for malunited fractures (25,29). Moreover, surgical correction of a malunited DRF may be technically difficult (7,13,23). Even if accurate preoperative planning is performed, we should adapt operative methods to correct shortening and realign angular deformities simultaneously. Among the components of the deformity (VT, RI, and UV), RI

accounts less for carpal alignment, and VT clearly shows a greater impact (14,28). Our findings show that clinical results correlate with RI and length of shortening. VT within our criteria showed no correlation with clinical results. Corrective osteotomy of the radius can improve RI and restore length. Combined corrective osteotomy of the radius and USO could avoid excessive shortening of the ulna, although the surgical method is invasive.

USO has been the standard treatment for UCA for many years (1,18); it can be performed for most cases of positive ulnar wrist (5). We have previously reported clinical results for USO and TFCC evaluation (27). Malalignment with respect to ulnar inclination and the sigmoid notch has been considered a relative contraindication for USO (11), which might cause degenerative changes in the DRUJ (6,16,22). Although spur formation occurred in two-thirds of patients in this study, clinical results did not correlate with bony spur formation at the DRUJ. Moreover, this study found no correlation between bony spur formation and radiological alignment. We think USO can be performed irrespective of DRUJ morphology. The advantage of USO is the simplicity of the procedure, which does not require bone grafting (8). The disadvantage of USO is the risk of nonunion/delayed union and irritation by the implant (21). However, the rate of complications could be low if properly performed (1,8). We thus assume USO is only suitable in the malunited DRF with mild axial shortening and minimal tilt in the coronal and sagittal plane.

This study has some limitations. This study was retrospective in design, and included only patients who underwent USO, and none who were treated conservatively or underwent other procedures. Second, the number of cases was small. Differences in each parameter were also relatively small and this small sample size may have limited the statistical power of the analyses. Further prospective research is thus warranted to clarify whether all patients of UCA with malunited DRF need corrective osteotomy.

In conclusion, about half of the patients had a good or excellent result. Radial inclination and the length of ulnar shortening were found to affect the clinical results of USO for malunited DRF. We

recommend USO for the surgical treatment of UCA after malunited DRF, for which the main deformity is moderate radial shortening with a normal radial inclination. In the presence of severe radial shortening and decreased radial inclination, combined osteotomy should be considered.

REFERENCES

- Chun S, Palmer AK.** The ulnar impaction syndrome : follow-up of ulnar shortening osteotomy. *J Hand Surg* 1993 ; 18-A : 46-53.
- Cooney WP, Linscheid RL, Dobyns JH.** Triangular fibrocartilage tears. *J Hand Surg* 1994 : 19-A : 143-154.
- Cummings SR, Black DM, Rubin SM.** Lifetime risks of hip, Colles', or vertebral fracture and coronary heart disease among white postmenopausal women. *Arch Intern Med* 1989 ; 149 : 2445-2448.
- Curtis MS, William FB.** Measuring ulnar variance : a comparison of techniques. *J Hand Surg* 1989 ; 14-A : 607-612.
- El-Karef E.** Staged reconstruction for malunited fractures of the distal radius. *J Hand Surg* 2005 ; 30-B : 73-78.
- Feldon P, Terrono AL, Belsky MR.** Wafer distal ulna resection for triangular fibrocartilage tears and/or ulna impaction syndrome. *J Hand Surg* 1992 ; 17-A : 731-737.
- Fernandez DL.** Correction of post-traumatic wrist deformity in adults by osteotomy, bone grafting and internal fixation. *J Bone Joint Surg* 1982 ; 64-A : 1164-1178.
- Fricker R, Pfeiffer KM, Troeger H.** Ulnar shortening osteotomy in posttraumatic ulnar impaction syndrome. *Arch Orthop Trauma Surg* 1996 ; 15 : 158-161.
- Gehrmann SV, Windolf J, Kaufmann RA.** Distal radius fracture management in elderly patients : a literature review. *J Hand Surg* 2008 ; 33-A : 421-429.
- Geissler WB, Fernandez DL, Lamey DM.** Distal radio-ulnar joint injuries associated with fractures of the distal radius. *Clin Orthop Relat Res* 1996 ; 327 : 135-146.
- Hollevoet N, Verdonk R, Van Maele G.** The influence of articular morphology on non-traumatic degenerative changes of the distal radioulnar joint. A radiographic study. *J Hand Surg* 2006 ; 31-B : 221-225.
- Hunt TR, Hastings H 2nd, Graham TJ.** A systematic approach to handling the distal radio-ulnar joint in cases of mal-united distal radius fractures. *Hand Clinics* 1998 ; 14 : 239-249.
- Jupiter JB, Ruder J, Roth DA.** Computer-generated bone models in the planning of osteotomy of multidirectional distal radius malunions. *J Hand Surg* 1992 ; 17-A : 406-415.
- Karnezis IA, Panagiotopoulos E, Tyllianakis M, Megas P, Lambiris E.** Correlation between radiological parameters and patient-rated wrist dysfunction following fractures of the distal radius. *Injury* 2005 ; 36 : 1435-1439.
- Kihara H, Palmer AK, Werner FW, Short WH, Fortino MD.** The effect of dorsally angulated distal radius fractures on distal radio-ulnar joint congruency and forearm rotation. *J Hand Surg* 1996 ; 21-A : 40-47.
- Köppel M, Hargreaves IC, Herbert TJ.** Ulnar shortening osteotomy for ulnar carpal instability and ulnar carpal impaction *J Hand Surg* 1997 ; 22-B : 451-456.
- Lindau T, Adlercreutz C, Aspenberg P.** Peripheral tears of the triangular fibrocartilage complex cause distal radio-ulnar joint instability after distal radial fractures. *J Hand Surg* 2000 ; 25-A : 464-468.
- Loh YC, Van Den Abbeele K, Stanley JK, Trail IA.** The results of ulnar shortening for ulnar impaction syndrome. *J Hand Surg* 1999 ; 24-B : 316-320.
- Mayr S, Errdfelder E, Buchner A, Faul F.** A short tutorial of G Power. *Tutorials Quant Method Psychol* 2007 ; 3 : 51-59.
- Milch H.** Treatment of disabilities following fracture of the lower end of the radius. *Clin Orthop Relat Res* 1963 ; 29 : 157-163.
- Oskam J, Kingma J, Klasen HJ.** Ulnar-shortening osteotomy after fracture of the distal radius. *Arch Orthop Trauma Sur.* 1993 ; 112 :198-200.
- Palmer AK, Glisson RR, Werner FW.** Relationship between ulnar variance and triangular fibrocartilage complex thickness. *J Hand Surg* 1984 ; 9-A : 681-682.
- Ring D, Roberge C, Morgan T, Jupiter JB.** Osteotomy for malunited fractures of the distal radius : a comparison of structural and nonstructural autogenous bone grafts. *J Hand Surg* 2002 ; 27-A : 216-222.
- Saffar P.** The pathology of the long ulna : anatomy and treatment. *J Hand Surg* 2007 ; 32-E : 608-619.
- Schuind F, Alemzadeh S, Stallenberg B, Burny F.** Does the normal contralateral wrist provide the best reference for X-ray film measurements of the pathologic wrist ? *J Hand Surg* 1996 ; 21-A : 24-30.
- Sagerman SD, Zogby RG, Palmer AK, Werner FW, Fortino MD.** Relative articular inclination of the distal radioulnar joint : a radiographic study. *J Hand Surg* 1995 ; 20-A : 597-601.
- Tatebe M, Horii E, Nakao E et al.** Repair of the triangular fibrocartilage complex after ulnar-shortening osteotomy : second-look arthroscopy. *J Hand Surg* 2007 ; 32-A : 445-449.
- Villar RN, Marsh D, Rushton N, Greatorex RA.** Three years after Colles' fracture. A prospective review. *J Bone Joint Surg* 1987 ; 69-B : 635-638.
- von Campe A, Nagy L, Arbab D, Dumont CE.** Corrective osteotomies in malunions of the distal radius : do we get what we planned ? *Clin Orthop Relat Res* 2006 ; 450 : 179-185.
- Wada T, Tatebe M, Ozasa Y et al.** Clinical outcomes of corrective osteotomy for distal radial malunion : a review of opening and closing-wedge techniques *J Bone Joint Surg* 2011 ; 93-A : 1619-1926.