



## Thermal energy for the arthroscopic treatment of tears of the triangular fibrocartilage of the wrist

Ignacio GARCIA-LOPEZ, Pedro J. DELGADO, Jose M. ABAD, Fernando GARCIA DE LUCAS

*From Hospital Fremap Majadahonda, Madrid, Spain*

**We evaluated the clinical and occupational outcomes of arthroscopic treatment with electrothermal shrinkage for triangular fibrocartilage complex (TFCC) tears. We retrospectively reviewed 162 patients. All patients had ulnar-sided wrist pain that limited their occupational and sporting activities. The surgical technique consisted of electrothermal collagen shrinkage of the TFCC. Pain relief, range of motion, complications, reoperation rate, time to return to work and workers' compensation claims were evaluated. Exclusion criteria were distal radioulnar joint instability and association of other wrist lesions. Complete pain relief was noted in 80.3% of the patients, incomplete pain relief in 14.8%, and only 4.9% required reoperation because of pain persistence. The average range of motion was over 90% compared to the opposite hand. Worker's compensation claims were introduced by 20 patients, of which 6 did not return to their previous occupation. Electrodiathermy may be a useful option for arthroscopic treatment of TFCC tears in cases without distal radioulnar joint instability.**

**Keywords:** wrist; triangular fibrocartilage complex; electrodiathermy; collagen shrinkage.

### INTRODUCTION

The usual management of TFCC tears is currently arthroscopic repair by means of various suturing and reinsertion techniques, with which several authors have reported good to excellent results (1-

3,16,18,20,21,23). Recently, Infanger and Grimm (9) reported 72 cases using laser assisted arthroscopy for various types of TFCC tears, excluding those with distal radio ulnar joint (DRUJ) instability. They found excellent results in terms of range of motion and pain relief.

Collagen type I fibers provide mechanical stiffness and strength to ligaments and joint capsules. When heat is applied to it, collagen undergoes denaturation due to destruction of its intermolecular bonds, which leads to shrinkage of collagen fibers. Based on the existence of collagen type I-fibers in the structure of the TFCC (22) and the demonstrated shrinking and stiffening effect of thermal energy on collagen-rich tissues (5-7,10,15,19), we hypothesize that thermocoagulation may be an optional procedure for the treatment of TFCC tears. Besides the mechanical effects of thermal energy by providing stiffness to the TFCC, we consider it may also have

- 
- Ignacio Garcia-Lopez, MD, orthopaedic surgeon.
  - Pedro J Delgado, MD, orthopaedic surgeon.
  - Jose M. Abad, MD, chief of orthopaedic surgery department.
  - Fernando Garcia De Lucas, MD, Ph D, orthopaedic surgeon and hospital medical director.

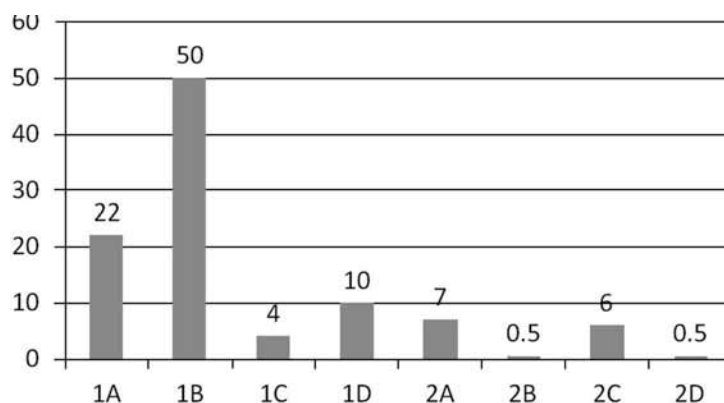
*Upper Limb Unit, Hospital Fremap Majadahonda, Madrid, Spain.*

Correspondence : Ignacio Garcia-Lopez, Hospital Fremap Majadahonda, carretera pozuelo, nº 61 Majadahonda ZP 28222, Madrid (Spain).

E-mail : dr.joseignaciogarcialopez@gmail.com

© 2012, Acta Orthopædica Belgica.

---



*Fig. 1.* — TFCC tears findings according to Palmer's classification

a local denervation effect which could contribute to pain relief.

The primary aim of this study was to analyze the clinical outcomes in working compensation patients with TFCC tears undergoing wrist arthroscopy with thermocoagulation.

#### PATIENTS AND METHODS

Our inclusion criteria were patients diagnosed with TFCC tears by arthroscopy. The indication for surgery was continuous pain on the ulnar side of the wrist without clinical improvement after conservative treatment. The exclusion criteria were DRUJ instability in the pre-operative physical examination, and association with other wrist lesions (fractures, carpal instabilities).

We retrospectively reviewed all arthroscopies performed between 2003 and 2009; among these, 162 matched our inclusion criteria. There were 115 men (71%) and 47 women (29%). The dominant hand was involved in 115 cases (71%). Patients' occupations were classified based on their physical demand: low, medium and high; 76% of the cases fitted in a medium or high physically demanding occupation.

The average time between initial trauma and surgery was 7.2 months (range: 1.5-17). Prior to surgery, all patients had followed conservative treatment including rest, non-steroid anti-inflammatory drugs and physiotherapy for at least 6 weeks.

#### Physical Examination and Radiographic Evaluation

All patients reported a history of trauma. The most frequent mechanism was wrist torsion caused by gripping activities under load (35%).

On physical examination, ulnar wrist pain was found in 87 patients (53.7%), pain in the DRUJ region in 84 patients (51.9%), and a combination of both in 22 (13.6%). In active pronosupination and ulnar deviation of the wrist against resistance, pain was exacerbated in 21 patients (13%).

Plain radiographs of the wrist – posteroanterior view in pronation and lateral – were taken at the initial evaluation to identify any bony lesion. MRI was performed prior to surgery in all patients, showing TFCC tear in 72.2% of them.

#### Surgical Technique

All procedures were performed with the patients in supine position and using a wrist arthroscopy traction tower (Acumed®, Hillsboro, Oregon, USA). Arthroscopic portals were 3-4 as visualization portals, and 4-5 or 6R as working portals. Midcarpal portals were performed in all cases for additional evaluation. The surgical instruments used were a 2.7 mm arthroscope with 30° oblique lens, a 3.5 meniscus shaver and an arthroscopic monopolar thermal probe (Arthrocare®, Austin, Texas, USA). Surgical procedures were performed by three different surgeons of the hand surgery unit.

The TFCC was assessed and classified according to Palmer classification; findings are shown in figure I. The trampoline effect and the hook test were performed when no central or radial tear was found, to assess the TFCC mechanical resistance. Thermocoagulation was applied to the TFCC (or its remnant) preserving peripheral insertions. Thermal energy was applied discontinuously preserving parallel areas of TFCC unheated. The entire procedure was performed under continuous irrigation and the maximal temperature limit of the probe was set at 75° to prevent heat injury of joint tissues. After application of

thermal energy was finished, the trampoline effect and hook test were re-evaluated to check the increased mechanical resistance of the TFCC compared to the previous assessment.

### Postoperative Care

All patients were splinted with a volar forearm cast for partial wrist immobilization to reduce postoperative inflammation and pain. Three weeks later, the cast was removed and every patient underwent an intensive rehabilitation protocol based on gaining motion and strength for 4 to 6 weeks.

### Clinical and occupational assessment

Pain relief was classified according to three levels, a method that has been used in other studies concerning TFCC tears (20,21) :

- (i) Complete pain relief with all activities.
- (ii) Incomplete pain relief : pain with heavy work activities without interfering with daily activities. The patient was able to return to his occupation.
- (iii) Persistence pain : pain during daily activities. The patient did not return to work.

Postoperative range of motion was measured with a goniometer, and the gain or loss was reported as a percentage compared with the healthy contralateral wrist. Complications, reoperation rates, return to work and workers' compensation claims were also assessed. Days off work were calculated from the surgery, as the initial day, and reported in weeks. The presence of DRUJ instability was also assessed postoperatively.

### Data Analysis

Data collection was performed by a third evaluator not involved in the treatment. Range of motion, time to return to work, pain relief and days out of work were considered outcome variables for the statistical analysis. Age, sex, hand dominance and delay to surgery were contemplated as potential confounding factors. The Palmer's type of TFCC lesion was also analyzed. Data followed a non parametric distribution and were analyzed by Kruskal-Wallis, Wilcoxon and Pearson "R" tests using SPSS (v.19.0) statistical analysis program.

## RESULTS

The average follow-up period was 39 months (range : 15-72 months) and the patients' average

age was 36 years (range : 19-64). Prior to surgery, all patients referred pain with all activities. After surgery, 130 of the 162 patients (80.3%) had complete pain relief, 24 patients (14.8%) referred incomplete pain relief and 8 patients had pain persistence (4.9%). The average range of motion compared with the contralateral healthy wrist is shown on Figure 2.

We recorded 10 complications (6.2%) in 10 different patients. The most frequent complication was mild portal problems, such as burns or painful scars, in 6 (3.6%) patients.

The reoperation rate was 6.2% (10 of 162 patients). The indications for surgery were in one case to repair a tendon rupture, in another to debride a burn scar, and in 8 cases because of pain persistence. In these 8 cases, an ulnar shortening osteotomy (4), a further arthroscopic debridement (2) and an open TFCC suture (2) were performed.

Concerning to the faculty of the patient to return to his work, 87.7% of the patients returned to their previous occupational and/or sports activities without physical restrictions and 20 patients (12.3%) introduced a workers' compensation claim. Of these, 6 (3.6%) did not return to the same job and 14 (8.6%) returned to their previous job with an activity restriction of less than 33%. The average time to return to work was 21.2 weeks (range : 3-148).

No statistical correlations were found between sex, hand dominance, age and clinical outcome. There were a significant correlation between the delay to surgery and the final range of motion and time off work ( $p < 0.001$ ). Results were worse when the delay before surgery was longer. There was a significant correlation between the type of TFCC lesion and the clinical outcome ( $p < 0.001$ ). Patients with degenerative and traumatic type 1C tears had longer time off work (Table I) ; there was a minor difference in average range of motion ( $< 10^\circ$ ), which may not be considered clinically relevant.

## DISCUSSION

The management of TFCC tears has developed over the years, from the initial open procedures based on total or partial disk resection (8,12), going

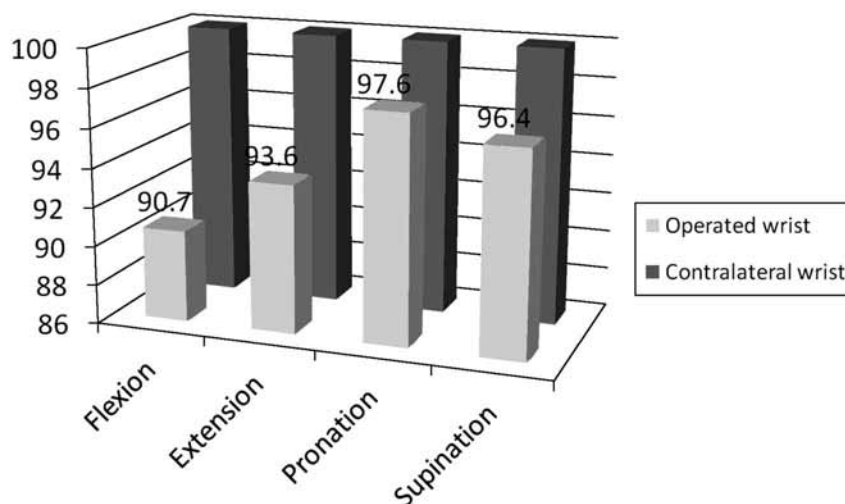


Fig. 2. — Average range of motion compared with the contralateral wrist

through various open suture techniques, and to the latest arthroscopic treatments. The current management of TFCC traumatic lesions advocates surgical repair mainly for type 1B tears. Indeed, several studies (1-3,18,20,21,23) have shown good clinical outcomes using various suture techniques. Suture or reinsertion techniques for type 1C and 1D tears have been described with excellent results (16). Nonetheless, these techniques are not free of technical problems. This has prompted the development of new devices to improve surgery and decrease complications. Other difficulties that have been reported are knot safety that is surgeon-dependent (13), dorsal sensory ulnar nerve entrapment by a suture knot (11) and foreign body tissue reaction.

From the late 90s several experimental studies have been published reporting changes in the histological properties of the collagen-rich tissues, such as the joint capsule, ligaments and meniscus, after using electrothermal energy. Its arthroscopic application was made in the knee (10) and shoulder before the wrist. Shrinkage and stabilization of the loose scapholunate and lunotriquetal ligaments by electrothermal energy has shown good results (6,7). DeWal *et al* concluded that the use of thermal energy in arthroscopic surgery of the wrist could have a useful role in the management of ligaments and TFCC lesions (4).

Based on information provided by these studies, we used thermal energy to achieve TFCC stabilization to prevent loose flaps of the TFCC causing symptoms, as has been done for meniscus degenerative tears. Many cases showed an intraoperative decrease of the trampoline effect maneuver and hook test after application of thermal energy. Shigemitsu *et al* (17) suggested the existence of a zone called internal portion and located deep in the pre-styloid recess as the main source of ulnar side wrist pain. We believe the application of thermal energy in this zone may help achieving pain relief.

In conclusion, the use of electrothermal energy for both stabilizing and denervating the TFCC lesions could be an option in the management of TFCC tears, with the exception of those cases where the presence of DRUJ instability is suspected at physical examination. In such cases a repair technique is necessary ; we use a foveal reinsertion technique rather than simple suture to the capsule. The treatment with electrothermal energy could reduce the surgical time and decrease technical difficulties related to the arthroscopic suture and knot tying. However, special care should be taken with thermal energy devices to avoid burns at portal sites at the wrist.

This study has a large number of cases (162), but its conclusions have the limitations of a retrospective

Table I. — Differences in number of days off work between TFCC lesion types.

Palmer type	Days off work (weeks)
1A	20.2±19.4
1B	20.6±20.2
1C	24.3±28.1
1D	18.1±11.2
2A	32.8±45.2
2C	22.2±20.8

review. Outcome measures such as the range of motion were straightforward, but the patients' records did not provide any validated functional scores such as DASH or SF-36. The pain outcome was reported in the records with sufficient precision to allow for comparison with other studies (20,21). The patients' records also provided reliable information on the ability of the patient to return to work and the number of days out of work. These are objective data that adequately reflect the clinical results.

Future prospective studies comparing this technique with the suture techniques would be necessary.

## REFERENCES

1. **Badia A, Khanchandani P.** Suture welding for arthroscopic repair of peripheral TFCC tears. *Tech Hand Upp Extrem Surg* 2007 ; 11 : 45-50.
2. **Böhringer G, Schädel-Höpfner M, Petermann J, Gotzen L.** A method for all-inside arthroscopic repair of Palmer 1B TFCC tears. *Arthroscopy* 2002 ; 18 : 211-213.
3. **De Araujo W, Pochling GG, Kuzma GR.** New Tuohy needle technique for TFCC repair : Preliminary studies. *Arthroscopy* 1996 ; 12 : 699-703.
4. **DeWal H, Ahn A, Raskin KB.** Thermal energy in arthroscopic surgery of the wrist. *Clin Sports Med* 2002 ; 21 : 727-735.
5. **Fitzgerald B, Watson B, Lapoint J.** The use of thermal capsulorrhaphy in the treatment of multidirectional instability. *J Shoulder Elbow Surg* 2002 ; 11 : 108-113.
6. **Geissler WB, Freeland AE, Savoic FH, Melntyre LW, Whippel TL.** Intra-articular soft-tissue lesions associated with an intra-articular fracture of the distal end of the radius. *J Bone Joint Surg* 1996 ; 78-A : 357-365.
7. **Hayasi K, Markel M.** Thermal modification of joint capsule and ligamentous tissues : the use of thermal energy in sports medicine. *Op Tech Sports Med* 1998 ; 6 : 120-125.
8. **Imbriglia JE, Bolan DS.** Tears of the articular disc of the TFCC : the results of excision of the articular disc. *J Hand Surg* 1983 ; 8 : 620-630.
9. **Infanger M, Grimm D.** Meniscus and discus lesions of TFCC : treatment by laser-assisted wrist arthroscopy. *J Plastic Reconstr Aesthetic Surg* 2009 ; 62 : 466-471.
10. **Khan A, Sherman O, Delay B.** Thermal treatment of anterior cruciate ligament injury and laxity with its imaging characteristics. *Clin Sports Med* 2002 ; 21 : 701-711.
11. **McAdams T, Hentz V.** Injury to the dorsal sensory branch of the ulnar nerve in the arthroscopic repair of ulnar sided TFC tears using an inside-out technique : a cadaver study. *J Hand Surg* 2002 ; 27 : 840-844.
12. **Menon J, Wood VE, Schoene HR.** Isolated tears of the TFC of the wrist : results of partial excision. *J Hand Surg* 1984 ; 9-A : 527-530.
13. **Mishra DK, Cannon WD Jr, Lucas DJ.** Elongation of arthroscopically tied knots. *Am J Sports Med* 1997 ; 25 : 113-115.
14. **Palmer AK.** TFCC lesions : a classification. *J Hand Surg* 1989 ; 14-A : 594-606.
15. **Rusch DS, Poehling G.** Arthroscopic management of partial scapholunate and lunotriquetal injuries of the wrist. *J Hand Surg* 1996 ; 21-A : 412-417.
16. **Sagerman SD, Short W.** Arthroscopic repair of radial-sided TFCC tears. *Arthroscopy* 1996 ; 12 : 339-342.
17. **Shigemitsu T, Tobe M, Mizutani K et al.** Innervation of the TFCC in the human wrist : Quantitative immunohistochemical study. *Anat Science Int* 2007 ; 82 : 127-132.
18. **Shih JT, Lee HM, Tan CM.** Early isolated TFCC tears : Management by arthroscopic repair. *Injury* 2002 ; 53 : 922-927.
19. **Shih JT, Lee HM.** Monopolar radiofrequency electrothermal shrinkage of the scapholunate ligament. *Arthroscopy* 2006 ; 22 : 553-557.
20. **Trumble TE, Gilbert MA, Vedder N.** Arthroscopic repair of the TFCC. *Arthroscopy* 1996 ; 12 : 588-597.
21. **Trumble TE, Gilbert M, Vedder N.** Isolated tears of the TFCC : Management by early arthroscopic repair. *J Hand Surg* 1997 ; 22-A : 57-65.
22. **Unglaub F, Fellenberg J, German G.** Detection of apoptotic cartilage cells in symptomatic central tears of the TFC. *J Hand Surg* 2007 ; 32-A : 618-622.
23. **Zachee B, De Smet L, Fabry G.** Arthroscopic suturing of TFCC lesions. *Arthroscopy* 1993 ; 9 : 242-243.