



A modified custom-made triflanged acetabular reconstruction ring (MCTARR) for revision hip arthroplasty with severe acetabular defects

Sascha COLEN, Ramzi HARAKE, Julien DE HAAN, Michiel MULIER

From the University Hospitals Leuven, Pellenberg, Belgium

The treatment of extensive acetabular bone loss and pelvic discontinuity in revision total hip arthroplasty remains challenging. We report our preliminary experience with the modified custom-made triflanged acetabular reconstruction ring (MCTARR) in the management of such situations. The MCTARR is a custom-made metal reinforcement ring with a trabecular surface to encourage bone ingrowth and a bulky trabecular metal augmentation to fill the acetabular defects, designed to achieve initial and long-term stability. A custom-made drilling jig is used to achieve optimal screw positioning.

The clinical and radiological short-term follow-up (10-58 months) of our first six cases treated with this new technique show acceptable to good results. None of the reconstructions failed or had to be revised. Clinical results were satisfactory. Radiographs showed good screw positioning.

The custom-made acetabular drilling jig and the reconstruction of the acetabulum with a titanium porous structure are of added value in the treatment of severe acetabular bone loss and pelvic discontinuity with custom-made triflanged components.

Keywords : acetabular revision arthroplasty ; triflanged component ; acetabular jig.

INTRODUCTION

The well-known aging of the population combined with the tendency to use total hip replacement in younger patients may explain the increasing incidence of revision arthroplasties. Extensive bone

loss makes revision surgery particularly challenging. The Norwegian Arthroplasty Register showed a failure rate of 25.6% for revision hip arthroplasty versus 11.4% for primary hip arthroplasty, with a follow-up of 10 years. Fifty-eight percent of these revisions were acetabular component revisions (10). Revision surgery should aim at stability of the joint implants, and restoration of normal hip biomechanics (6,7). The selection of the fixation mode and cup type depends on the remaining bone stock.

D'Antonio *et al* (2) proposed reconstructions using antiprotrusio cages, bilobed and oversized cups and augments for the treatment of type 3 and 4 acetabular defects according to the American Academy of Orthopaedic Surgeons (AAOS) classification. Reconstructions with structural bone transplants and compacted morselised allografts have also been proposed for revision surgery of total hip arthroplasties (9,12,14,17).

-
- Sascha Colen, MD, Orthopaedic Surgeon.
 - Ramzi Harake, MD, Orthopaedic Surgeon.
 - Julien De Haan, MD, Resident.
 - Michiel Mulier, MD, PhD, Senior Orthopaedic surgeon.
Department of Orthopaedic Surgery, University Hospitals Leuven, Pellenberg, Belgium.

Correspondence : Michiel Mulier, University Hospitals Leuven, site Pellenberg, Department of Orthopaedic Surgery, Weligerveld 1, 3212 Pellenberg, Belgium.

E-mail : michiel.mulier@uzleuven.be

© 2012, Acta Orthopædica Belgica.

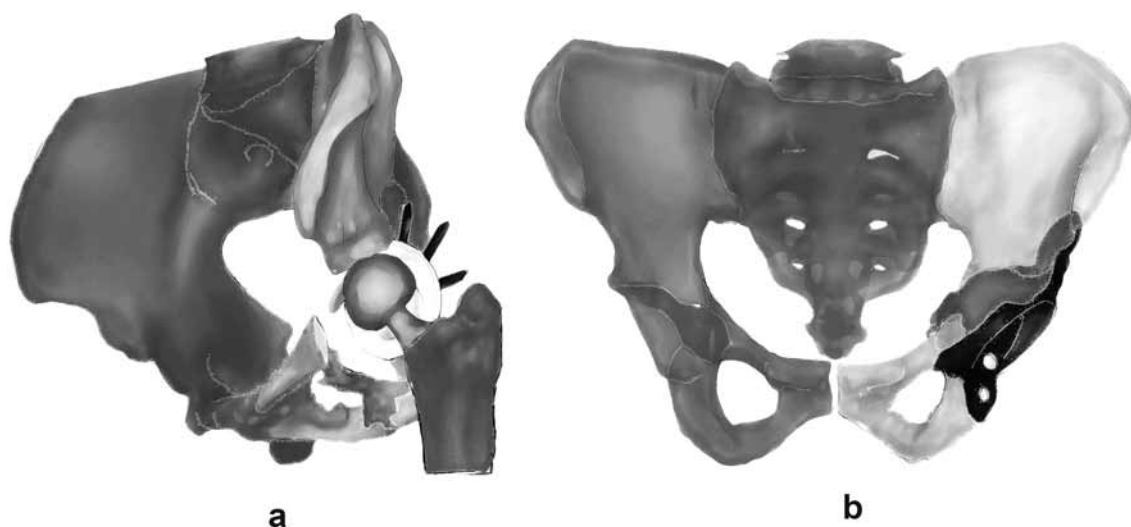


Fig. 1. — (a) CT 3D preoperative reconstruction of the pelvis with visualization of the bony acetabular defect and the implant components. (b) 3D planned reconstruction of the pelvis with visualization of the custom-made acetabular implant and bone augment.

The use of triflanged titanium cementless custom-made acetabular implants in the management of complex acetabular bone deficiencies has already been reported by Joshi *et al* (8) in 2002 with satisfactory functional and short-term results. In 2007 DeBoer *et al* (4) reported good clinical results in 18 patients at a mean follow-up of 10 years after implantation of a custom-made porous-coated triflanged acetabular component for the treatment of pelvic discontinuity.

A triflanged acetabular implant is an acetabular component with iliac, ischial and pubic flanges. These flanges link the implant to the stable host bone with screws for initial stability, while maintaining or returning the hip center to its anatomic location (15). Even with imaging, preoperative assessment of acetabular bone loss, planning and screw positioning remain difficult.

The modified custom-made triflanged acetabular reconstruction ring (MCTARR) used in this study is developed using the data of 3D CT-based image processing and virtual anatomical reconstruction methodology (Fig. 1) (Mobelife & Materialise NV, Leuven, Belgium). The surface of the MCTARR in contact with the pelvic bone is covered with a trabecular titanium layer that has bone mimicking characteristics. The titanium porous structure is also

used to fill and reconstruct the acetabular defect anatomically. The position, trajectory and length of the screws are pre-determined, based on the CT-scan data. A custom-made epoxy jig based on the CT-scan data, is applied on the MCTARR to guide screw position, orientation and depth.

The purpose of this study is to describe the short-term to mid-term results of acetabular revisions using the MCTARR with the corresponding acetabular drilling jig in patients with type 3 or 4 acetabular defects according to the AAOS classification (2).

MATERIALS AND METHODS

Six patients with severe acetabular bone defects in combination with failure of a total hip arthroplasty received complete information on the necessity to use a custom-made implant. Contraindications to revision surgery were medical comorbidities prohibiting surgery and active infection.

Anteroposterior (AP) and true lateral radiographs of the hip and AP radiograph of the pelvis were made for all six patients preoperatively and postoperatively. Preoperative bone deficiency was determined on the AP radiographs of the pelvis and hip and true lateral view of the hip, according to the AAOS classification (2). Only patients with severe acetabular bone loss (type 3 and 4 according to the AAOS classification) were candidates

for this type of reconstruction. A type 3 defect combines a segmental and a cavitary defect ; a Type 4 defect includes a pelvic discontinuity with complete separation between the superior and the inferior acetabulum. Preoperatively, all six patients had a CT-scan with minimal slice thickness and interval (0.2 ± 0.5 mm) to evaluate the bone loss and the intra-pelvic migration of the cup. Both the implants and patient-specific instruments are produced using Additive Manufacturing® (AM) (Mobile & Materialise NV, Leuven, Belgium) technology. A patient-specific 3D digital design of the implant was made based on CT imaging data using dedicated software tools. The implant was then printed using the AM technology. Selective Laser Melting (SLM), which uses a focused laser beam to melt titanium powder layer-by-layer, results in a fully dense end product with properties comparable with cast or wrought Ti6Al4V. The patient-specific instruments manufactured using medical grade epoxy monomer were produced using the same AM technology.

All six revisions were performed by one senior surgeon (MM). The anterolateral approach with the patient in supine position was used. If possible the incision was made on the scar of the previous approach ; it was extended if necessary. After detaching less than the anterior half of the gluteus medius and minimus muscle, the capsule and fibrous tissue around the hip joint were removed and the hip joint was dislocated. By removing the remaining fibrous tissue a good exposure of the acetabulum was obtained. The acetabular component that needed revision was removed ; all soft tissue in the acetabulum and at the regions of the implant fixation at the ilium, ischium and pubis were excised. After cleaning with pulsatile lavage, the custom-made acetabular implant was tested. The implant is designed to fit snugly within the prepared acetabulum. Initial implant fixation is secured with screws inserted through holes in the three extended arms (flanges) of the implant, and also through holes in the cup portion, using an epoxy custom-made drilling jig (Fig. 2). As mentioned before, the screw positioning and length of the screws were pre-operatively determined. The screws were directed, using the patient-specific drilling jig, towards the iliac crest, the sacrum and the superior pubic ramus.

The porous surface of the implant encourages bone ingrowth, thus promoting long-term implant stability by osseointegration. The larger space filling scaffold is constructed as an augment with a porous macrostructure. It is in continuity with the metal plate, forming an one-piece implant. The areas of the flanges contacting the host bone are also covered with porous metal as a structural

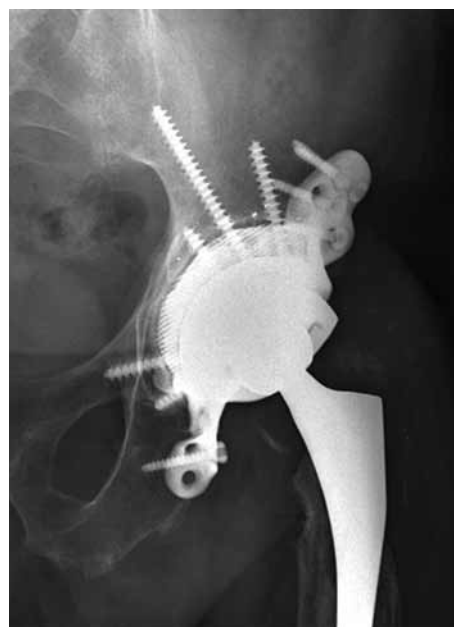

Fig. 2. — Two-year postoperative AP pelvic radiograph showing the well-fitted acetabular component and the restored centre of rotation of the hip.

part of the implant. The cup orientation was determined preoperatively with respect to inclination, medialization and anteversion to replicate the normal anatomy and decrease the risk of postoperative dislocation, using the data of 3D CT-based image processing and virtual anatomical reconstruction methodology (Fig. 1) (Mobile & Materialise NV, Leuven, Belgium). A dual-mobility cup (Biomet Avantage 48 mm [Biomet Inc., Warsaw, In, USA]) was cemented in the MCTARR.

The hip was repositioned, the gluteus medius muscle was reattached to the greater trochanter and the wound was closed.

On the first postoperative day the patients underwent passive range of motion exercises. When the wound was dry, gait training with the aid of a physical therapist was started. Partial weight-bearing with the use of a walker or two crutches was recommended until three months after surgery.

Follow-up visits were scheduled at six weeks, three months, six months and one year postoperatively, and annually thereafter. At each visit all patients had an AP pelvis and hip radiograph and a true lateral view radiograph of the hip. The clinical results were also obtained using the Visual Analogue Scale Score (VAS) (3), modified Harris Hip Score (mHHS) (1,13,16) and the Hip disability and Osteoarthritis Outcome Score (HOOS) (11).

Table I. — Patient details

Patient	Age at operation (years)	AAOS	Previous revisions	Follow-up (months)	VAS (0-100)	Modified HHS (0-91)	HOOS (%)
1	63	IV	2	26	21	58	71.7
2	70	IV	2	31	7	71	88.8
3	67	III	5	10	4	62	86.3
4	69	III	7	19	30	68	70.0
5	68	III	2	27	76	42	53.8
6	78	IV	5	58	32	66	74.7

Screw positioning was checked on the first postoperative radiograph. The second and the most recent postoperative radiographs were compared for signs of loosening, component migration, hardware failure, presence of radiolucent lines and bridging callus across the site of pelvic discontinuity.

RESULTS

Between July 2007 and June 2011, six patients (six hips) with a failed total hip arthroplasty underwent revision THA with a MCTARR. All six patients had type 3 or 4 acetabular defects according to the AAOS classification (3 patients with type 3 and 3 patients with type 4) (Table I). Three men and three women with a mean age of 69.2 years (63-78 years) were included. They had undergone two to seven previous revisions. The indication for revision with MCTARR was loosening of the cup with severe intra-pelvic migration in 4 patients, previous infection with severe bone loss in one patient, and migration and protrusion of the cup in one patient. Because of their age and co-morbidity, minimal weight-bearing (less than 50%) was allowed on the operated leg with the aid of a walker or two crutches during the first three months.

These six patients were followed for a minimum of ten months (10 to 58 months).

To date, no components had to be removed and no hip had to be revised for any reason, no dislocations of the operated hip occurred and no evidence of infection was registered. The VAS, HHS and HOOS scores showed fair results (Table I), but more importantly, all patients were very satisfied with the clinical result of the reconstruction.

Due to the bulk of the titanium acetabular component, the possibility for radiographic analysis was limited (Fig. 2). However, until now no operated hip showed signs of migration, loosening or hardware failure. Screw positioning was correct in all patients: the screws in the ilium, pubis and ischium all had adequate direction and length. None of the screws used in the cup portion protruded into the pelvis.

A post-operative CT-scan of the pelvis was available in only one of the patients. This CT-scan allowed to show the matching of the pre-operatively planned orientation onto the actual postoperative image using the Mimics® image processing software (Mobelife & Materialise NV, Leuven, Belgium). Analysis showed a close match of the intended positioning and the obtained implant positioning with less than 2° and 3 mm difference in respectively the angulation of the device and the location of the centre of rotation.

DISCUSSION

In this series of six patients with severe acetabular bone loss and with pelvic discontinuity in three of them, we obtained fair clinical and good radiological results using a MCTARR with a follow-up of 10 to 58 months. Because of the high manufacturing cost of the custom-made implant, only patients with severe type 3 and 4 acetabular defects according to the AAOS classification were included. By means of a pre-operatively performed CT-scan and with the use of special software, we were able to preoperatively assess the bone quality, and to

pre-determine the screw positioning and length. Per-operatively we used a custom-made drill jig to perform a solid and anatomical fixation of the acetabular implant. Using this patient-specific drilling jig makes it possible to safely insert a screw towards the iliac crest while avoiding the ischiatic notch. The cup screws into the superior pubic ramus can also be safely placed while avoiding injuries to the external iliac blood vessels, femoral nerve and obturator nerve and vessels (5).

The whole surface at the back of the implant as well as the contact area of the flanges have a porous microstructure to promote bone ingrowth and thus provide the best chances for long-term stability. We believe a bulky titanium porous acetabular reconstruction as used in the MCTARR provides an improved stability of the implant and therefore an opportunity for ingrowth of bone which will ensure the long-term stability of the implant.

The use of this novel automated CT-based methodology together with engineering software makes it possible to create a patient-specific implant. Evaluation of bone quality and thickness are incorporated in the preoperative planning.

Last but not least, it takes about one month from performing a CT-scan to delivery of the custom-made implant together with the acetabular drilling jig. During this time period several meetings with the engineering team are included to discuss the bone quality analysis and the jig planning.

Although postoperative radiographic assessment is hindered by the bulk of the implant, no signs of loosening, migration or hardware breakage were observed.

We are now planning a prospective follow-up for patients that can be treated with this new technique.

REFERENCES

1. **Byrd JW, Jones KS.** Prospective analysis of hip arthroscopy with 2-year follow-up. *Arthroscopy* 2000 ; 16 : 578-587.
2. **D'Antonio JA, Capello WN, Borden LS et al.** Classification and management of acetabular abnormalities in total hip arthroplasty. *Clin Orthop Relat Res* 1989 ; 243 : 126-137.
3. **de Nies F, Fidler MW.** Visual analog scale for the assessment of total hip arthroplasty. *J Arthroplasty* 1997 ; 12 : 416-419.
4. **DeBoer DK, Christie MJ, Brinson MF, Morrison JC.** Revision total hip arthroplasty for pelvic discontinuity. *J Bone Joint Surg* 2007 ; 89-A : 835-840.
5. **Galat DD, Petrucci JA, Wasielewski RC.** Radiographic evaluation of screw position in revision total hip arthroplasty. *Clin Orthop Relat Res* 2004 ; 419 : 124-129.
6. **Issack PS, Nousiainen M, Beksac B et al.** Acetabular component revision in total hip arthroplasty. Part I : cementless shells. *Am J Orthop* 2009 ; 38 : 509-514.
7. **Issack PS, Nousiainen M, Beksac B et al.** Acetabular component revision in total hip arthroplasty. Part II : management of major bone loss and pelvic discontinuity. *Am J Orthop* 2009 ; 38 : 550-556.
8. **Joshi AB, Lee J, Christensen C.** Results for a custom acetabular component for acetabular deficiency. *J Arthroplasty* 2002 ; 17 : 643-648.
9. **Lee JM, Nam HT.** Acetabular revision total hip arthroplasty using an impacted morselized allograft and a cementless cup : minimum 10-year follow-up. *J Arthroplasty* 2011 ; 26 : 1057-1060.
10. **Lie SA, Havelin LI, Furnes ON, Engesaeter LB, Vollset SE.** Failure rates for 4762 revision total hip arthroplasties in the Norwegian Arthroplasty Register. *J Bone Joint Surg* 2004 ; 86-B : 504-509.
11. **Nilsdotter AK, Lohmander LS, Klassbo M, Roos EM.** Hip disability and osteoarthritis outcome score (HOOS) – validity and responsiveness in total hip replacement. *BMC Musculoskelet Disord* 2003 ; 4 : 10.
12. **Pieringer H, Auersperg V, Bohler N.** Reconstruction of severe acetabular bone-deficiency : the Burch-Schneider antiprotrusio cage in primary and revision total hip arthroplasty. *J Arthroplasty* 2006 ; 21 : 489-496.
13. **Potter BK, Freedman BA, Andersen RC et al.** Correlation of Short Form-36 and disability status with outcomes of arthroscopic acetabular labral debridement. *Am J Sports Med* 2005 ; 33 : 864-870.
14. **Schelfaut S, Cool S, Mulier M.** The use of structural peri-acetabular allografts in acetabular revision surgery : 2.5-5 years follow-up. *Arch Orthop Trauma Surg* 2009 ; 129 : 455-461.
15. **Taunton MJ, Fehring TK, Edwards P et al.** Pelvic discontinuity treated with custom triflange component : a reliable option. *Clin Orthop Relat Res* 2012 ; 470 : 428-434.
16. **van den Bekerom MP, Hilverdink EF, Siersevelt IN et al.** A comparison of hemiarthroplasty with total hip replacement for displaced intracapsular fracture of the femoral neck : a randomised controlled multicentre trial in patients aged 70 years and over. *J Bone Joint Surg* 2010 ; 92-B : 1422-1428.
17. **van Egmond N, De Kam DC, Gardeniers JW, Schreurs BW.** Revisions of extensive acetabular defects with impaction grafting and a cement cup. *Clin Orthop Relat Res* 2011 ; 469 : 562-573.