



Comparison of locked plating and intramedullary nailing for periprosthetic supracondylar femur fractures after knee arthroplasty

Önder İ. KILIÇOĞLU, Turgut AKGÜL, Yavuz SAĞLAM, Önder YAZICIOĞLU

Department of Orthopaedic Surgery, Istanbul Medicine Faculty, Istanbul, Turkey

This study aimed to compare the efficacy of two treatment modalities for periprosthetic supracondylar fractures. The results of intramedullary nailing in 7 patients and locked plating in 9 patients were reviewed retrospectively. Mean follow-up was 4.3 years (range : 1 to 13 years). One patient died on the first postoperative day. Union of the fracture was achieved in the other 15 patients, after a mean time of 3.86 months : 3.9 months (range : 3 to 6 months) in the locked plate group and 3.86 months (range : 3 to 5 months) in the intramedullary nail group ($p = 0.96$). Mean Knee Society Score was 78 points (range : 68 to 84 points) and mean total knee range of motion was 82° (range 70° to 90°) with no significant differences between groups. Sagittal and coronal plane measurements were similar both in the early postoperative period and at the last follow-up. The two treatment modalities had similar results with a high success rate.

Keywords : knee arthroplasty ; periprosthetic femur fracture ; locked plate ; intramedullary nailing.

periprosthetic knee fracture. A periprosthetic patella fracture occurs on a resurfaced patella (7,16). Documented risk factors for periprosthetic fracture after total knee arthroplasty are osteoporosis, rheumatoid arthritis, neurological and medical disorders, female gender and revision arthroplasty (1, 5,6,12,22). Anterior femoral notching has also been proven to be an important risk factor, causing stress concentration in the supracondylar region in condylar type prostheses (6,12).

The goals of periprosthetic supracondylar fracture treatment are to obtain healing without deformity, to preserve range of motion in the knee and to provide a painless joint during daily activities (11). Treatment options include conservative and surgical modalities (11). Osteosynthesis methods such as retrograde intramedullary nailing, dynamic condylar plates, flexible nails and locked plates have previously been reported to decrease the non-union

INTRODUCTION

The incidence of periprosthetic knee fractures parallels the rapid increase in the number of total knee replacement procedures (2,7), reaching a reported level of 0.3-2%. By definition, a tibia or femur fracture within 15 cm to a knee arthroplasty, or within 5 cm to the stem of a knee implant is a

■ Önder İ. Kılıçoğlu, MD, Professor.

■ Turgut Akgül, MD, Orthopaedic Surgeon.

■ Yavuz Sağlam, MD, Resident.

■ Önder Yazıcıoğlu, MD, Professor.

Orthopaedics and Traumatology Department, Istanbul University Medicine Faculty, Istanbul, Turkey.

Correspondence : Turgut Akgül, Istanbul University, Istanbul Medicine Faculty, Orthopaedics and Traumatology Department, Millet caddesi, Çapa, Fatih, Istanbul.

E-mail : doktorturgut@yahoo.com

© 2013, Acta Orthopædica Belgica.

rates and to have positive effects on mortality and morbidity, allowing early knee mobilization (6).

The aim of this study was to compare the clinical and radiological results obtained with two treatment modalities, locked plating and intramedullary nailing in femoral supracondylar periprosthetic fractures.

PATIENTS AND METHODS

Sixteen patients (16 knees), who had been treated in our institution for periprosthetic supracondylar fractures of the femur were reviewed retrospectively. Thirteen patients were female and three were male. Mean patient age was 72.5 years (range: 63-84). Fractures were classified as type 2 in 13 patients, type 4 in two patients and type 3 in one patient according to the classification described by Neer *et al* (18). The mean period between total knee replacement and periprosthetic fracture was 51 months (range: 1-180).

Two of the patients had previously been treated in other institutions, while the other patients were primary cases. Nine patients (56%) were treated with locked plates (LISS, Synthes, Switzerland) and seven (44%) were treated with retrograde intramedullary nailing (TriGen Knee Nail, Smith & Nephew, USA). Minimally invasive surgical techniques were applied in all primary cases, while the two revision osteosynthesis patients received intramedullary nailing after removal of the implants. Autologous iliac bone grafting was used in one patient with nonunion.

Range of motion exercises were started after the drains were removed on the second postoperative day, when toe-touch gait was also allowed. Full weight-bearing was not allowed until union was observed on the radiographs taken every 6 weeks.

Study design and outcome parameters

Patient records were reviewed retrospectively for demographic data, details of operations and early follow-up results. Seven patients died during the follow-up period; therefore, records of their last follow-up examinations were used for the study. The remaining eight patients were invited for a last clinical and radiological examination.

The Knee Society Score was used for clinical assessment (8).

Radiological outcome parameters were time to union, evidence of reduction loss during healing period and

final alignment of fracture fragments. Union was defined as the presence of bridging callus formation in two or more cortices on the anterior-posterior and lateral radiographs. Any change of more than 5 degrees in the position of the fragments in any of the orthogonal planes was assessed as a loss in reduction (14). Nonunion was defined as a painful fracture which, after six months of follow-up, did not show evidence of healing on three consecutive radiographs taken at one-month intervals. A femoral shortening of more than 2 cm and a difference of more than 10 degrees in rotation were considered as malunion (14).

The alignment of the femoral component was evaluated using anatomic lateral distal femoral angle (aLDFA) (Fig. 1a) and anatomic posterior distal femoral angle (aPDFA) (Fig. 1b) measured on plain radiographs (19). Normal values for these parameters were accepted as 81° (range: 79° to 83°) and 83° (range: 77° to 88°) respectively.

Significance of differences between results of nail and plate groups were tested using Student's *t* test. Significance of differences between early postoperative and latest follow-up alignment values was tested using Wilcoxon-rank test. Significance level was set at $p < 0.05$.

RESULTS

One patient with femoral nailing died due to pulmonary embolus on the first postoperative day. Seven patients died after completion of healing from causes unrelated to the femoral fracture or operation. Mean follow-up period for fifteen patients was 4.3 years (range: 1 to 13).

Mean Knee Society Score of the eight patients who were clinically examined was 78 points (range: 68 to 84). Mean total knee range of motion of these patients was 82° (range: 70° to 90°).

Union was achieved in all patients, except in one patient who died on the first postoperative day. Mean time to radiological union was 3.86 months (range: 3 to 6) for the remaining 15 patients, 3.9 months (range: 3 to 6) in the locked plate group and 3.8 months (range: 3 to 5) in the intramedullary nail group ($p = 0.149$).

Average aLDFA value was 85° (range: 75° to 90°) and average aPDFA 81.2° (range: 74 to 87°) in early postoperative radiographs. In the locked plate group, the average aLDFA value was 84.3° (range: 75 to 90°) and the average aPDFA 81.1°

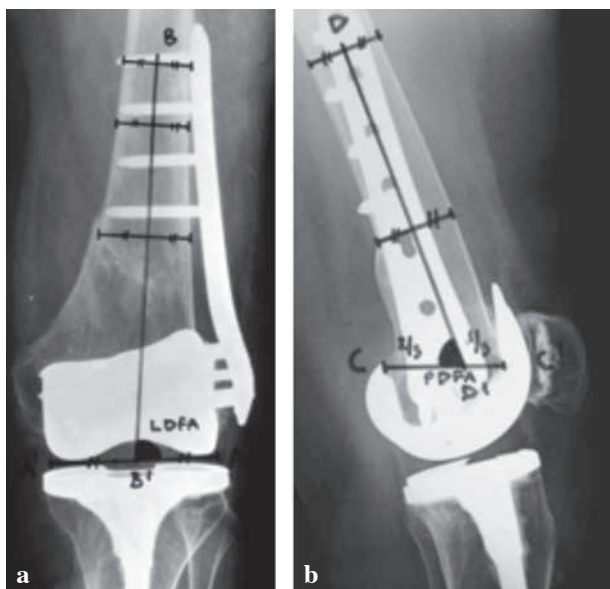


Fig. 1. — The alignment of the femoral component was evaluated using the anatomic lateral distal femoral angle (aLDFA) (Angle between A-A and B-B line) (a) and the anatomic posterior distal femoral angle (aPDFA) (Angle between C-C and D-D line) (b) measured on plain radiographs. Normal values for these parameters were accepted as 81° (range 79° to 83°) and 83° (range 77° to 88°) respectively.

(range : 74° to 87°). These values were 86° (range 81° to 90°) and 81° (range : 77° to 85°), respectively for the intramedullary nail group.

Average aLDFA value after union was 85.3° (range 74° to 92°) and average aPDFA 80.6° (range 72° to 87°). For the locked plate group, the average aLDFA value was 83.9° (range : 74° to 90°) and the average PDFFA value 80.4° (range : 72° to 87°). These values were 87° (range : 82° to 92°) and 80.8° (range : 75° to 84°) respectively, for the retrograde intramedullary nail group (Table I). Malunion or implant failure was not observed on follow-up radiographs and clinical examinations. The mean loss of reduction in aLDFA was 1.27° (range : 0° to 2°) and 1.18° (range : 0° to 3°) for aPDFA values.

No significant difference was found between groups in sagittal and coronal plane measurements, in the early postoperative period and at last follow-up. Differences between times to healing and Knee Society Scores in the two groups were not significant either. The average age of the patients was younger

in the IM nail group than in the locked plate group (Table I).

DISCUSSION

Union was achieved in all patients treated with IM nailing or locked plate fixation. No complication was experienced during or after the surgery. There was no significant difference between the two treatment modalities with respect to lower extremity alignment and functional scoring.

Union was achieved in all cases without a significant delay. While a high failure rate of 35-50% was reported in the early 90's (9,17), recent series utilizing minimal invasive surgical techniques report better outcomes with both plates and IM nails (3,10,15,20,21). In a study of 13 periprosthetic fractures managed by locked plating, Kregor *et al* reported successful union in 94% of cases. One patient required grafting because of delayed union (15). Ricci *et al* had a primary healing rate of 86% in 22 fractures managed with lateral locked plating according to minimal invasive technique (21). Gliatis *et al* reported that bone union could be obtained using retrograde intramedullary nailing in all cases of periprosthetic fractures even though revision arthroplasty using a stem was required in one case with a 35° valgus deformity (10). Bezwada reported successful results at 3-year follow-up of 18 patients treated with retrograde IM nailing, with however one infection and one malunion (3).

Osteoporosis, small size of distal fracture fragment and the prosthesis itself create technical problems for osteosynthesis supracondylar periprosthetic fractures (22). Gliatis and Bezwada *et al* reported difficulties in controlling the small distal fracture fragment using an intramedullary nail (3,10). Clinical and biomechanical studies showed that a stable osteosynthesis can be achieved with locked plates, irrespective of the size of the distal fragment and of osteoporosis (24,25).

KS scores were 75 points (range : 68 to 84) and no statistically significant difference was found between groups. Kolb *et al* had good functional scores (mean 74 points ; range : 62-84) in a study of 18 periprosthetic supracondylar femoral fractures managed with indirect reduction technique (13).

Table I. — Demographic distributions of patients

	Case #	Age	NEER class.	Early postop aLDFA*	Early Postop aPDFa**	Follow-up (years)	Time to union (months)	Final aLDFA*	Final aPDFa**	Control KSS
Locked Plate	1	84	Type 2	86	87	2	4	87	87	72
	2	76	Type 2	88	86	1	4	86	87	80
	3	80	Type 2	75	86	1	4	74	84	NA
	4	75	Type 4	90	74	3	6	90	72	80
	5	75	Type 4	85	85	-	-	-	-	NA
	6	67	Type 2	86	74	2	3	84	73	NA
	7	77	Type 2	84	78	2	3	82	76	NA
	8	77	Type 2	81	82	2	3	82	84	80
	9	79	Type 2	84	78	1	4	86	80	82
	Mean and range	76.7 (77+/-4,6)		84.3 (85+/-4.3)	81.1 (82+/-5.2)	1.75 (2+/-0.7)	3.9 (4+/-0.9)	83.9 (85+/-4.8)	80.4 (82+/-6)	78.8 (80+/-3.9)
Intramedullary Nail	10	65	Type 2	85	85	2	4	87	82	68
	11	78	Type 3	84	78	1	3	82	78	84
	12	71	Type 2	81	77	13	4	82	75	NA
	13	63	Type 2	90	80	5	3	92	81	76
	14	71	Type 2	85	84	1	4	86	84	NA
	15	68	Type 2	90	82	10	5	91	81	NA
	16	64	Type 2	88	84	7	4	89	85	NA
	Mean and range	68.6 (68+/-5,6)		86 (85+/-3.3)	81.4 (82+/-3.3)	5.57 (5+/-4.9)	3.86 (4+/-0.7)	87 (87+/-4)	80.9 (81+/-3.4)	72.7 (74+/-4.16)
Statistical comparison (P=)	0.005	-	0.37	0.89	0.039	0.96	0.19	0.85	0.080	

*aLDFA : Anatomic lateral distal femoral angle ; **aPDFa : Anatomic posterior distal femoral angle ; KSS : Knee society score ; class : classification.

The mortality rate within one year was 13% in our series. Bhattacharyya *et al* reported an average mortality rate of 11% after periprosthetic femoral fractures, significantly higher ($p < 0.0001$) than in a group of matched patients who had undergone primary joint replacement ; it was similar to the mortality rate after a hip fracture. Patients with a periprosthetic fracture had a higher mortality risk regardless of the surgical treatment method chosen : it was 33% after open reduction and internal fixation (4). Rorabeck *et al* reported mortality rates of up to 18% in the first year after surgery (23).

Both intramedullary nailing and locked plate fixation resulted in a high union rate and functional scores. The two treatment modalities provided comparable clinical results.

REFERENCES

1. Aaron RK, Scott R. Supracondylar fracture of the femur after total knee arthroplasty. *Clin Orthop Relat Res* 1987 ; 219 : 136-139.
2. Backstein D, Safir O, Gross A. Periprosthetic fractures of the knee. *J Arthroplasty* 2007 ; 222 : 45-49.
3. Bezwada HP, Neubauer P, Baker J, Israelite CL, Johanson NA. Periprosthetic supracondylar femur fractures following total knee arthroplasty. *J Arthroplasty* 2004 ; 19 : 453-458.
4. Bhattacharyya T, Chang D, Meigs JB, Estok DM 2nd, Malchau H. Mortality after periprosthetic fracture of the femur. *J Bone Joint Surg* 2007 ; 89-A : 2658-2662.
5. Chen F, Mont MA, Bachner RS. Management of ipsilateral supracondylar femur fractures following total knee arthroplasty. *J Arthroplasty* 1994 ; 9 : 521-526.
6. Dennis DA. Periprosthetic fractures following total knee arthroplasty. *Instr Course Lect* 2001 ; 50 : 379-389.

7. **DiGioia AM 3rd, Rubash HE.** Periprosthetic fractures of the femur after total knee arthroplasty. A literature review and treatment algorithm. *Clin Orthop Relat Res* 1991 ; 271 : 135-142.
8. **Dorr IJN, Scott RD LD, Scott WN.** Rationale of the Knee Society clinical rating system. *Clin Orthop Relat Res* 1989 ; 248 : 13-14.
9. **Figgie MP, Goldberg VM, Figgie HE, Sobel M.** The results of treatment of supracondylar fracture above total knee arthroplasty. *J Arthroplasty* 1990 ; 5 : 267-276.
10. **Gliatis J, Megas P, Panagiotopoulos E, Lambiris E.** Midterm results of treatment with a retrograde nail for supracondylar periprosthetic fractures of the femur following total knee arthroplasty. *J Orthop Trauma* 2005 ; 19 : 164-170.
11. **Herrera DA, Kregor PJ, Cole PA, Levy BA et al.** Treatment of acute distal femur fractures above a total knee arthroplasty. *Acta Orthop* 2008 ; 79 : 22-27.
12. **Huo MH, Sculco TP.** Complication in primary total knee arthroplasty. *Orthop Rev* 1990 ; 19 : 781-788.
13. **Kolb K, Koller H, Lorenz I et al.** Operative treatment of distal femoral fractures above total knee arthroplasty with the indirect reduction technique : a long-term follow-up study. *Injury* 2009 ; 40 : 433-439.
14. **Krbec M, Motycka J, Lunáček L, Dousa P.** Osteosynthesis for periprosthetic supracondylar fracture above a total knee arthroplasty using a locking compression plate. *Acta Chir Orthop Traumatol Cech* 2009 ; 76 : 473-478.
15. **Kregor PJ, Hughes JL, Cole PA.** Fixation of distal femoral fractures above total knee arthroplasty utilizing the Less Invasive Stabilization System (L.I.S.S.). *Injury* 2001 ; 32 : 64-75.
16. **Laffargue P, Soenen M, Pinoit Y, Migaud H.** [Periprosthetic fractures around total hip and knee arthroplasty. Mortality, morbidity and prognostic factors of periprosthetic femoral fractures following hip arthroplasty : multicentric prospective assessment of 115 cases.] (in French). *Rev Chir Orthop Réparatrice Appar Mot* 2006 ; 92 : 264-269.
17. **Moran MC, Brick GW, Sledge CB, Dysart SH, Chien EP.** Supracondylar femoral fracture following total knee arthroplasty. *Clin Orthop Relat Res* 1996 ; 324 : 196-209.
18. **Neer C, Grantham S, Shelton M.** Supracondylar fracture of the adult femur. A study of 110 cases. *J Bone Joint Surg* 1967 ; 49-A : 591-613.
19. **Paley D.** *Principle of Deformity Correction.* Springer, 2003, 2nd edition, p 1-17.
20. **Raab G E, Davis C M 3rd.** Early healing with locked condylar plating of periprosthetic fractures around the knee. *J Arthroplasty* 2005 ; 20 : 984-989.
21. **Ricci WM, Loftus T, Cox C, Borrelli J.** Locked plates combined with minimally invasive insertion technique for the treatment of periprosthetic supracondylar femur fractures above a total knee arthroplasty. *J Orthop Trauma* 2006 ; 20 : 190-196.
22. **Ritter MA, Keating EM, Faris PM, Meding JB.** Rush rod fixation of supracondylar fractures above total knee arthroplasties. *J Arthroplasty* 1995 ; 10 : 213-216.
23. **Rorabeck CH, Taylor JW.** Periprosthetic fractures of the femur complicating total knee arthroplasty. *Orthop Clin North Am* 1999 ; 30 : 265-277.
24. **Wick M, Muller EJ, Kutscha-Lissberg F, Hopf F, Muhr G.** [Periprosthetic supracondylar femoral fractures : LISS or retrograde intramedullary nailing ? Problems with the use of minimally invasive technique.] (in German). *Unfallchirurg* 2004 ; 107 : 181-188.
25. **Zlowodzki M, Williamson S, Cole PA, Zardiackas LD, Kregor PJ.** Biomechanical evaluation of the less invasive stabilization system, angled blade plate, and retrograde intramedullary nail for the internal fixation of distal femur fractures. *J Orthop Trauma* 2004 ; 18 : 494-502.